



**PATIENT**

Jasper Sacheli

**SPECIES**

Canine

**BREED**

Bull Terrier

**SEX**

Neutered male

**AGE**

13 years

**WEIGHT**

58 lbs

**INTERPRETED BY**

Eric Lindquist, DMV,  
 DABVP, Cert. IVUSS,  
 CEO of SonoPath.com

**IMAGING PERFORMED BY**

Eric Lindquist, DMV,  
 DABVP, Cert. IVUSS,  
 CEO of SonoPath.com

**HOSPITAL NAME**

Greenwood Lake AH

**REFERRING VET**

Dr. Price

**INVOICE**

71612

**DATE**

2/17/26

**PRESENTING CLINICAL SIGNS**

The patient has a chronic cough, collapsing episode, possible seizure. Elevated liver enzymes. Chem BUN 33, Creatinine 20  
 ALT 350, ALP 3147, GGT 111, Chol 401

**ULTRASONOGRAPHIC EXAMINATION OF THE HEART**

The echocardiogram in this patient demonstrated normal **left atrial** size based on 3 different LA measurement methods. Chamber volumes and echogenicity were normal. The cranial and caudal **mitral** valve leaflets presented vegetative thickening consistent with endocardiosis. Doppler indicated measurable insufficiency. The **left ventricle** presented thicknesses with linear contour and was not dilated nor restricted. The **myocardium** presented normal echogenicity without subjective evidence of significant fibrotic or ischemic disease. **Contractility** of the ventricular walls was adequate and in normal range for this patient evidenced by the fractional shortening measurement and subjective evaluation of the different regions of the myocardium. The **left ventricular outflow** tract demonstrated normal laminar flow and subjective structural integrity. The **right atrium** and auricle revealed normal size, structure and content. No evidence of masses was noted or chamber overload. **Tricuspid** valvular assessment demonstrated adequate linear morphology. The **right ventricle** was of normal size (1/3 diameter of LV), chordae structure, myocardial echogenicity and thickness. **Pulmonic** tract assessment revealed normal valve structure, laminar flow, and diameter (approx. 1:1 pa/ao ratio). No visible **pericardial** or free pleura fluid was noted. No echographically detectable evidence of infiltrative disease was visible. The cranial **mediastinum and pericardial regions** were free of masses in the visible window.

<b>CANINE CARDIAC PARAMETERS</b>	<b>MR VMAX (m/s)</b>	<b>TR VMAX (m/s)</b>	<b>LA/AO</b>	<b>LA/AO (Heart Base)</b>	<b>FS (%)</b>	<b>EF (%)</b>	<b>EPSS (cm)</b>
<b>NORMAL PARAMETER</b>	4.5-5.5	<2.7	1.3	<1.6	28-40	40-100	<0.6
<b>PATIENT</b>	5.2	2.8	1.0	1.2	47	81	NM
<b>CANINE CARDIAC PARAMETERS</b>	<b>HR (BPM)</b>	<b>AV VMAX (m/s)</b>	<b>PV MAX (m/s)</b>	<b>BODY WEIGHT</b>	<b>LA 2D short axis Base view (cm)</b>	<b>LVIDd Avg; 2D and m-mode short axis (cm)</b>	<b>LVIDs Avg; 2D and m-mode short axis (cm)</b>
<b>NORMAL PARAMETER</b>	50-100	0.7-1.7	0.7-1.6	BELOW	BELOW	BELOW	BELOW
<b>PATIENT</b>	128	1.54	0.91	58 lbs	2.8	2.06	



**PATIENT**

Jasper Sacheli

**SPECIES**

Canine

**BREED**

Bull Terrier

**SEX**

Neutered male

**AGE**

13 years

**WEIGHT**

58 lbs

**INTERPRETED BY**

Eric Lindquist, DMV,  
DABVP, Cert. IVUSS,  
CEO of SonoPath.com

**IMAGING PERFORMED BY**

Eric Lindquist, DMV,  
DABVP, Cert. IVUSS,  
CEO of SonoPath.com

**HOSPITAL NAME**

Greenwood Lake AH

**REFERRING VET**

Dr. Price

**INVOICE**

71612

**DATE**

2/17/26

**ULTRASONOGRAPHIC EXAMINATION OF THE ABDOMEN**

**Urinary System**

The **urinary bladder**, trigone, and pelvic urethra presented normal thicknesses and normal tone. The pelvic urethra was imaged 3.0 cm beyond the cystourethral junction and appeared normal. The ureters were not visible which is normal. Accumulation of calculi were noted and measured up to 3.4 cm and was non-obstructive. The largest calculi measured 1.0 cm. No evidence of inflammatory or neoplastic changes was noted. Ureteral papillae were normal.

The **kidneys** revealed largely normal size and structure, corticomedullary definition and ratio (cortex 1/3 of medulla) were essentially maintained with some age-related loss of curvilinear patterns regarding the capsule and C/M junction. The cortices presented largely uniform texture with some increased echogenicity expected for this age patient. Medullary structure differed distinctly from that of the cortex. Pyelectasia was noted in the kidneys and measured 0.55 cm in the right kidney and 0.7 cm in the left kidney. Mineralization was noted in the kidneys. The right kidney measured 7.04 cm. The left kidney measured 7.38 cm with cortical infarcts likely owing to movement of calculi.

The residual **prostate** measured 1.1 cm.

**Adrenal Glands**

Both **adrenal glands** were visualized and recognized as having normal shape, size, position and echogenicity for this breed. The phrenic vasculature, glandular echogenicity and detail were unremarkable. Capsule, cortex, and medullary definition were normal for this age patient. The left adrenal gland measured 3.29 x 0.68 cm. The right adrenal gland measured 2.71 x 0.82 cm.

**Spleen**

The **spleen** presented a smooth homogeneous parenchyma hyperechoic to liver and renal cortical parenchyma. The capsule was smooth without noticeable expansion or deviation from within the spleen or adjacent pathology. The splenic vasculature demonstrated normal volume without signs of congestion or thrombosis. No sonographic evidence of acute or chronic inflammatory, neoplastic, or infarctual changes was noted.

**Liver**

The **liver** was uniformly swollen with minor, excessive gallbladder debris and over distension with dependent and suspended bile without evidence of overt mucocele formation. However, excessive sludge was present. The liver presented coarse architecture with mildly increased portal markings and subtle, mixed echogenic changes. Occasional hypoechoic nodule was noted. This is consistent with vacuolar hepatopathy and some level of remodeling and history of inflammatory component. There was no overt suspicion of neoplasia.



**PATIENT**

Jasper Sacheli

**SPECIES**

Canine

**BREED**

Bull Terrier

**SEX**

Neutered male

**AGE**

13 years

**WEIGHT**

58 lbs

**INTERPRETED BY**

Eric Lindquist, DMV,  
DABVP, Cert. IVUSS,  
CEO of SonoPath.com

**IMAGING PERFORMED BY**

Eric Lindquist, DMV,  
DABVP, Cert. IVUSS,  
CEO of SonoPath.com

**HOSPITAL NAME**

Greenwood Lake AH

**REFERRING VET**

Dr. Price

**INVOICE**

71612

**DATE**

2/17/26

**Gastrointestinal**

There was some residual chyme and gas was noted in the **stomach**, yet not pathological. This is consistent with post prandial presentation. Transit of chyme into the small intestine was normal. Curvilinear patterns were maintained throughout the GI tract. No evidence of pathology. Small and large intestine demonstrated normal luminal chyme and stool consistency respectively. No obstructive or overt infiltrative disease was noted. No associated abnormal lymphatic activity was noted.

**Pancreas**

The base and limbs of the **pancreas** were observed to be largely isoechoic to surrounding omental fat. Pancreatic duct and capsular contour were acceptably normal and parenchyma respected normal curvilinear patterns. No overt evidence of active inflammatory or neoplastic disease was noted.

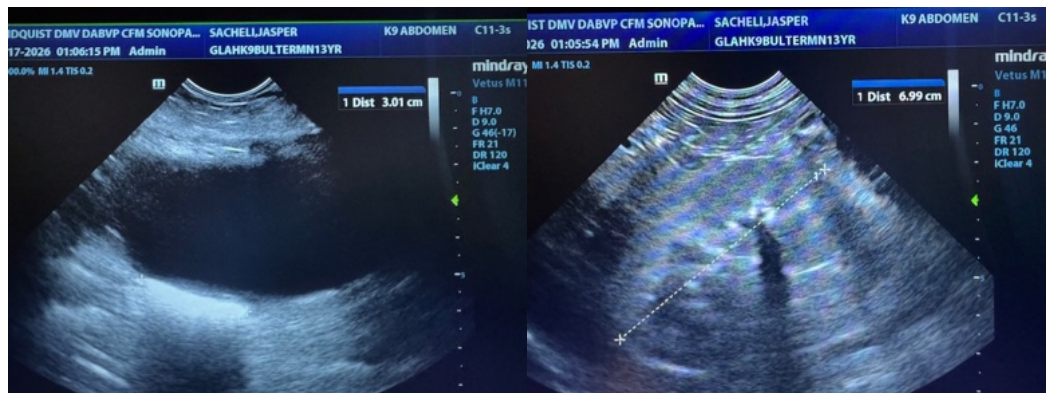
**ULTRASONOGRAPHIC FINDINGS**

- Stage B1 valvular disease.
- Moderate degenerative renal disease with nephrolithiasis, non-obstructive.
- Geriatric abdomen.

**INTERPRETATION OF THE FINDINGS & FURTHER RECOMMENDATIONS**

The heart is stable without clinical disease. No overt contraindication for anesthesia of brief to moderate duration. I suggest Torbutrol premed, Propofol induction, Isoflo maintenance or similar protocol if anesthesia is desired. Blood pressure recommended if not already performed and target white coat negative systolic pressure of < 160 mmHg. If higher than this ACE-inhibitor is suggested to reach this level. Recheck echocardiogram is recommended in 6 months, earlier if murmur grade increases or clinical signs initiate.

Eventual cystotomy, stone analysis and culture are indicated.





**PATIENT**

Jasper Sacheli

**SPECIES**

Canine

**BREED**

Bull Terrier

**SEX**

Neutered male

**AGE**

13 years

**WEIGHT**

58 lbs

**INTERPRETED BY**

Eric Lindquist, DMV,  
 DABVP, Cert. IVUSS,  
 CEO of SonoPath.com

**IMAGING PERFORMED BY**

Eric Lindquist, DMV,  
 DABVP, Cert. IVUSS,  
 CEO of SonoPath.com

**HOSPITAL NAME**

Greenwood Lake AH

**REFERRING VET**

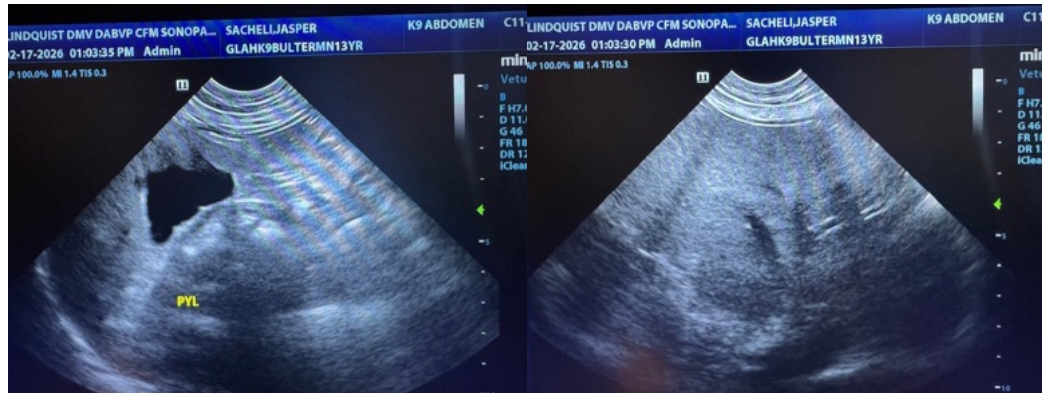
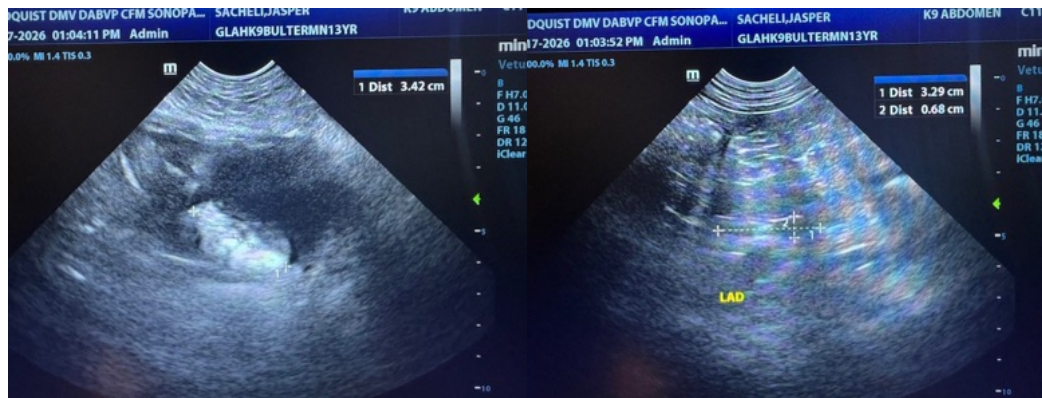
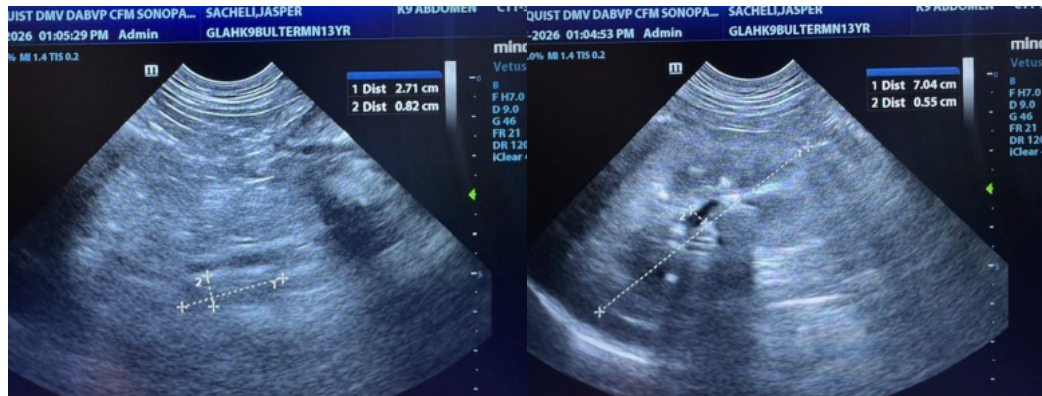
Dr. Price

**INVOICE**

71612

**DATE**

2/17/26





**PATIENT**

Jasper Sacheli

**SPECIES**

Canine

**BREED**

Bull Terrier

**SEX**

Neutered male

**AGE**

13 years

**WEIGHT**

58 lbs

**INTERPRETED BY**

Eric Lindquist, DMV,  
 DABVP, Cert. IVUSS,  
 CEO of SonoPath.com

**IMAGING PERFORMED BY**

Eric Lindquist, DMV,  
 DABVP, Cert. IVUSS,  
 CEO of SonoPath.com

**HOSPITAL NAME**

Greenwood Lake AH

**REFERRING VET**

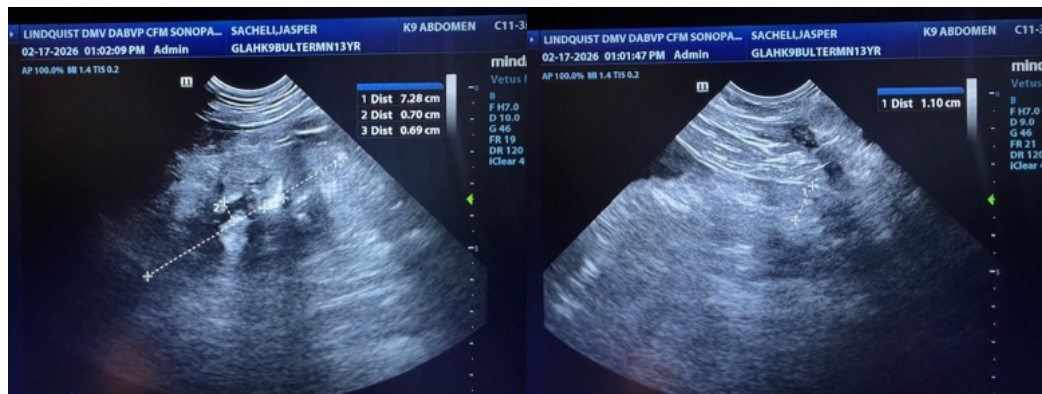
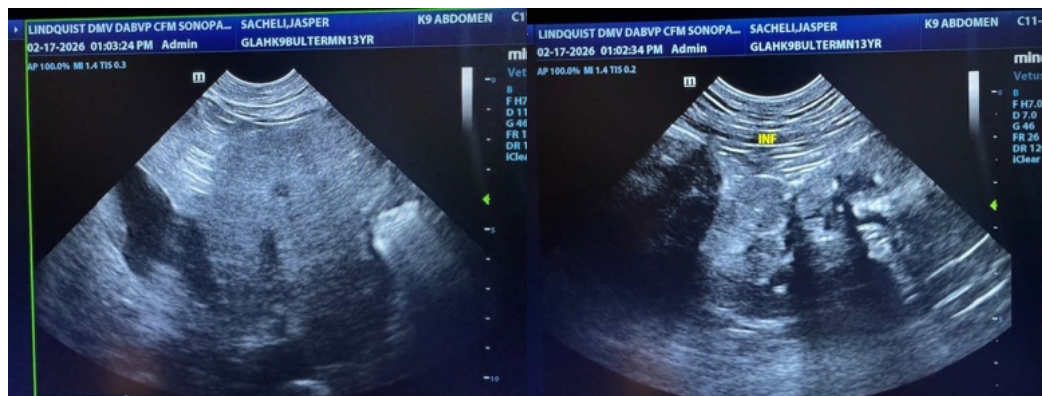
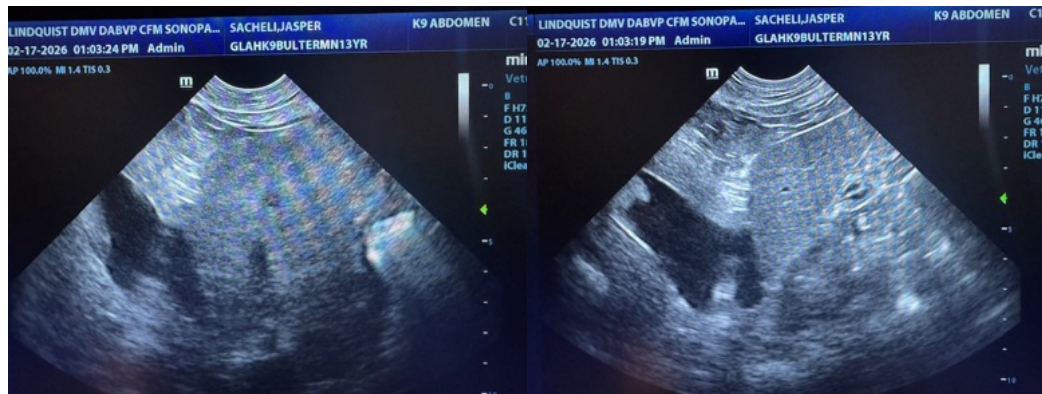
Dr. Price

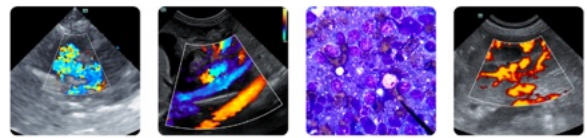
**INVOICE**

71612

**DATE**

2/17/26





**PATIENT**

Jasper Sacheli

**SPECIES**

Canine

**BREED**

Bull Terrier

**SEX**

Neutered male

**AGE**

13 years

**WEIGHT**

58 lbs

**INTERPRETED BY**

Eric Lindquist, DMV,  
 DABVP, Cert. IVUSS,  
 CEO of SonoPath.com

**IMAGING PERFORMED BY**

Eric Lindquist, DMV,  
 DABVP, Cert. IVUSS,  
 CEO of SonoPath.com

**HOSPITAL NAME**

Greenwood Lake AH

**REFERRING VET**

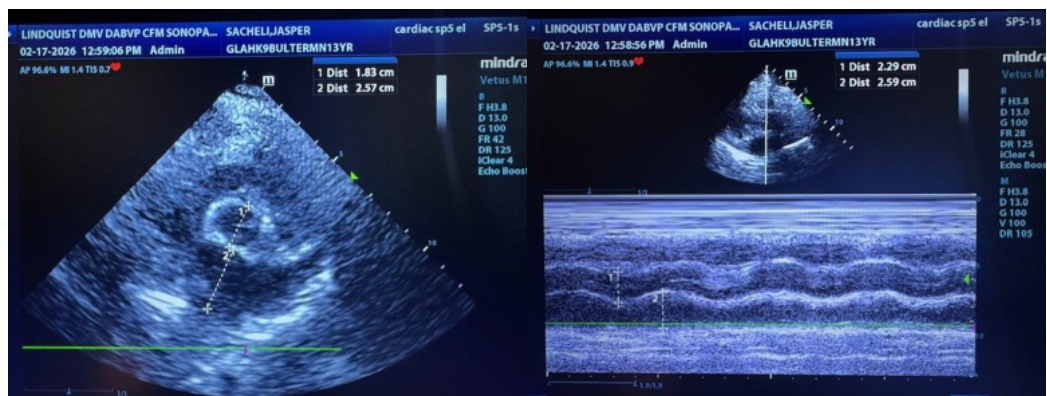
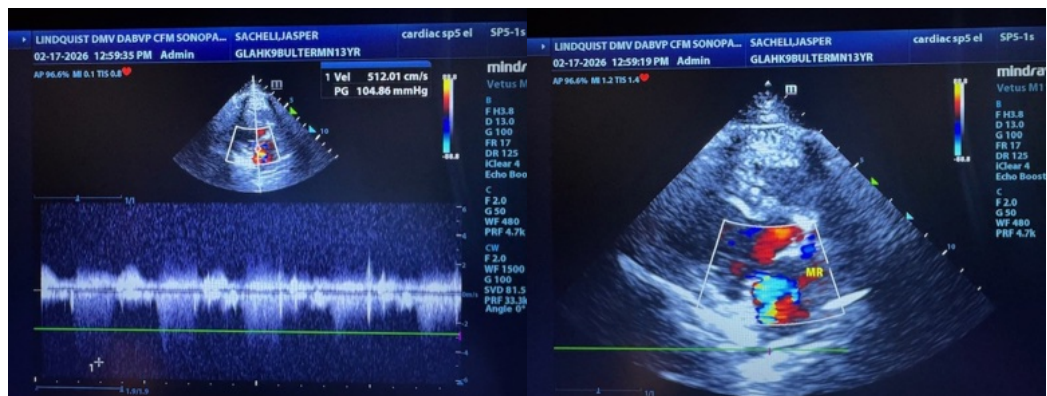
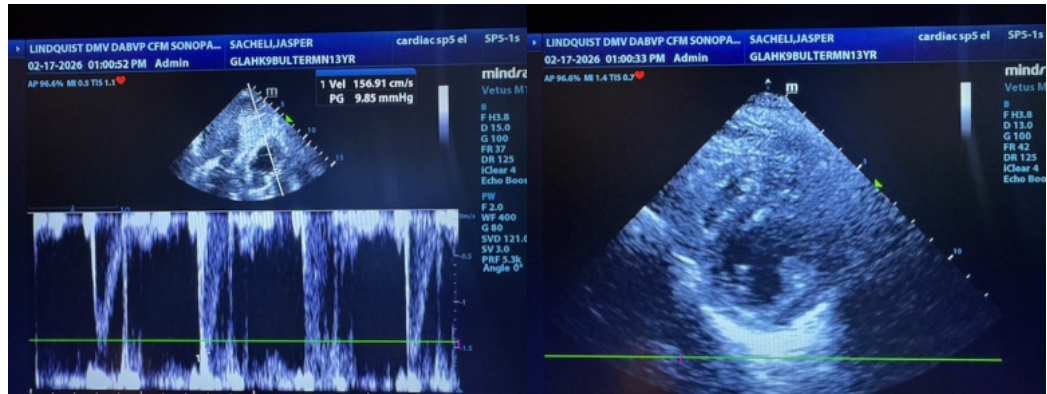
Dr. Price

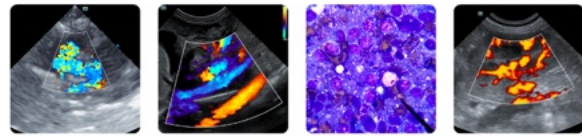
**INVOICE**

71612

**DATE**

2/17/26





**PATIENT**

Jasper Sacheli

**SPECIES**

Canine

**BREED**

Bull Terrier

**SEX**

Neutered male

**AGE**

13 years

**WEIGHT**

58 lbs

**INTERPRETED BY**

Eric Lindquist, DMV,  
 DABVP, Cert. IVUSS,  
 CEO of SonoPath.com

**IMAGING PERFORMED BY**

Eric Lindquist, DMV,  
 DABVP, Cert. IVUSS,  
 CEO of SonoPath.com

**HOSPITAL NAME**

Greenwood Lake AH

**REFERRING VET**

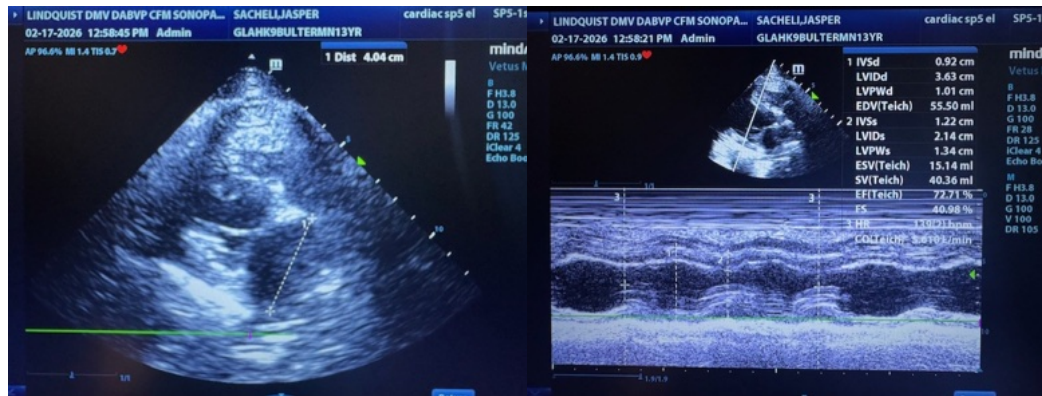
Dr. Price

**INVOICE**

71612

**DATE**

2/17/26



The information and recommendations provided are based on the images presented by the referring veterinarian/sonographer. No evaluation can be communicated regarding pathology that was not visible in the image/video clips provided.

Thank you for this referral. If the clinical or image interpretation does not parallel your findings or if I can be of any further assistance please contact me.

Eric Lindquist, DMV, DABVP, Cert. IVUSS, CEO of SonoPath.com

Info@SonoPath.com