



PATIENT

Ash Sodhi

SPECIES

Canine

BREED

Lhasa Apso

SEX

Male

AGE

3 years

WEIGHT

22.6 lbs

INTERPRETED BY

Eric Lindquist, DMV,
DABVP (CFM), Cert.
IVUSS, CEO of
SonoPath.com

IMAGING PERFORMED BY

Vincent Ravancho,
CVT

HOSPITAL NAME

Summit Dog and Cat
Hospital

REFERRING VET

Dr. Baker

INVOICE

71643

DATE

2/17/26

PRESENTING CLINICAL SIGNS

- Cardiomegaly on radiographs
- No medications for cardiac
- Occasional cough
- Medications: Lomotil

ULTRASONOGRAPHIC EXAMINATION OF THE HEART

The echocardiogram in this patient demonstrated normal **left atrial** size based on 3 separate methods of LA evaluation. The cranial and caudal **mitral** valve leaflets presented normal linear structure, extension in systole, and union in diastole with normal kinesis. The **left ventricle** presented thicknesses with linear contour and was not dilated nor restricted. The **myocardium** presented normal echogenicity without subjective evidence of significant fibrotic or ischemic disease. **Contractility** of the ventricular walls was adequate and in normal range for this patient evidenced by the fractional shortening measurement and subjective evaluation of the different regions of the myocardium. The **left ventricular outflow** tract demonstrated normal laminar flow and subjective structural integrity. The **right atrium** and auricle revealed normal size, structure and content. No evidence of masses was noted. **Tricuspid** valvular assessment demonstrated adequate linear morphology and kinesis. The **right ventricle** was of normal size (1/3 diameter of LV), chordae structure, myocardial echogenicity and thickness. **Pulmonary outflow** tract assessment revealed normal valve structure, laminar flow, and diameter (approx.1:1 pa/ao ratio). No visible **pericardial** or free pleura fluid was noted. The cranial **mediastinum and pericardial and extra-cardiac regions** were free of masses in the visible window.

CANINE CARDIAC PARAMETERS	MR VMAX (m/s)	TR VMAX (m/s)	LA/AO	LA/AO (Heart Base)	FS (%)	EF (%)	EPSS (cm)
NORMAL PARAMETER	4.5-5.5	<2.7	1.3	<1.6	28-40	40-100	<0.6
PATIENT	-	-	1.1	1.4	45	90	0.1
CANINE CARDIAC PARAMETERS	HR (BPM)	AV VMAX (m/s)	PV MAX (m/s)	BODY WEIGHT	LA 2D short axis Base view (cm)	LVIDd Avg; 2D and m-mode short axis (cm)	LVIDs Avg; 2D and m-mode short axis (cm)
NORMAL PARAMETER	50-100	0.7-1.7	0.7-1.6	BELOW	BELOW	BELOW	BELOW
PATIENT	-	1.2	0.7	22.6 lbs	2.6	2.4	

ULTRASONOGRAPHIC FINDINGS

Normal echocardiogram.



PATIENT

Ash Sodhi

SPECIES

Canine

BREED

Lhasa Apso

SEX

Male

AGE

3 years

WEIGHT

22.6 lbs

INTERPRETED BY

Eric Lindquist, DMV,
 DABVP (CFM), Cert.
 IVUSS, CEO of
 SonoPath.com

IMAGING PERFORMED BY

Vincent Ravancho,
 CVT

HOSPITAL NAME

Summit Dog and Cat
 Hospital

REFERRING VET

Dr. Baker

INVOICE

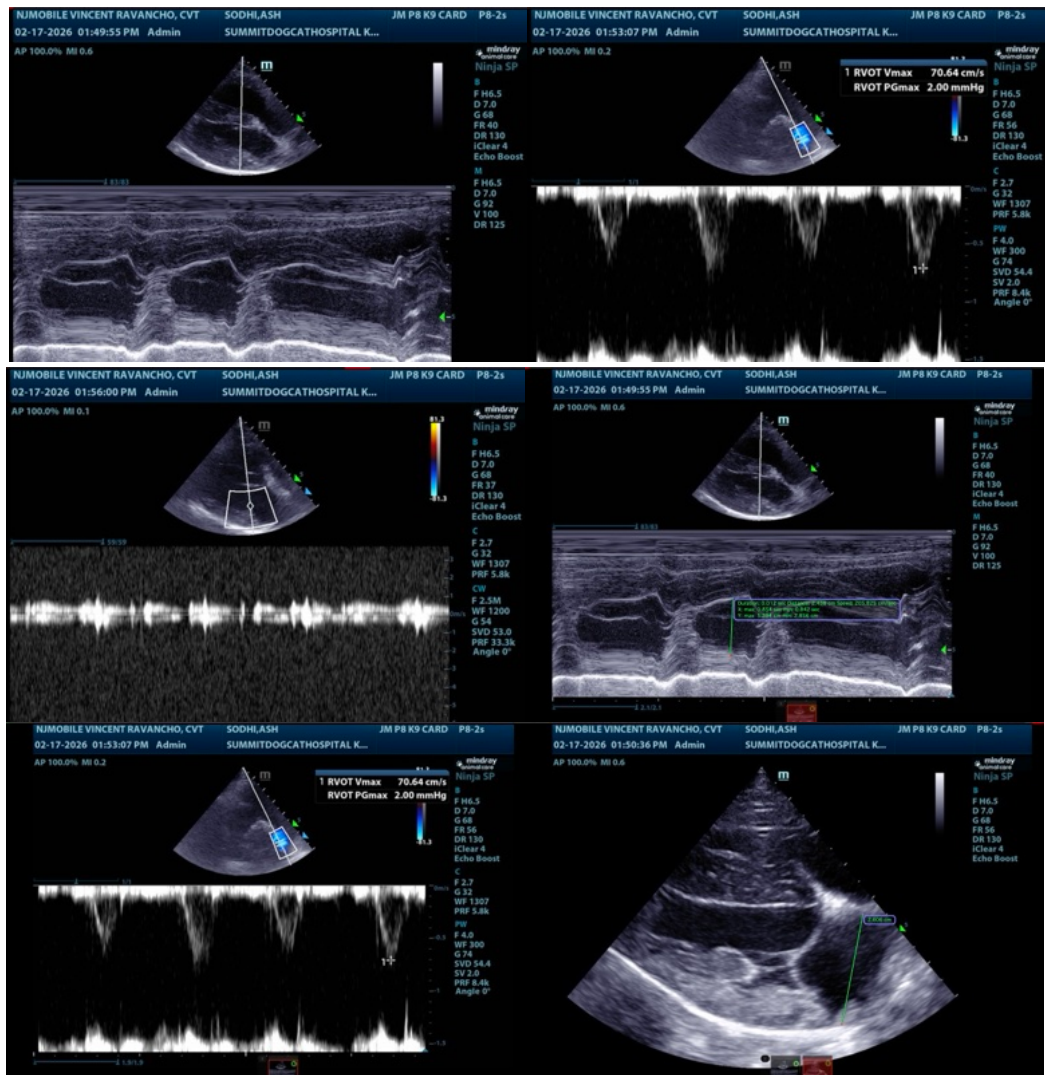
71643

DATE

2/17/26

INTERPRETATION OF THE FINDINGS & FURTHER RECOMMENDATIONS

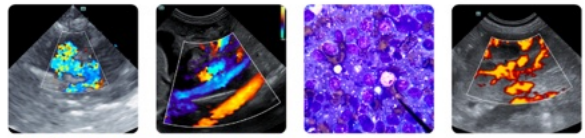
The appearance of cardiomegaly is likely a normal variant as structurally and functionally the heart is normal in this patient.



The information and recommendations provided are based on the images presented by the referring veterinarian/sonographer. No evaluation can be communicated regarding pathology that was not visible in the image/video clips provided.

Thank you for this referral. If the clinical or image interpretation does not parallel your findings or if I can be of any further assistance please contact me.

Eric Lindquist, DMV, DABVP (CFM), Cert. IVUSS, CEO of SonoPath.com



PATIENT

Info@SonoPath.com

Ash Sodhi

SPECIES

Canine

BREED

Lhasa Apso

SEX

Male

AGE

3 years

WEIGHT

22.6 lbs

INTERPRETED BY

Eric Lindquist, DMV,
DABVP (CFM), Cert.
IVUSS, CEO of
SonoPath.com

**IMAGING
PERFORMED BY**

Vincent Ravancho,
CVT

HOSPITAL NAME

Summit Dog and Cat
Hospital

REFERRING VET

Dr. Baker

INVOICE

71643

DATE

2/17/26