



**PATIENT**

Meatloaf Jersey Girls

**SPECIES**

Canine

**BREED**

Pitbull Mix

**SEX**

Neutered male

**AGE**

6 years

**WEIGHT**

50.4 lbs

**INTERPRETED BY**

Eric Lindquist, DMV,  
 DABVP (CFM), Cert.  
 IVUSS, CEO of  
 SonoPath.com

**IMAGING PERFORMED BY**

Vincent Ravancho,  
 CVT

**HOSPITAL NAME**

Plainfield AH

**REFERRING VET**

Dr. Lyons Brown

**INVOICE**

71588

**DATE**

2/16/26

**PRESENTING CLINICAL SIGNS**

- Grade II/VI HM, loudest m left
- Needs Anesthesia for COHAT
- Asymptomatic

**ULTRASONOGRAPHIC EXAMINATION OF THE HEART**

The echocardiogram in this patient demonstrated normal **left atrial** size based on 3 different LA measurement methods. Chamber volumes and echogenicity were normal. The cranial and caudal **mitral** valve leaflets presented vegetative thickening consistent with endocardiosis. Doppler indicated measurable insufficiency. The **left ventricle** presented thicknesses with linear contour and was not dilated nor restricted. The **myocardium** presented normal echogenicity without subjective evidence of significant fibrotic or ischemic disease. **Contractility** of the ventricular walls was adequate and in normal range for this patient evidenced by the fractional shortening measurement and subjective evaluation of the different regions of the myocardium. The **left ventricular outflow** tract demonstrated normal laminar flow and subjective structural integrity. The **right atrium** and auricle revealed normal size, structure and content. No evidence of masses was noted or chamber overload. **Tricuspid** valvular assessment demonstrated adequate linear morphology. The **right ventricle** was of normal size (1/3 diameter of LV), chordae structure, myocardial echogenicity and thickness. **Pulmonic** tract assessment revealed normal valve structure, laminar flow, and diameter (approx. 1:1 pa/ao ratio). No visible **pericardial** or free pleura fluid was noted. No echographically detectable evidence of infiltrative disease was visible. The cranial **mediastinum and pericardial regions** were free of masses in the visible window. The **hepatic** veins were not dilated.

<b>CANINE CARDIAC PARAMETERS</b>	<b>MR VMAX (m/s)</b>	<b>TR VMAX (m/s)</b>	<b>LA/AO</b>	<b>LA/AO (Heart Base)</b>	<b>FS (%)</b>	<b>EF (%)</b>	<b>EPSS (cm)</b>
<b>NORMAL PARAMETER</b>	4.5-5.5	<2.7	1.3	<1.6	28-40	40-100	<0.6
<b>PATIENT</b>	5.5	3.08	NM	1.6	40	80	0.68
<b>CANINE CARDIAC PARAMETERS</b>	<b>HR (BPM)</b>	<b>AV VMAX (m/s)</b>	<b>PV MAX (m/s)</b>	<b>BODY WEIGHT</b>	<b>LA 2D short axis Base view (cm)</b>	<b>LVIDd Avg; 2D and m-mode short axis (cm)</b>	<b>LVIDs Avg; 2D and m-mode short axis (cm)</b>
<b>NORMAL PARAMETER</b>	50-100	0.7-1.7	0.7-1.6	BELOW	BELOW	BELOW	BELOW
<b>PATIENT</b>	90	1.9	1.3	50.4 lbs	4.5	3.4	

**ULTRASONOGRAPHIC FINDINGS**

Mitral and tricuspid insufficiency, compensated at this time.

Stage B1 valvular disease.



**PATIENT**

Meatloaf Jersey Girls

**SPECIES**

Canine

**BREED**

Pitbull Mix

**SEX**

Neutered male

**AGE**

6 years

**WEIGHT**

50.4 lbs

**INTERPRETED BY**

Eric Lindquist, DMV,  
 DABVP (CFM), Cert.  
 IVUSS, CEO of  
 SonoPath.com

**IMAGING PERFORMED BY**

Vincent Ravancho,  
 CVT

**HOSPITAL NAME**

Plainfield AH

**REFERRING VET**

Dr. Lyons Brown

**INVOICE**

71588

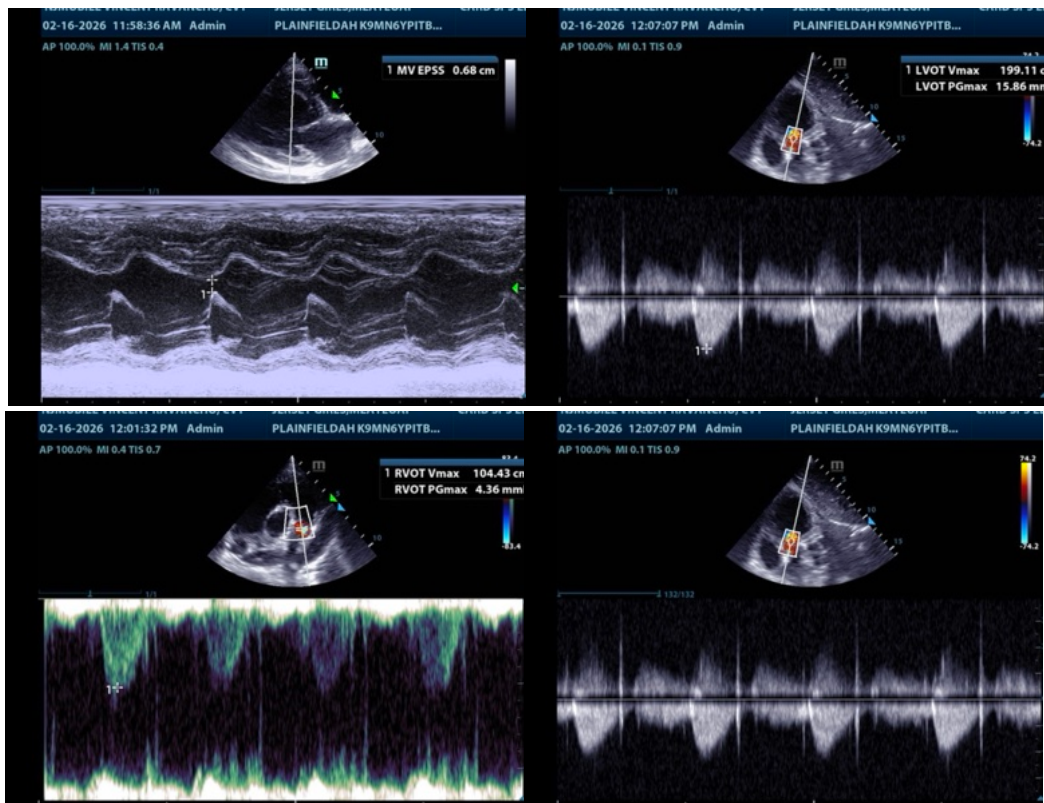
**DATE**

2/16/26

**INTERPRETATION OF THE FINDINGS & FURTHER RECOMMENDATIONS**

Potential mitral valve stenosis in this patient if the murmur has been present this patient's entire life some level of stenosis may be present in addition to the regurgitation. Some spectral flow suggests mitral valve stenosis. However, management is the same for B1 valvular disease at this time.

The heart is stable without clinical disease. No overt contraindication for anesthesia of brief to moderate duration. I suggest Torbutrol premed, Propofol induction, Isoflo maintenance or similar protocol if anesthesia is desired. Blood pressure recommended if not already performed and target white coat negative systolic pressure of < 160 mmHg. If higher than this ACE-inhibitor is suggested to reach this level. Recheck echocardiogram is recommended in 6 months, earlier if murmur grade increases or clinical signs initiate.





**PATIENT**

Meatloaf Jersey Girls

**SPECIES**

Canine

**BREED**

Pitbull Mix

**SEX**

Neutered male

**AGE**

6 years

**WEIGHT**

50.4 lbs

**INTERPRETED BY**

Eric Lindquist, DMV,  
 DABVP (CFM), Cert.  
 IVUSS, CEO of  
 SonoPath.com

**IMAGING PERFORMED BY**

Vincent Ravancho,  
 CVT

**HOSPITAL NAME**

Plainfield AH

**REFERRING VET**

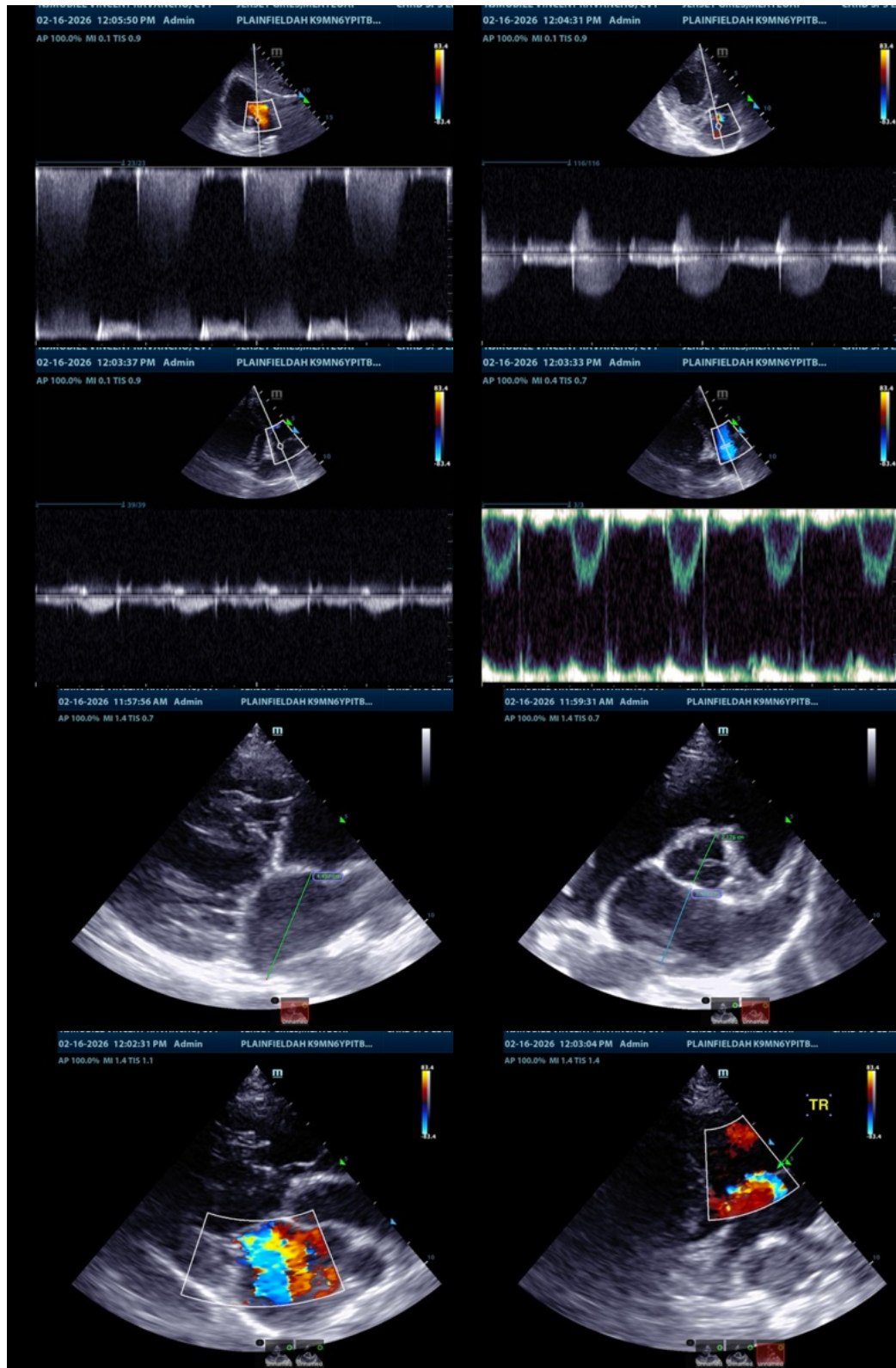
Dr. Lyons Brown

**INVOICE**

71588

**DATE**

2/16/26





**PATIENT**

Meatloaf Jersey Girls

**SPECIES**

Canine

**BREED**

Pitbull Mix

**SEX**

Neutered male

**AGE**

6 years

**WEIGHT**

50.4 lbs

**INTERPRETED BY**

Eric Lindquist, DMV,  
DABVP (CFM), Cert.  
IVUSS, CEO of  
SonoPath.com

**IMAGING  
PERFORMED BY**

Vincent Ravancho,  
CVT

**HOSPITAL NAME**

Plainfield AH

**REFERRING VET**

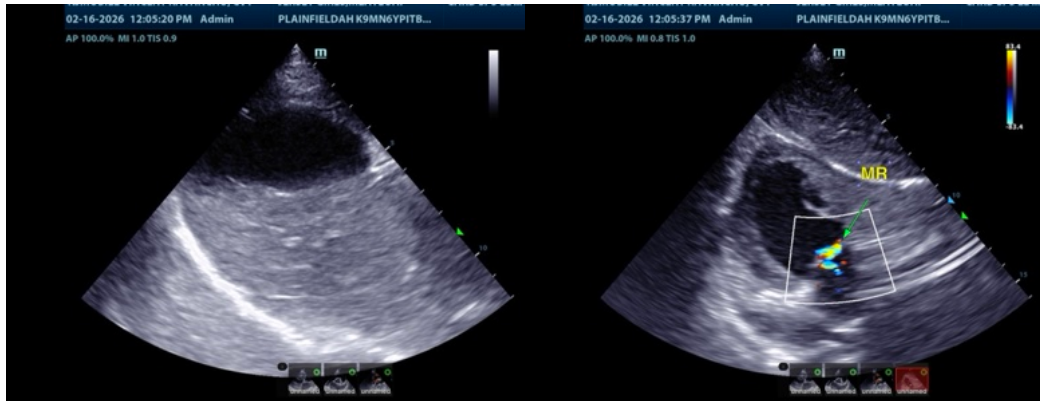
Dr. Lyons Brown

**INVOICE**

71588

**DATE**

2/16/26



The information and recommendations provided are based on the images presented by the referring veterinarian/sonographer. No evaluation can be communicated regarding pathology that was not visible in the image/video clips provided.

Thank you for this referral. If the clinical or image interpretation does not parallel your findings or if I can be of any further assistance please contact me.

Eric Lindquist, DMV, DABVP (CFM), Cert. IVUSS, CEO of SonoPath.com

Info@SonoPath.com