



**PATIENT**

Biscuit Kim

**SPECIES**

Feline

**BREED**

Domestic Medium Hair

**SEX**

Neutered male

**AGE**

4 years

**WEIGHT**

12 lbs

**INTERPRETED BY**

Eric Lindquist, DMV,  
 DABVP (CFM), Cert.  
 IVUSS, CEO of  
 SonoPath.com

**IMAGING PERFORMED BY**

Vincent Ravancho,  
 CVT

**HOSPITAL NAME**

Plainfield AH

**REFERRING VET**

Dr. Lyons-Brown

**INVOICE**

71587

**DATE**

2/16/26

**PRESENTING CLINICAL SIGNS**

- Dx w/ Grade III/VI HM about 1 yr ago. Asymptomatic
- Sedated with Gaba
- No medications

**ULTRASONOGRAPHIC EXAMINATION OF THE HEART**

The echocardiogram in this patient demonstrated normal **left atrial** size based on 3 separate LA measurements. **Mitral** valve insufficiency was noted in this patient. The **left ventricle** presented normal thicknesses with linear contour and was not dilated nor restricted. The **myocardium** presented normal echogenicity without subjective evidence of significant fibrotic or ischemic disease. **Contractility** of the ventricular walls was adequate and in normal range for this patient evidenced by the fractional shortening measurement and subjective evaluation of the different regions and angles of the myocardium. A **ventricular septal defect** appeared to be present in this patient with somewhat of a dysplastic valve measuring 0.6 cm. The **right atrium** and auricle revealed normal size, structure and content. No evidence of masses was noted or chamber overload. **Tricuspid** valvular assessment demonstrated adequate linear morphology and kinetics. The **right ventricle** presented mild hypertrophy. Increased RVOT velocity was also noted. This may be compensatory or potentially concurrent with pulmonic stenosis. No visible **pericardial** or free pleura fluid was noted or extra cardiac pathology in the visible planes. The cranial **mediastinum and pericardial regions** were free of masses in the visible window.

FELINE CARDIAC PARAMETERS	BODY WEIGHT	HR (BPM)	IVSd (cm)	LVIDd (cm)	LVWd (cm)	FS (%)	EF (%)
NORMAL PARAMETER	-----	150-240	0.3-0.6	1.0-2.1	0.25-0.6	35-67	80-100
PATIENT	12 lbs	186	0.3	1.8	0.5	41	74
FELINE CARDIAC PARAMETERS	LA/AO (M-mode)	LA/AO HEART BASE (Sisson)	LAD LA MAX 4 Chamber	LVOT VEL. (m/s)	RVOT VEL. (m/s)	IVRT (m/)	
NORMAL PARAMETER	<1.5	1.6	0.7-1.7	<1.6	<1.3	40-60	
PATIENT	1.1	1.0	1.4		0.9	NM	
Adapted from June Boon, Veterinary Echocardiography, 1998 Sisson D et al. JVIM 1991; 5: 232, Jacobs et al. Am J Vet Res 1985; 46:1705							



**PATIENT**

Biscuit Kim

**SPECIES**

Feline

**BREED**

Domestic Medium Hair

**SEX**

Neutered male

**AGE**

4 years

**WEIGHT**

12 lbs

**INTERPRETED BY**

Eric Lindquist, DMV,  
DABVP (CFM), Cert.  
IVUSS, CEO of  
SonoPath.com

**IMAGING PERFORMED BY**

Vincent Ravancho,  
CVT

**HOSPITAL NAME**

Plainfield AH

**REFERRING VET**

Dr. Lyons-Brown

**INVOICE**

71587

**DATE**

2/16/26

**ULTRASONOGRAPHIC FINDINGS**

Ventricular septal defect.

Right ventricular hypertrophy, yet compensated.

Dysplastic aortic valve.

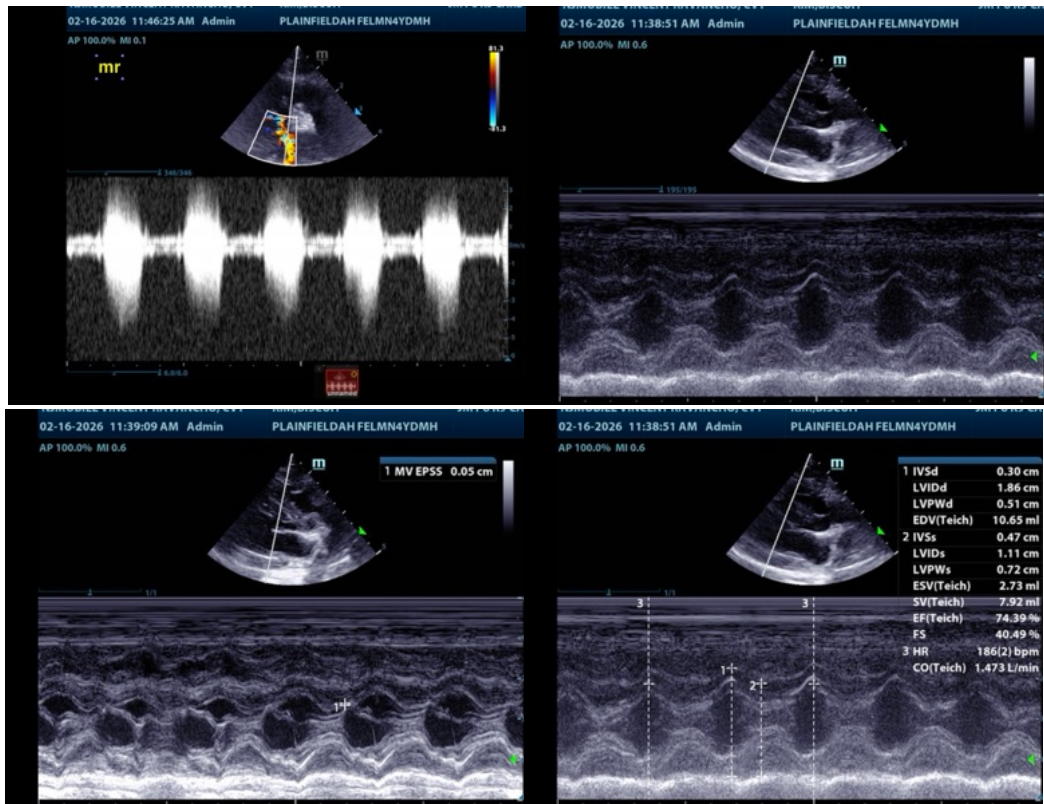
Increased RVOT.

Compensatory pulmonic outflow velocity or minor form of pulmonic stenosis, yet not hemodynamically significant.

Compensated mitral insufficiency. No evidence of volume overload.

**INTERPRETATION OF THE FINDINGS & FURTHER RECOMMENDATIONS**

Even though there are multiple defects in this patient, these appear to be compensated. There is no overt contraindication to anesthetic procedure at this time. A recheck echocardiogram is recommended in 6 months. No specific therapy is recommended at this time. The changes are consistent with congenital lesion.





**PATIENT**

Biscuit Kim

**SPECIES**

Feline

**BREED**

Domestic Medium Hair

**SEX**

Neutered male

**AGE**

4 years

**WEIGHT**

12 lbs

**INTERPRETED BY**

Eric Lindquist, DMV,  
 DABVP (CFM), Cert.  
 IVUSS, CEO of  
 SonoPath.com

**IMAGING PERFORMED BY**

Vincent Ravancho,  
 CVT

**HOSPITAL NAME**

Plainfield AH

**REFERRING VET**

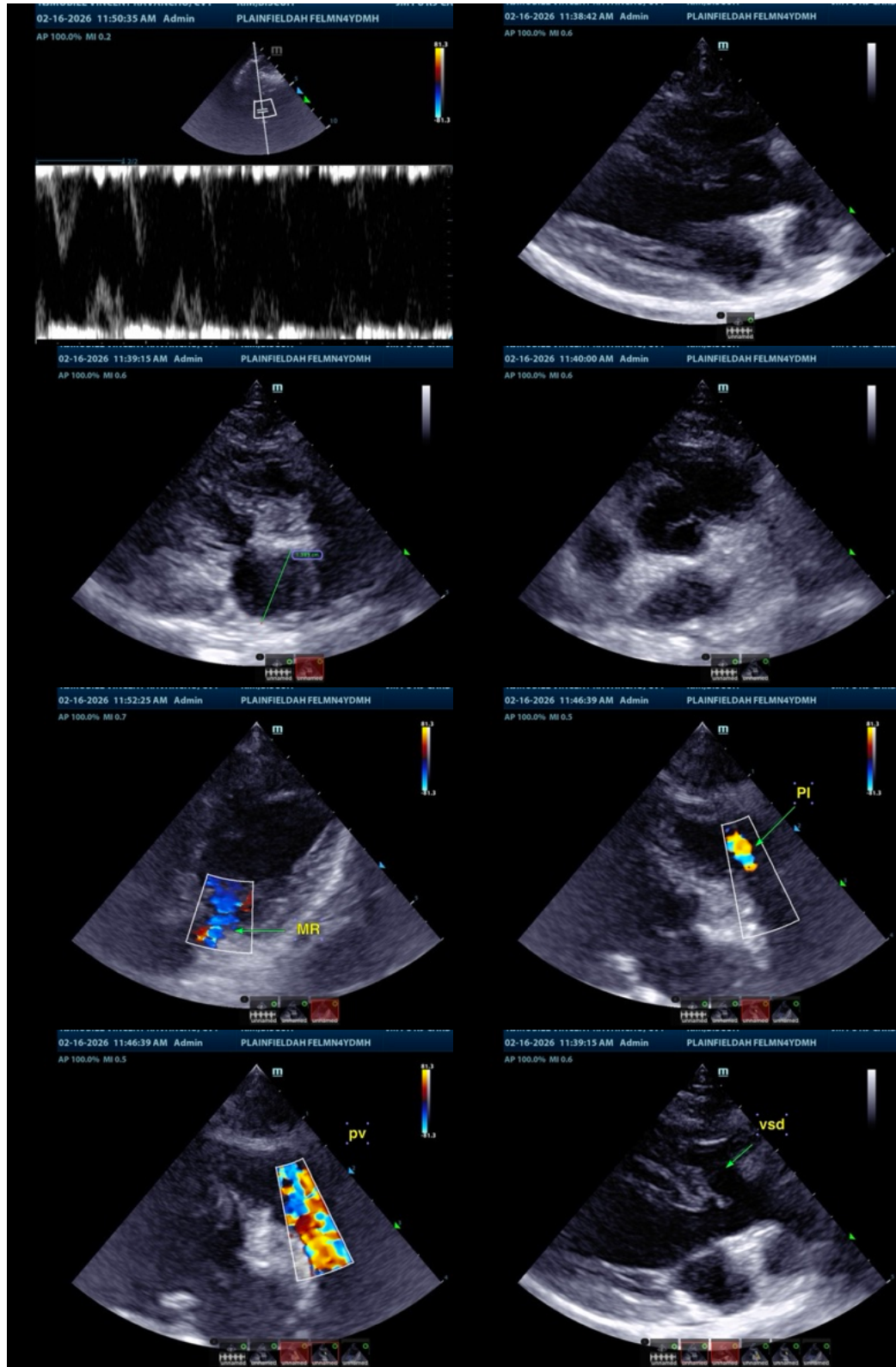
Dr. Lyons-Brown

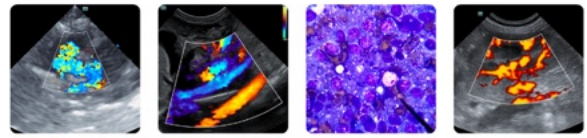
**INVOICE**

71587

**DATE**

2/16/26





**PATIENT**

Biscuit Kim

**SPECIES**

Feline

**BREED**

Domestic Medium Hair

**SEX**

Neutered male

**AGE**

4 years

**WEIGHT**

12 lbs

**INTERPRETED BY**

Eric Lindquist, DMV,  
DABVP (CFM), Cert.  
IVUSS, CEO of  
SonoPath.com

**IMAGING  
PERFORMED BY**

Vincent Ravancho,  
CVT

**HOSPITAL NAME**

Plainfield AH

**REFERRING VET**

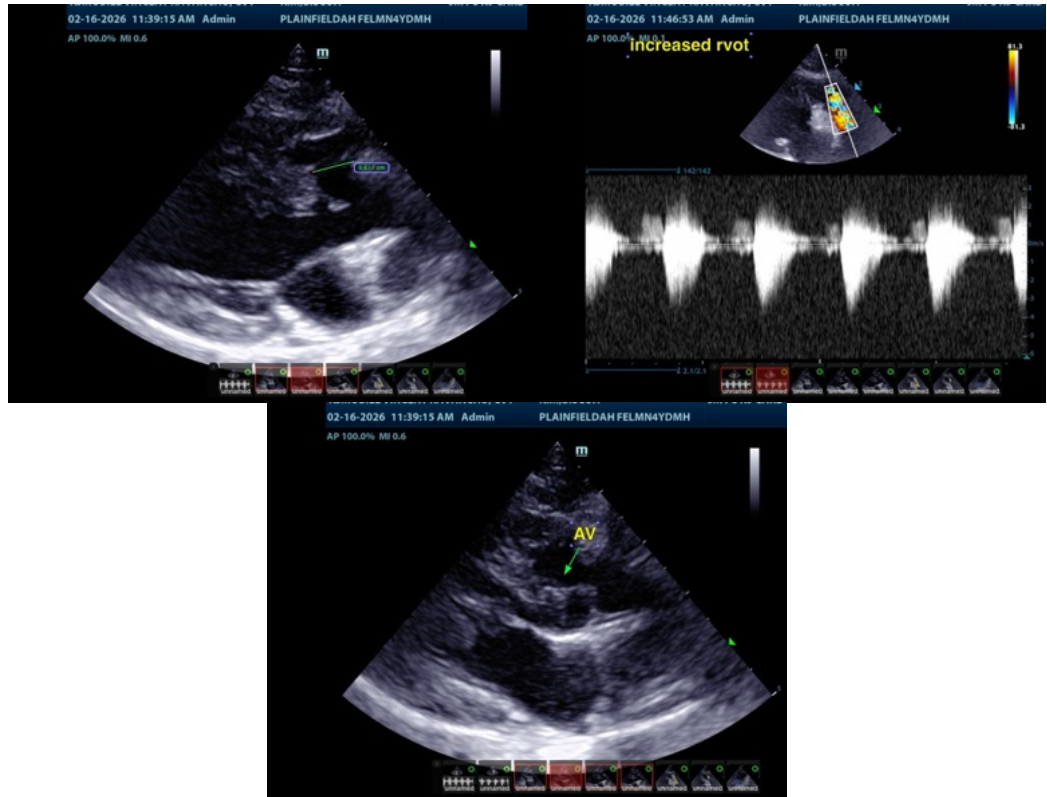
Dr. Lyons-Brown

**INVOICE**

71587

**DATE**

2/16/26



**The information and recommendations provided are based on the images presented by the referring veterinarian/sonographer. No evaluation can be communicated regarding pathology that was not visible in the image/video clips provided.**

Thank you for this referral. If the clinical or image interpretation does not parallel your findings or if I can be of any further assistance please contact me.

Eric Lindquist, DMV, DABVP (CFM), Cert. IVUSS, CEO of SonoPath.com

Info@SonoPath.com