



PATIENT

Prince Charming Johnson

SPECIES

Feline

BREED

Domestic Shorthair

SEX

Neutered male

AGE

13 years

WEIGHT

18.5 lbs

INTERPRETED BY

Eric Lindquist, DMV, DABVP, Cert. IVUSS, CEO of SonoPath.com

IMAGING PERFORMED BY

Meghan Morse, LVT, CVT

HOSPITAL NAME

East Fishkill AH

REFERRING VET

Dr. Baffi

INVOICE

71568

DATE

2/12/26

PRESENTING CLINICAL SIGNS

- Recheck echo. Cardiomyopathy, hypertrophic
- Current meds: Pred 3.7mg SID, Atenolol 6mg
- Labs WNL

ULTRASONOGRAPHIC EXAMINATION OF THE HEART

The echocardiogram in this patient demonstrated normal volumes and contractility. Septal and free wall thicknesses were within normal limits. There was no evidence of volume overload or pressure overload. Valvular structures were unremarkable. There was no pericardial or pleural effusion was noted. There was no arrhythmogenic activity was noted. The volumes are well contained. The hepatic veins were not dilated. There was no significant flow turbulence in any of the chambers or valves.

FELINE CARDIAC PARAMETERS	BODY WEIGHT	HR (BPM)	IVSd (cm)	LVIDd (cm)	LVWd (cm)	FS (%)	EF (%)
NORMAL PARAMETER	-----	150-240	0.3-0.6	1.0-2.1	0.25-0.6	35-67	80-100
PATIENT	18.5 lbs	200	0.38	2.0	0.4	60	91
FELINE CARDIAC PARAMETERS	LA/AO (M-mode)	LA/AO HEART BASE (Sisson)	LAD LA MAX 4 Chamber		LVOT VEL. (m/s)	RVOT VEL. (m/s)	IVRT (m/)
NORMAL PARAMETER	<1.5	1.6	0.7-1.7		<1.6	<1.3	40-60
PATIENT	1.3	1.26	1.2		1.0	0.91	NM
Adapted from June Boon, Veterinary Echocardiography, 1998 Sisson D et al. JVIM 1991; 5: 232, Jacobs et al. Am J Vet Res 1985; 46:1705							

ULTRASONOGRAPHIC FINDINGS

Essential normal geriatric heart.

INTERPRETATION OF THE FINDINGS & FURTHER RECOMMENDATIONS

No further cardiac medications are recommended in this patient based on the echocardiogram finding, which is essentially normal. If Atenolol is being utilized for history of arrhythmogenic activity then it could be continued. However, there is no structural evidence of disease that would suggest Atenolol was necessary in this patient at this time.



PATIENT

Prince Charming
 Johnson

SPECIES

Feline

BREED

Domestic Shorthair

SEX

Neutered male

AGE

13 years

WEIGHT

18.5 lbs

INTERPRETED BY

Eric Lindquist, DMV,
 DABVP, Cert. IVUS,
 CEO of SonoPath.com

IMAGING PERFORMED BY

Meghan Morse, LVT,
 CVT

HOSPITAL NAME

East Fishkill AH

REFERRING VET

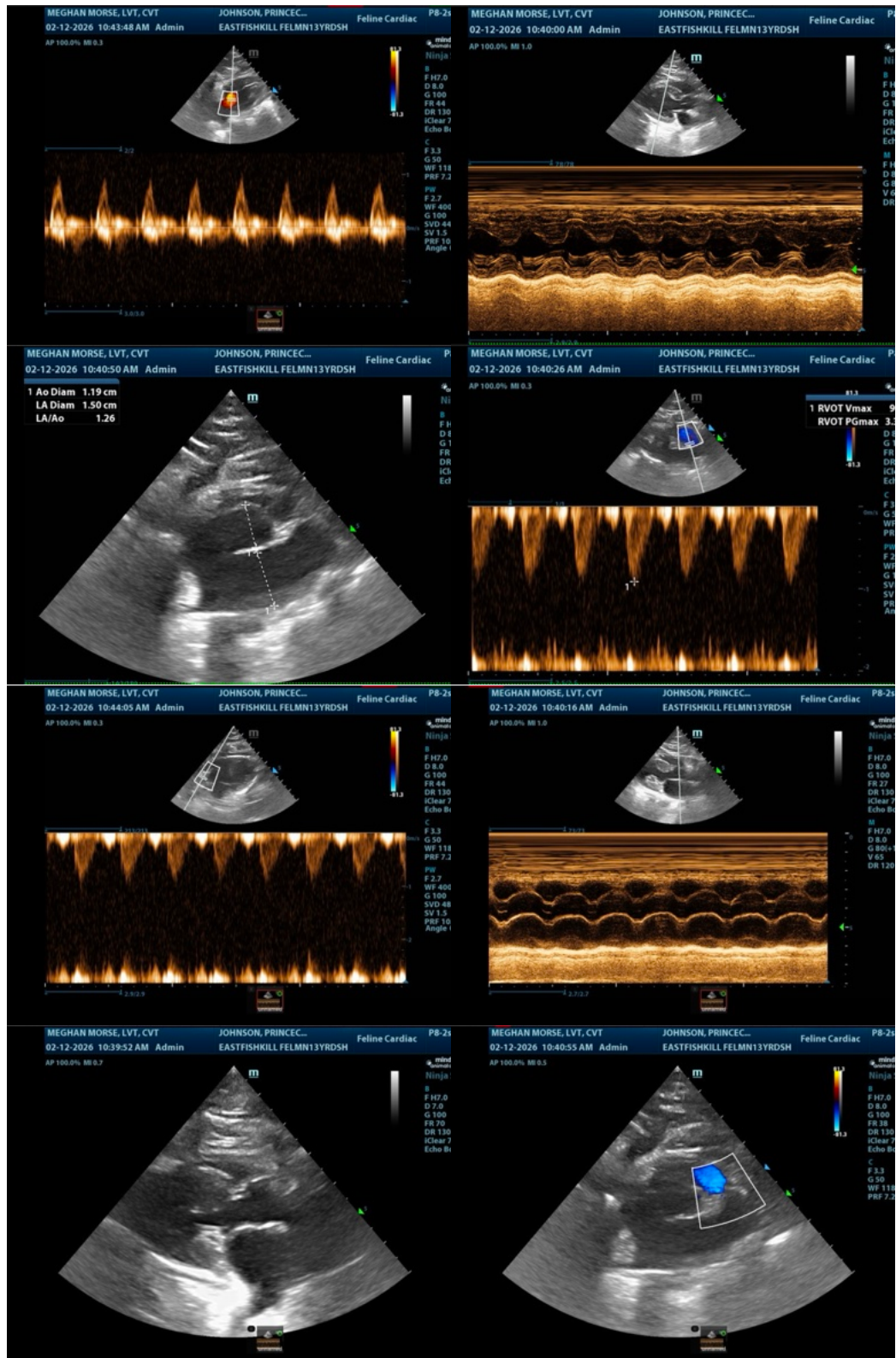
Dr. Baffi

INVOICE

71568

DATE

2/12/26





PATIENT

Prince Charming
Johnson

SPECIES

Feline

BREED

Domestic Shorthair

SEX

Neutered male

AGE

13 years

WEIGHT

18.5 lbs

INTERPRETED BY

Eric Lindquist, DMV,
DABVP, Cert. IVUSS,
CEO of SonoPath.com

**IMAGING
PERFORMED BY**

Meghan Morse, LVT,
CVT

HOSPITAL NAME

East Fishkill AH

REFERRING VET

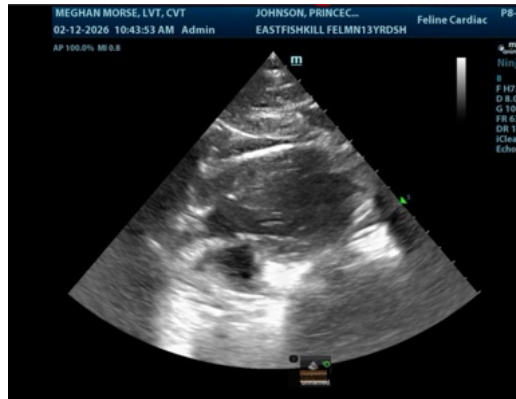Dr. Baffi

INVOICE

71568

DATE

2/12/26



The information and recommendations provided are based on the images presented by the referring veterinarian/sonographer. No evaluation can be communicated regarding pathology that was not visible in the image/video clips provided.

Thank you for this referral. If the clinical or image interpretation does not parallel your findings or if I can be of any further assistance please contact me.

Eric Lindquist, DMV, DABVP, Cert. IVUSS, CEO of SonoPath.com

Info@SonoPath.com