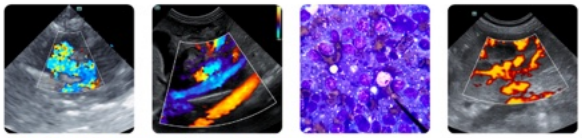

Clinical Sonography & Telecytology
Educational Teleconsultation Services™

PATIENT
Lilian Misrendino

SPECIES
Feline

BREED
Domestic Shorthair

SEX
Spayed female

AGE
4 years

WEIGHT
6.5 lbs

INTERPRETED BY
Eric Lindquist, DMV, DABVP, Cert. IVUSS, CEO of SonoPath.com

IMAGING PERFORMED BY
Shari Reffi, CVT

HOSPITAL NAME
Magnolia Veterinary Practice

REFERRING VET
Dr. Goldstein

INVOICE
71565

DATE
2/12/26

PRESENTING CLINICAL SIGNS

- Heart murmur 3-4/6. Needs dental
- Ca elevated Glu mild elevation suspect stress

ULTRASONOGRAPHIC EXAMINATION OF THE HEART

The echocardiogram in this patient demonstrated normal **left atrial** size based on 3 separate LA measurements. The cranial and caudal **mitral** valve leaflets presented normal linear structure and kinetics.. The **left ventricle** presented normal thicknesses with linear contour and was not dilated nor restricted. The **myocardium** presented normal echogenicity without subjective evidence of significant fibrotic or ischemic disease. **Contractility** of the ventricular walls was adequate and in normal range for this patient evidenced by the fractional shortening measurement and subjective evaluation of the different regions and angles of the myocardium. The **left ventricular outflow** tract demonstrated normal laminar flow and subjective structural integrity. The **right atrium** and auricle revealed normal size, structure and content. No evidence of masses was noted or chamber overload. **Tricuspid** valvular assessment demonstrated adequate linear morphology and kinetics. The **right ventricle** was of normal size (1/3 diameter of LV), chordae structure, myocardial echogenicity and thickness. **Pulmonic** tract assessment revealed normal valve structure, laminar flow, and diameter (approx.1:1 pa/ao ratio). No visible **pericardial** or free pleura fluid was noted or extra cardiac pathology in the visible planes. The cranial **mediastinum and pericardial regions** were free of masses in the visible window. The patient was tachycardic.

FELINE CARDIAC PARAMETERS	BODY WEIGHT	HR (BPM)	IVSd (cm)	LVIDd (cm)	LVWd (cm)	FS (%)	EF (%)
NORMAL PARAMETER	------	150-240	0.3-0.6	1.0-2.1	0.25-0.6	35-67	80-100
PATIENT	6.5 lbs	230	0.5	1.4	0.5	50	90
FELINE CARDIAC PARAMETERS	**LA/AO** (M-mode)	**LA/AO HEART BASE** (Sisson)	**LAD** LA MAX 4 Chamber		**LVOT VEL.** (m/s)	**RVOT VEL.** (m/s)	**IVRT** (m/)
NORMAL PARAMETER	<1.5	1.6	0.7-1.7		<1.6	<1.3	40-60
PATIENT	1.03	1.22	1.2		1.1	0.71	NM

Adapted from June Boon,Veterinary Echocardiography,1998
Sisson D et al. JVIM 1991; 5: 232, Jacobs et al. Am J Vet Res 1985; 46:1705

ULTRASONOGRAPHIC FINDINGS

Idiopathic flow murmur.

PATIENT

Lilian Misrendino

SPECIES

Feline

BREED

Domestic Shorthair

SEX

Spayed female

AGE

4 years

WEIGHT

6.5 lbs

INTERPRETED BY

Eric Lindquist, DMV, DABVP, Cert. IVUSS, CEO of SonoPath.com

IMAGING PERFORMED BY

Shari Reffi, CVT

HOSPITAL NAME

Magnolia Veterinary Practice

REFERRING VET

Dr. Goldstein

INVOICE

71565

DATE

2/12/26

INTERPRETATION OF THE FINDINGS & FURTHER RECOMMENDATIONS

There was no evidence of clinically significant disease.

Benign flow murmurs are common in cats. This may be owing to volume shifts, tachycardia, benign (DRVOTO) right ventricular outflow changes, trivial turbulence in any of the valvular apparatuses, or possibly excessive stethoscope pressure against the chest according to a recent study These are physiologically benign and unrelated to specific pathology.

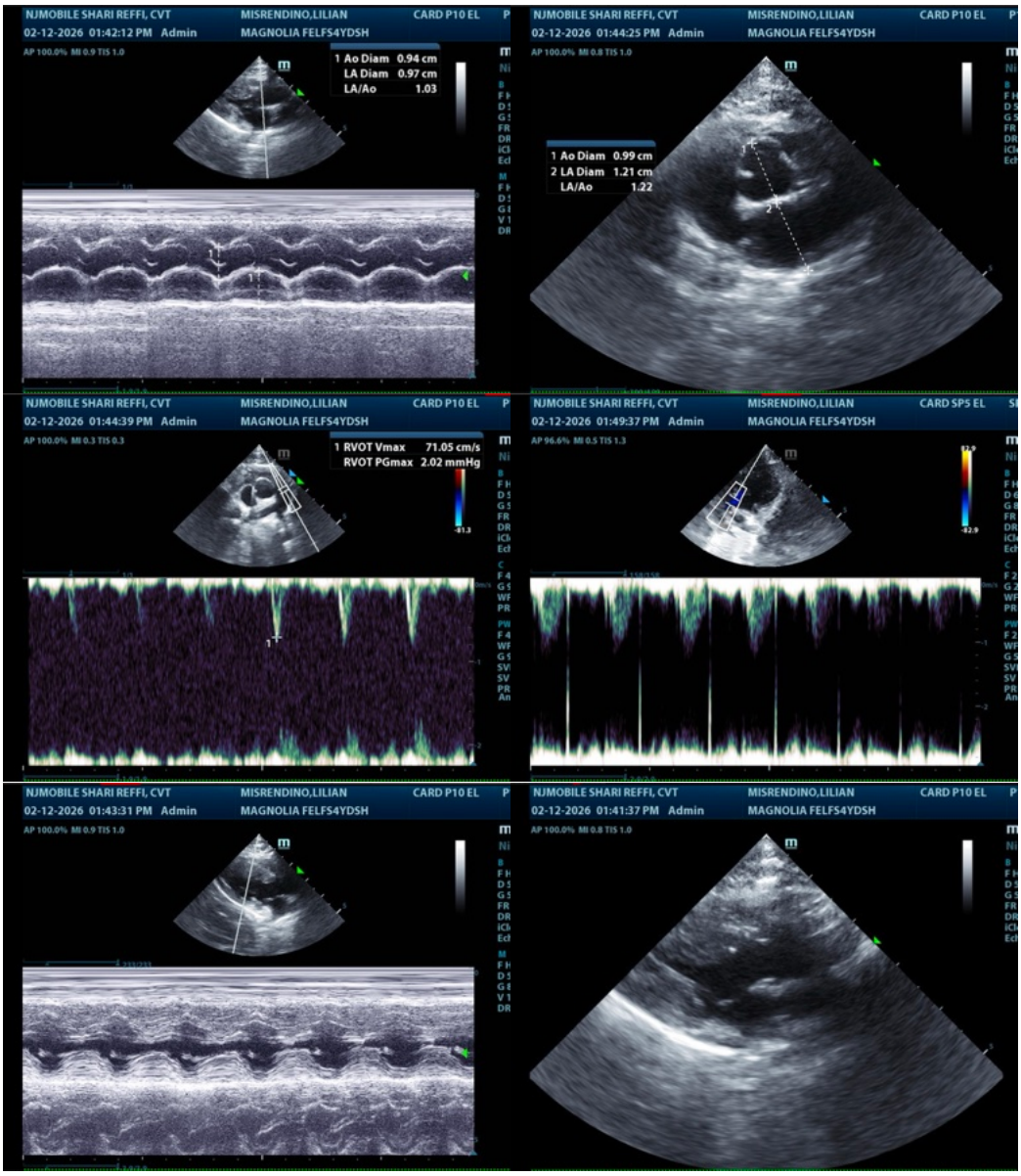

New Jersey Mobile
FUELED BY SONOPATH VETERINARY ULTRASOUND

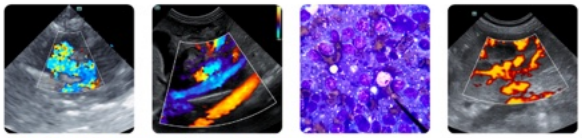

Clinical Sonography & Telecytology
Educational Teleconsultation Services™

SonoPath
FOSTERING THE ART OF VETERINARY MEDICINE™
www.SonoPath.com
info@sonopath.com 800.838.4268

PATIENT

Lilian Misrendino

SPECIES

Feline

BREED

Domestic Shorthair

SEX

Spayed female

AGE

4 years

WEIGHT

6.5 lbs

INTERPRETED BY

Eric Lindquist, DMV, DABVP, Cert. IVUSS, CEO of SonoPath.com

IMAGING PERFORMED BY

Shari Reffi, CVT

HOSPITAL NAME

Magnolia Veterinary Practice

REFERRING VET

Dr. Goldstein

INVOICE

71565

DATE

2/12/26

The information and recommendations provided are based on the images presented by the referring veterinarian/sonographer. No evaluation can be communicated regarding pathology that was not visible in the image/video clips provided.

Thank you for this referral. If the clinical or image interpretation does not parallel your findings or if I can be of any further assistance please contact me.

Eric Lindquist, DMV, DABVP, Cert. IVUSS, CEO of SonoPath.com

Info@SonoPath.com