



PATIENT

Daisy Ammirato

SPECIES

Canine

BREED

Shih Tzu

SEX

Spayed female

AGE

11 years

WEIGHT

15 lbs

INTERPRETED BY

Eric Lindquist, DMV,
DABVP, Cert. IVUSS,
CEO of SonoPath.com

IMAGING PERFORMED BY

Shari Reffi, CVT

HOSPITAL NAME

William Penn VH

REFERRING VET

Dr. Bouzaout

INVOICE

71562

DATE

2/12/26

PRESENTING CLINICAL SIGNS

- Seizures, vomiting, diarrhea.
- Cardiomegaly, heart murmur 4/6
- keppra 250mgs 1/2t PO TID, sulfatrim liquid
- UA - infection ALT increased , BUN increased

ULTRASONOGRAPHIC EXAMINATION OF THE ABDOMEN

Urinary System

The **urinary bladder**, trigone, and pelvic urethra presented normal thicknesses and normal tone. The ureters were not visible which is normal. No uroliths or sediment were visualized and anechoic urine was present. No evidence of inflammatory or neoplastic changes was noted. Ureteral papillae were normal.

The **kidneys** revealed largely normal size and structure, corticomedullary definition and ratio (cortex 1/3 of medulla) were essentially maintained with some age-related loss of curvilinear patterns regarding the capsule and C/M junction. The cortices presented largely uniform texture with some increased echogenicity expected for this age patient. Medullary structure differed distinctly from that of the cortex and no evidence of pelvic dilation was present. The left kidney measured 3.57 cm. The right kidney measured 4.7 cm The dorsal caudal aspect of the mass, which is presumed to be liver, impinges upon the dorsal cortex of the right kidney. I cannot completely rule out the potential of a right renal origin, yet this is most likely hepatic in origin.

Adrenal Glands

Both **adrenal glands** were visualized and recognized as having normal shape, size, position and echogenicity for this breed. The phrenic vasculature, glandular echogenicity and detail were unremarkable. Capsule, cortex, and medullary definition were normal for this age patient. The right adrenal gland measured 1.7 x 0.9 cm at the cranial pole and 0.54 cm at the caudal pole. The left adrenal gland was slightly enlarged at the caudal pole measuring 0.67 cm at the caudal pole and 0.39 cm at the cranial pole.

Spleen

The **spleen** presented a smooth homogeneous parenchyma hyperechoic to liver and renal cortical parenchyma. The capsule was smooth without noticeable expansion or deviation from within the spleen or adjacent pathology. The splenic vasculature demonstrated normal volume without signs of congestion or thrombosis. No sonographic evidence of acute or chronic inflammatory, neoplastic, or infarctual changes was noted.

Liver

The **liver** images from right and left intercostal as well as subcostal views revealed subjectively normal liver size, contour, and structure. Some age-related parenchymal remodeling was noted but likely not



PATIENT

Daisy Ammirato

SPECIES

Canine

BREED

Shih Tzu

SEX

Spayed female

AGE

11 years

WEIGHT

15 lbs

INTERPRETED BY

Eric Lindquist, DMV,
DABVP, Cert. IVUSS,
CEO of SonoPath.com

IMAGING PERFORMED BY

Shari Reffi, CVT

HOSPITAL NAME

William Penn VH

REFERRING VET

Dr. Bouzaout

INVOICE

71562

DATE

2/12/26

clinically significant at this time. The liver revealed a 6.8 cm, mixed hypoechoic, cystic and peripherally inflamed mass. The mass appeared to be deriving from the right caudal liver. Vascular and biliary tracts were of normal volume and no evidence of congestion was noted. The gallbladder presented some dependent debris with essentially normal contour. The cystic and common bile ducts were normal. The hepatic lymph nodes were unremarkable.

Gastrointestinal

Examination of the **gastrointestinal tract** revealed a stomach and intestine free of stasis, of normal wall thickness, acceptable curvilinear mural detail, and peristaltic activity. Small and large intestine demonstrated normal luminal chyme and stool consistency respectively. No obstructive or overt infiltrative disease was noted. No associated abnormal lymphatic activity was noted.

Pancreas

The hepatic mass superimposed the **pancreas**. Secondary inflammation was noted in the pancreas.

ULTRASONOGRAPHIC EXAMINATION OF THE HEART

The echocardiogram in this patient demonstrated normal **left atrial** size based on 3 different LA measurement methods. Chamber volumes and echogenicity were normal. The cranial and caudal **mitral** valve leaflets presented vegetative thickening consistent with endocardiosis. Doppler indicated measurable insufficiency. The **left ventricle** presented thicknesses with linear contour and was not dilated nor restricted. The **myocardium** presented normal echogenicity without subjective evidence of significant fibrotic or ischemic disease. **Contractility** of the ventricular walls was adequate and in normal range for this patient evidenced by the fractional shortening measurement and subjective evaluation of the different regions of the myocardium. The **left ventricular outflow** tract demonstrated normal laminar flow and subjective structural integrity. The **right atrium** and auricle revealed normal size, structure and content. No evidence of masses was noted or chamber overload. **Tricuspid** valvular assessment demonstrated adequate linear morphology. The **right ventricle** was of normal size (1/3 diameter of LV), chordae structure, myocardial echogenicity and thickness. **Pulmonic** tract assessment revealed normal valve structure, laminar flow, and diameter (approx. 1:1 pa/ao ratio). No visible **pericardial** or free pleura fluid was noted. No echographically detectable evidence of infiltrative disease was visible. The cranial **mediastinum and pericardial regions** were free of masses in the visible window.



PATIENT

Daisy Ammirato

SPECIES

Canine

BREED

Shih Tzu

SEX

Spayed female

AGE

11 years

WEIGHT

15 lbs

INTERPRETED BY

Eric Lindquist, DMV,
 DABVP, Cert. IVUSS,
 CEO of SonoPath.com

IMAGING PERFORMED BY

Shari Reffi, CVT

HOSPITAL NAME

William Penn VH

REFERRING VET

Dr. Bouzaout

INVOICE

71562

DATE

2/12/26

CANINE CARDIAC PARAMETERS	MR VMAX (m/s)	TR VMAX (m/s)	LA/AO	LA/AO (Heart Base)	FS (%)	EF (%)	EPSS (cm)
NORMAL PARAMETER	4.5-5.5	<2.7	1.3	<1.6	28-40	40-100	<0.6
PATIENT	5.58	2.61	1.12	1.25	28	56	0.1
CANINE CARDIAC PARAMETERS	HR (BPM)	AV VMAX (m/s)	PV MAX (m/s)	BODY WEIGHT	LA 2D short axis Base view (cm)	LVIDd Avg; 2D and m-mode short axis (cm)	LVIDs Avg; 2D and m-mode short axis (cm)
NORMAL PARAMETER	50-100	0.7-1.7	0.7-1.6	BELOW	BELOW	BELOW	BELOW
PATIENT	152	-	0.62	15 lbs	2.3	2.45	

ULTRASONOGRAPHIC FINDINGS

Stage B1 valvular disease.

Suspect hepatic mass, which impinged upon the pancreas and right kidney. There is a potential that the mass is deriving from right kidney. Suspect carcinoma, possibility of complex hepatoma.

INTERPRETATION OF THE FINDINGS & FURTHER RECOMMENDATIONS

FNA of the hepatic mass can be considered or better yet CT evaluation for potential surgical planning. The mass impinges dorsally upon the vena cava and portal vein, yet may be surgically resectable. FNA can be performed at the time of CT to assess for carcinoma versus necrotic or granulomatous lesion.

The heart is stable without clinical disease. No overt contraindication for anesthesia of brief to moderate duration. I suggest Torbutrol premed, Propofol induction, Isoflor maintenance or similar protocol if anesthesia is desired. Blood pressure recommended if not already performed and target white coat negative systolic pressure of < 160 mmHg. If higher than this ACE-inhibitor is suggested to reach this level. Recheck echocardiogram is recommended in 6 months, earlier if murmur grade increases or clinical signs initiate.



PATIENT

Daisy Ammirato

SPECIES

Canine

BREED

Shih Tzu

SEX

Spayed female

AGE

11 years

WEIGHT

15 lbs

INTERPRETED BY

Eric Lindquist, DMV,
 DABVP, Cert. IVUSS,
 CEO of SonoPath.com

IMAGING PERFORMED BY

Shari Reffi, CVT

HOSPITAL NAME

William Penn VH

REFERRING VET

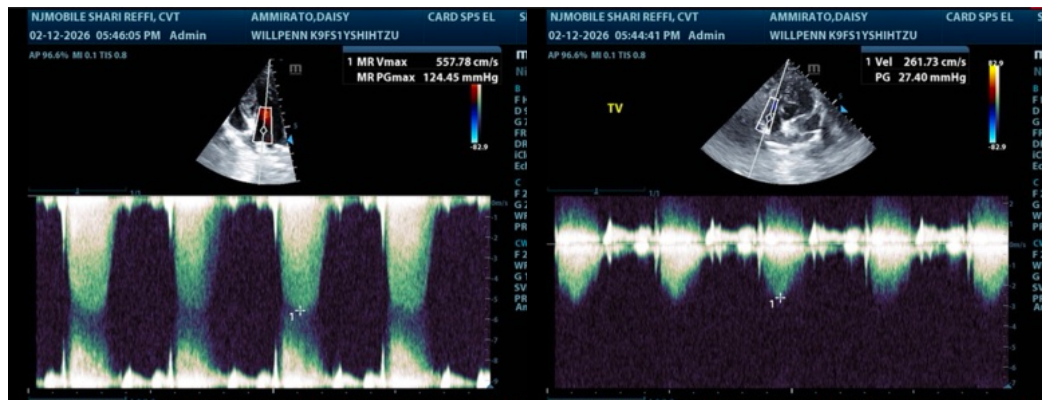
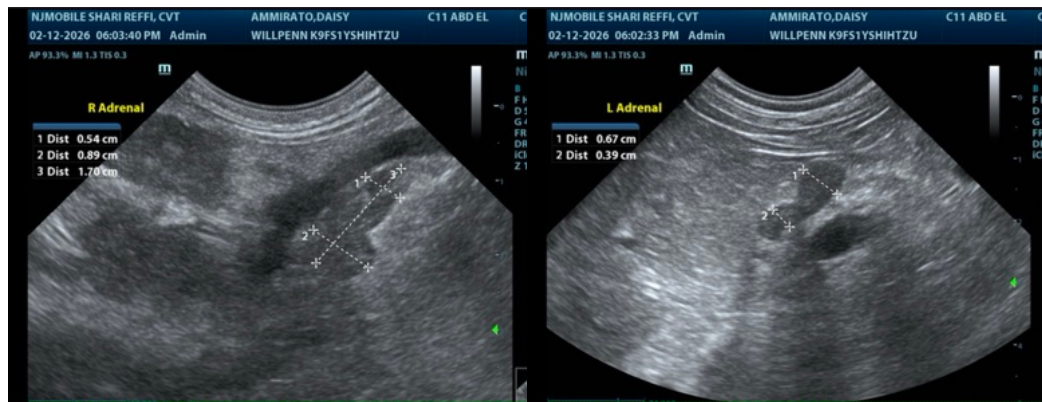
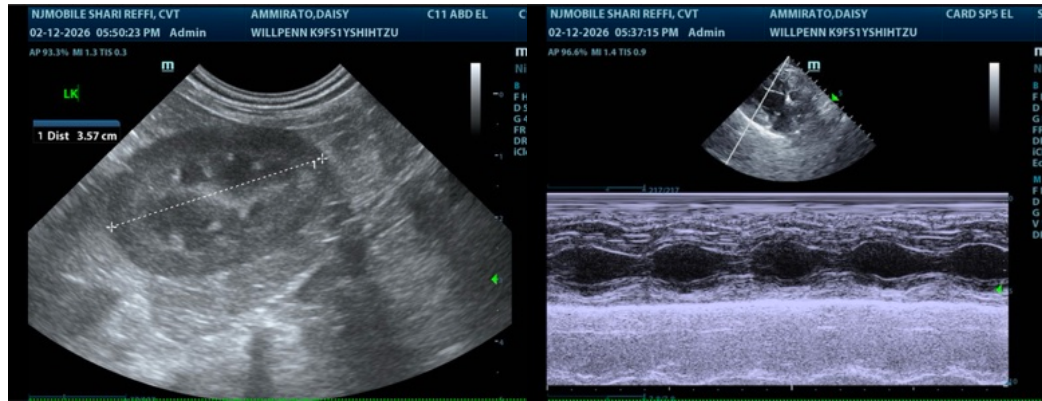
Dr. Bouzaout

INVOICE

71562

DATE

2/12/26





PATIENT

Daisy Ammirato

SPECIES

Canine

BREED

Shih Tzu

SEX

Spayed female

AGE

11 years

WEIGHT

15 lbs

INTERPRETED BY

Eric Lindquist, DMV,
 DABVP, Cert. IVUSS,
 CEO of SonoPath.com

IMAGING PERFORMED BY

Shari Reffi, CVT

HOSPITAL NAME

William Penn VH

REFERRING VET

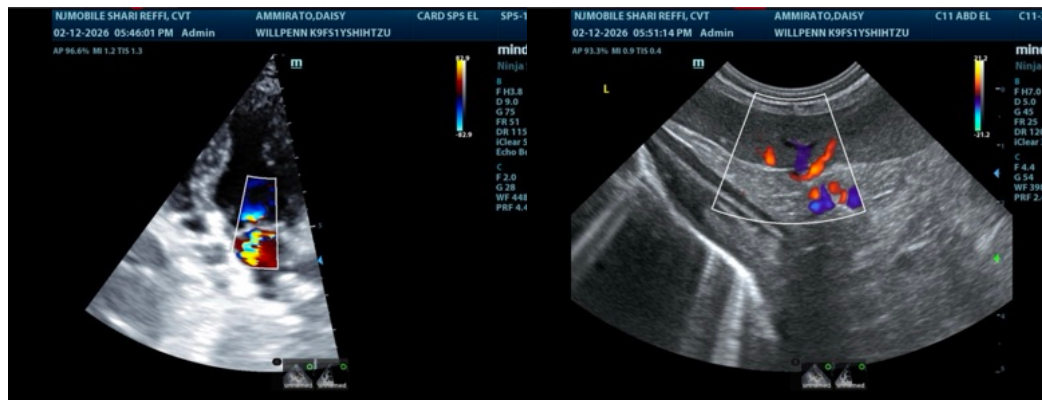
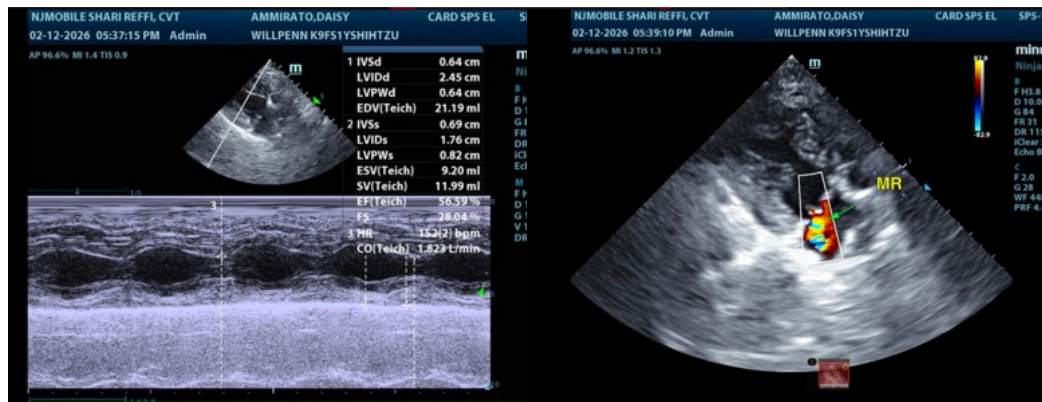
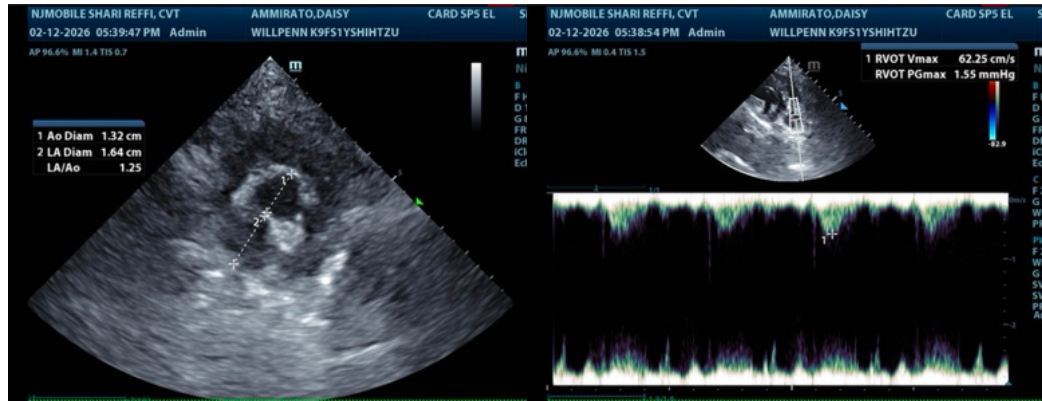
Dr. Bouzaout

INVOICE

71562

DATE

2/12/26





PATIENT

Daisy Ammirato

SPECIES

Canine

BREED

Shih Tzu

SEX

Spayed female

AGE

11 years

WEIGHT

15 lbs

INTERPRETED BY

Eric Lindquist, DMV,
 DABVP, Cert. IVUSS,
 CEO of SonoPath.com

IMAGING PERFORMED BY

Shari Reffi, CVT

HOSPITAL NAME

William Penn VH

REFERRING VET

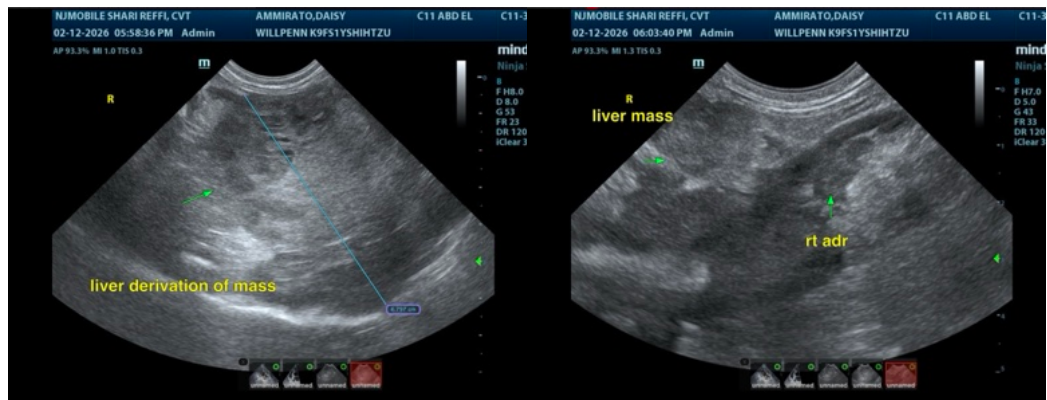
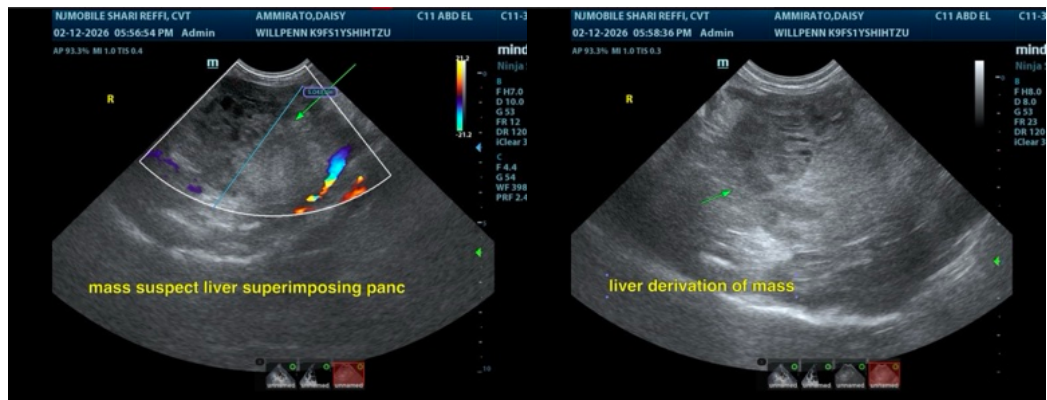
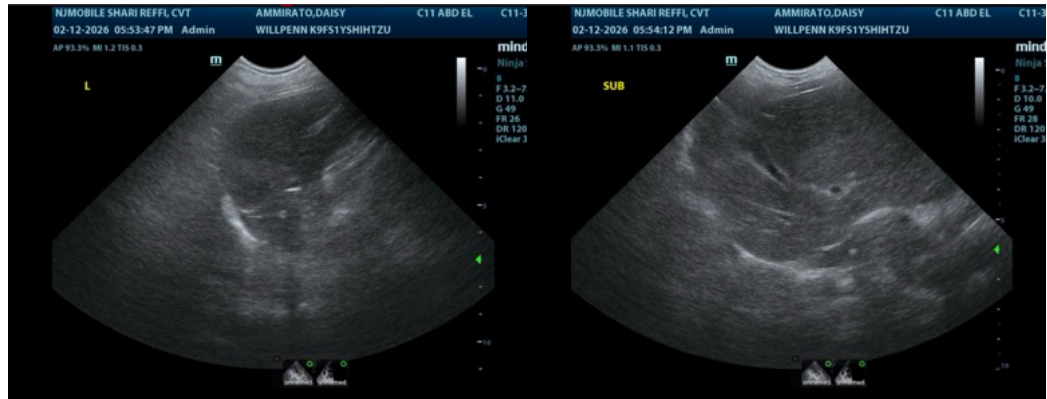
Dr. Bouzaout

INVOICE

71562

DATE

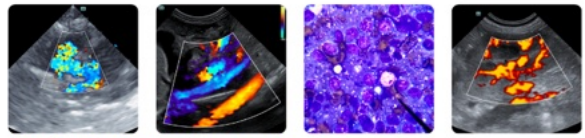
2/12/26



The information and recommendations provided are based on the images presented by the referring veterinarian/sonographer. No evaluation can be communicated regarding pathology that was not visible in the image/video clips provided.

Thank you for this referral. If the clinical or image interpretation does not parallel your findings or if I can be of any further assistance please contact me.

Eric Lindquist, DMV, DABVP, Cert. IVUSS, CEO of SonoPath.com



PATIENT

Info@SonoPath.com

Daisy Ammirato

SPECIES

Canine

BREED

Shih Tzu

SEX

Spayed female

AGE

11 years

WEIGHT

15 lbs

INTERPRETED BY

Eric Lindquist, DMV,
DABVP, Cert. IVUSS,
CEO of SonoPath.com

**IMAGING
PERFORMED BY**

Shari Reffi, CVT

HOSPITAL NAME

William Penn VH

REFERRING VET

Dr. Bouzaout

INVOICE

71562

DATE

2/12/26