



PATIENT

Happy Lee

SPECIES

Canine

BREED

Chihuahua

SEX

Spayed female

AGE

12 years

WEIGHT

4 lbs

INTERPRETED BY

Eric Lindquist, DMV,
DABVP, Cert. IVUSS,
CEO of SonoPath.com

IMAGING PERFORMED BY

Eric Lindquist, DMV,
DABVP, Cert. IVUSS,
CEO of SonoPath.com

HOSPITAL NAME

Butler VH

REFERRING VET

Dr. Sereda

INVOICE

71435

DATE

2/10/26

PRESENTING CLINICAL SIGNS

Recheck cardiac disease. Grade IV parasystolic heart murmur. Regularly irregular rhythm.
UA WBC 4-10, Trace protein, urine specific gravity 1.052
Lab: Platelets 581, neutrophils 2000, cholesterol 81, total T4 0.9

ULTRASONOGRAPHIC EXAMINATION OF THE HEART

The echocardiogram in this patient demonstrated enlarged **left atrial** size based on 3 different LA measurement methods. Chamber volumes and echogenicity were normal. The cranial and caudal **mitral** valve leaflets presented vegetative thickening consistent with endocardiosis. Prolapse of the anterior mitral valve leaflet was noted. Doppler indicated measurable insufficiency. Complete filling of the left atrium was noted on color flow assessment. The **left ventricle** presented normal thicknesses with linear contour and was not dilated nor restricted. The **myocardium** presented normal echogenicity without subjective evidence of significant fibrotic or ischemic disease. **Contractility** of the ventricular walls was adequate and in normal range for this patient evidenced by the fractional shortening measurement and subjective evaluation of the different regions of the myocardium. The **left ventricular outflow** tract demonstrated normal laminar flow and subjective structural integrity. The **right atrium** and auricle revealed normal size, structure and content. No evidence of masses was noted or chamber overload. **Tricuspid** valvular assessment demonstrated adequate linear morphology. The **right ventricle** was of normal size (1/3 diameter of LV), chordae structure, myocardial echogenicity and thickness. **Pulmonic** tract assessment revealed normal valve structure, laminar flow, and diameter (approx. 1:1 pa/ao ratio). No visible **pericardial** or free pleura fluid was noted. No echographically detectable evidence of infiltrative disease was visible. The cranial **mediastinum and pericardial regions** were free of masses in the visible window. The hepatic veins were dilated.

CANINE CARDIAC PARAMETERS	MR VMAX (m/s)	TR VMAX (m/s)	LA/AO	LA/AO (Heart Base)	FS (%)	EF (%)	EPSS (cm)
NORMAL PARAMETER	4.5-5.5	<2.7	1.3	<1.6	28-40	40-100	<0.6
PATIENT	6.11		1.5	1.9	60	91	0.1
CANINE CARDIAC PARAMETERS	HR (BPM)	AV VMAX (m/s)	PV MAX (m/s)	BODY WEIGHT (kg)	LA 2D short axis Base view (cm)	LVIDd Avg; 2D and m- mode short axis (cm)	LVIDs Avg; 2D and m- mode short axis (cm)
NORMAL PARAMETER	50-100	0.7-1.7	0.7-1.6	BELOW	BELOW	BELOW	BELOW
PATIENT	158	1.4	0.72		2.8	2.34	

ULTRASONOGRAPHIC FINDINGS

- Stage B2 valvular disease.



PATIENT

Happy Lee

SPECIES

Canine

BREED

Chihuahua

SEX

Spayed female

AGE

12 years

WEIGHT

4 lbs

INTERPRETED BY

Eric Lindquist, DMV, DABVP, Cert. IVUSS, CEO of SonoPath.com

IMAGING PERFORMED BY

Eric Lindquist, DMV, DABVP, Cert. IVUSS, CEO of SonoPath.com

HOSPITAL NAME

Butler VH

REFERRING VET

Dr. Sereda

INVOICE

71435

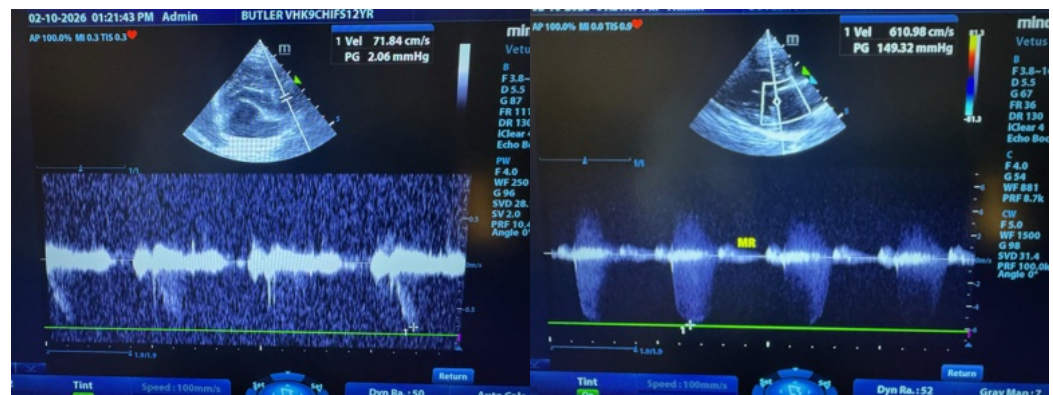
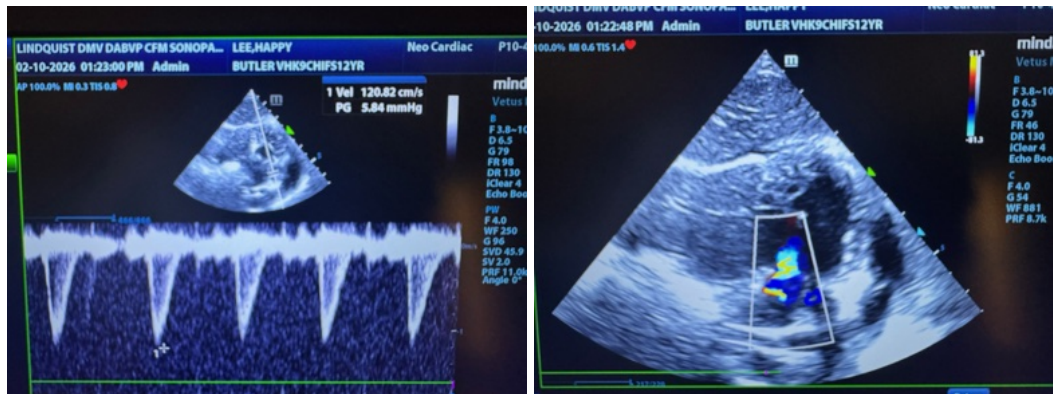
DATE

2/10/26

INTERPRETATION OF THE FINDINGS & FURTHER RECOMMENDATIONS

Left-sided volumes have increased compared to the prior sonogram. Mitral valve prolapse is definitive, which is indicative of ruptured chordae tendineae. The patient appears stable at this time. I recommend initiating Pimobendan at 0.3 mg/kg b.i.d.

The heart has minor volume overload and is working to compensate for the valvular insufficiency. Target respiratory rate is < 20 resp/minute after therapy. After initiating or adjusting therapy, I recommend recheck on the clinical exam, BUN, Creatinine, USG, Chest radiographs & Blood pressure in 5-7 days. Recheck echo in 3-6 months, earlier if clinical decompensation is occurring. Minor anesthetic risk for a brief procedure at this time. Repeat preanesthetic echo is ideal if anesthesia is eventually necessary. A suggested anesthetic combination would involve Torbutrol premed, propofol induction, Isoflurane maintenance or equivalent protocol.





PATIENT

Happy Lee

SPECIES

Canine

BREED

Chihuahua

SEX

Spayed female

AGE

12 years

WEIGHT

4 lbs

INTERPRETED BY

Eric Lindquist, DMV,
 DABVP, Cert. IVUSS,
 CEO of SonoPath.com

IMAGING PERFORMED BY

Eric Lindquist, DMV,
 DABVP, Cert. IVUSS,
 CEO of SonoPath.com

HOSPITAL NAME

Butler VH

REFERRING VET

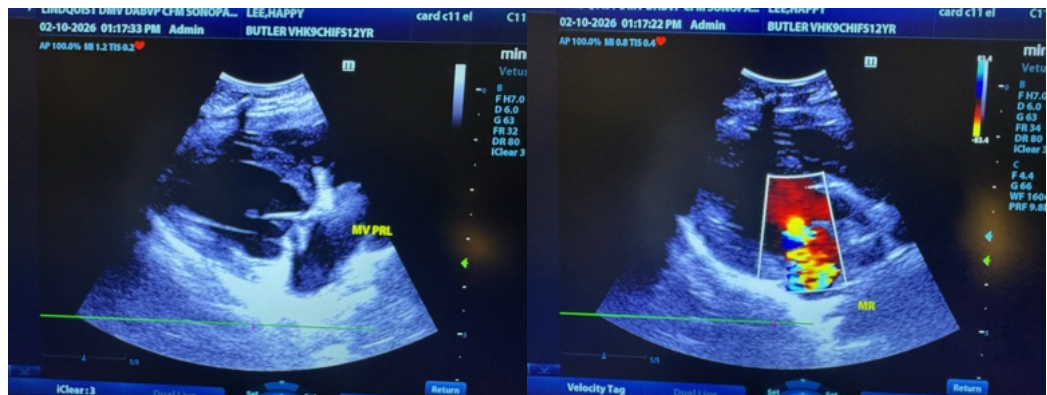
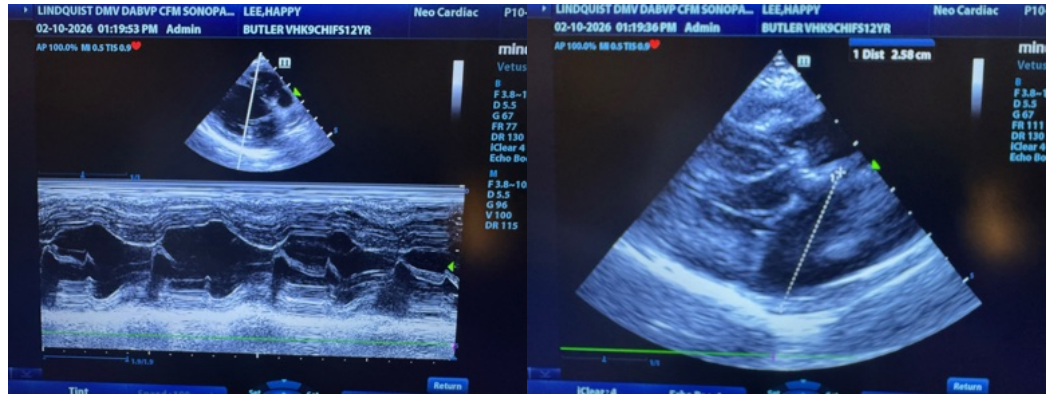
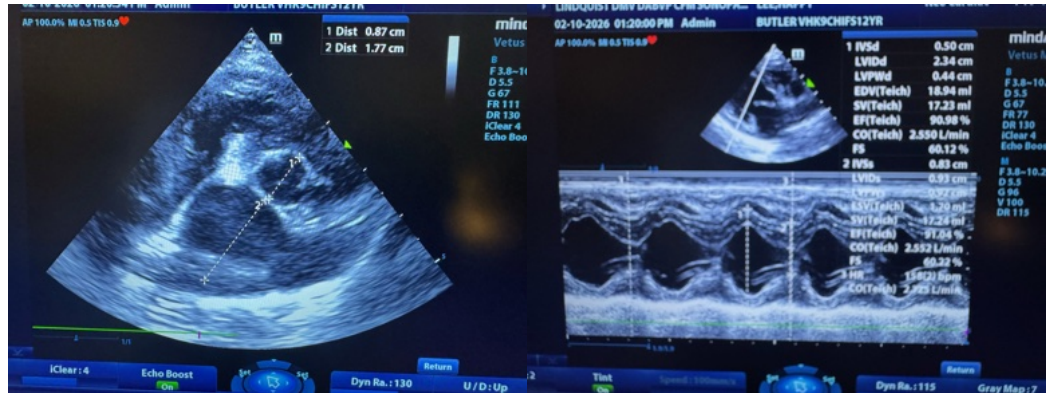
Dr. Sereda

INVOICE

71435

DATE

2/10/26





PATIENT

Happy Lee

SPECIES

Canine

BREED

Chihuahua

SEX

Spayed female

AGE

12 years

WEIGHT

4 lbs

INTERPRETED BY

Eric Lindquist, DMV,
DABVP, Cert. IVUSS,
CEO of SonoPath.com

IMAGING PERFORMED BY

Eric Lindquist, DMV,
DABVP, Cert. IVUSS,
CEO of SonoPath.com

HOSPITAL NAME

Butler VH

REFERRING VET

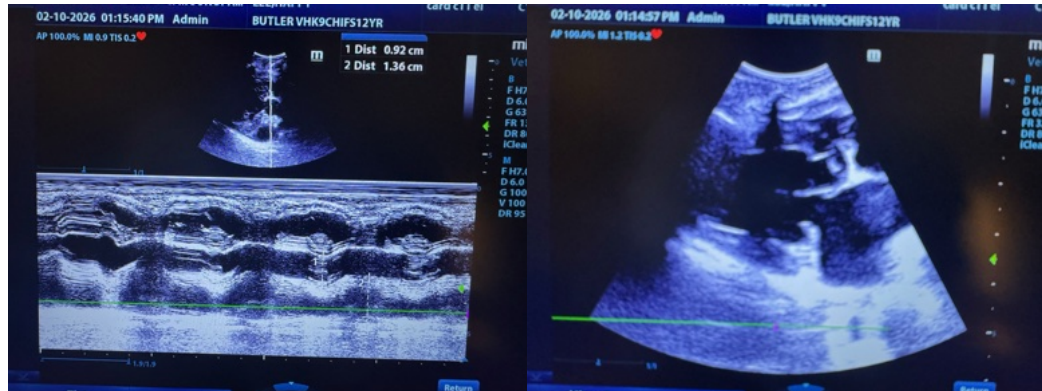
Dr. Sereda

INVOICE

71435

DATE

2/10/26



The information and recommendations provided are based on the images presented by the referring veterinarian/sonographer. No evaluation can be communicated regarding pathology that was not visible in the image/video clips provided.

Thank you for this referral. If the clinical or image interpretation does not parallel your findings or if I can be of any further assistance please contact me.

Eric Lindquist, DMV, DABVP, Cert. IVUSS, CEO of SonoPath.com

Info@SonoPath.com