



PATIENT

Soleil Eckler

SPECIES

Feline

BREED

Domestic Shorthair

SEX

Spayed female

AGE

6 years

WEIGHT

9.8 lbs

INTERPRETED BY

Eric Lindquist, DMV,
DABVP, Cert. IVUSS,
CEO of SonoPath.com

IMAGING PERFORMED BY

Eric Lindquist, DMV,
DABVP, Cert. IVUSS,
CEO of SonoPath.com

HOSPITAL NAME

Greenwood Lake AH

REFERRING VET

Dr. Price

INVOICE

69411

DATE

12/9/25

PRESENTING CLINICAL SIGNS

Non-clinical heart murmur.

ULTRASONOGRAPHIC EXAMINATION OF THE HEART

The echocardiogram in this patient demonstrated normal **left atrial** size based on 3 separate LA measurements. The cranial and caudal **mitral** valve leaflets presented normal linear structure and kinetics.. The **left ventricle** presented normal thicknesses with linear contour and was not dilated nor restricted. The **myocardium** presented normal echogenicity without subjective evidence of significant fibrotic or ischemic disease. **Contractility** of the ventricular walls was adequate and in normal range for this patient evidenced by the fractional shortening measurement and subjective evaluation of the different regions and angles of the myocardium. The **left ventricular outflow** tract demonstrated normal laminar flow and subjective structural integrity. The **right atrium** and auricle revealed normal size, structure and content. No evidence of masses was noted or chamber overload. **Tricuspid** valvular assessment demonstrated adequate linear morphology and kinetics. The **right ventricle** was of normal size (1/3 diameter of LV), chordae structure, myocardial echogenicity and thickness. **Pulmonic** tract assessment revealed normal valve structure, laminar flow, and diameter (approx.1:1 pa/ao ratio). No visible **pericardial** or free pleura fluid was noted or extra cardiac pathology in the visible planes. The cranial **mediastinum and pericardial regions** were free of masses in the visible window.

FELINE CARDIAC PARAMETERS	BODY WEIGHT	HR (BPM)	IVSd (cm)	LVIDd (cm)	LVWd (cm)	FS (%)	EF (%)
NORMAL PARAMETER	-----	150-240	0.3-0.6	1.0-2.1	0.25-0.6	35-67	80-100
PATIENT	9.8 lbs	180	0.55	1.41	0.54	62	93
FELINE CARDIAC PARAMETERS	LA/AO (M-mode)	LA/AO HEART BASE (Sisson)	LAD LA MAX 4 Chamber		LVOT VEL. (m/s)	RVOT VEL. (m/s)	IVRT (m/)
NORMAL PARAMETER	<1.5	1.6	0.7-1.7		<1.6	<1.3	40-60
PATIENT	1.1	1.3	1.2			0.88	NM
Adapted from June Boon, Veterinary Echocardiography, 1998 Sisson D et al. JVIM 1991; 5: 232, Jacobs et al. Am J Vet Res 1985; 46:1705							

ULTRASONOGRAPHIC FINDINGS

- Normal echocardiogram.
- Idiopathic flow murmur.



PATIENT

Soleil Eckler

SPECIES

Feline

BREED

Domestic Shorthair

SEX

Spayed female

AGE

6 years

WEIGHT

9.8 lbs

INTERPRETED BY

Eric Lindquist, DMV,
 DABVP, Cert. IVUSS,
 CEO of SonoPath.com

IMAGING PERFORMED BY

Eric Lindquist, DMV,
 DABVP, Cert. IVUSS,
 CEO of SonoPath.com

HOSPITAL NAME

Greenwood Lake AH

REFERRING VET

Dr. Price

INVOICE

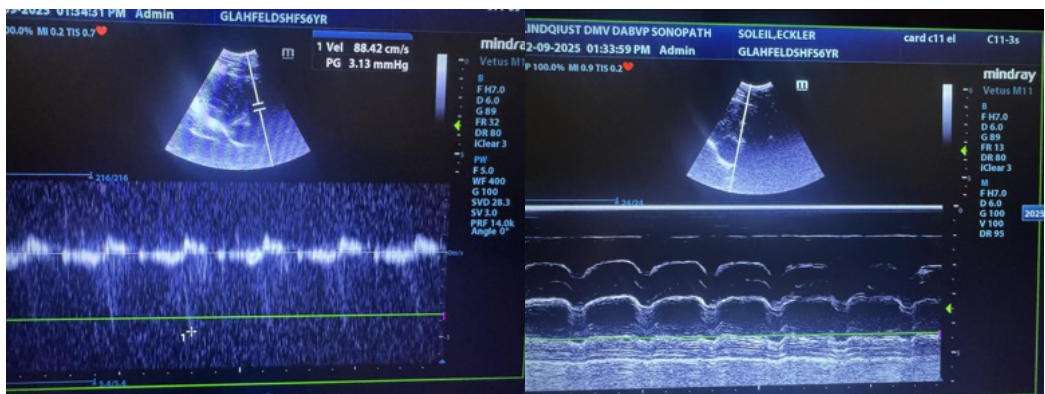
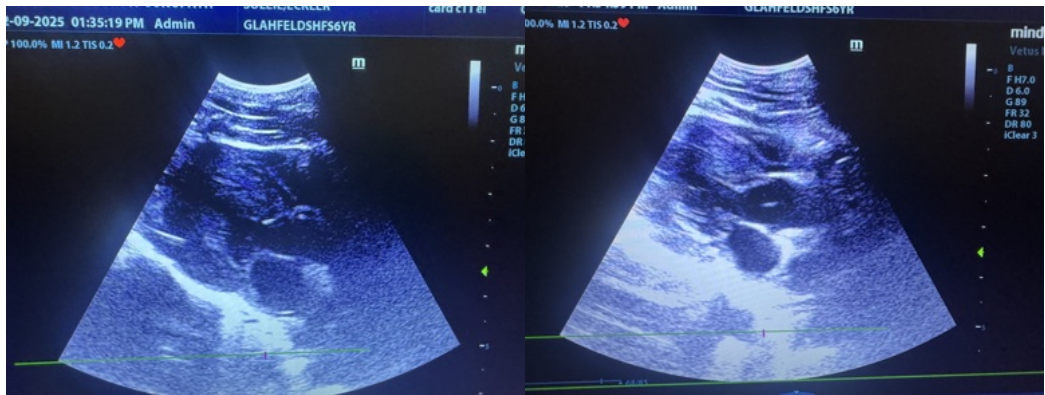
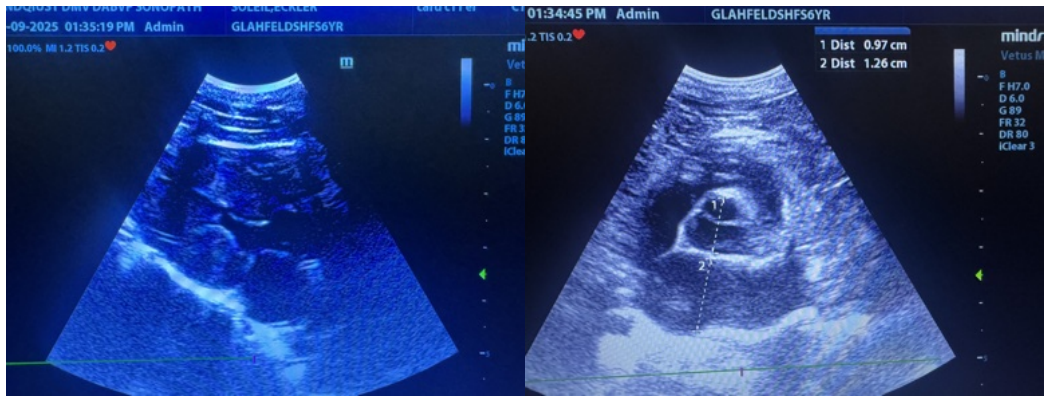
69411

DATE

12/9/25

INTERPRETATION OF THE FINDINGS & FURTHER RECOMMENDATIONS

Benign flow murmurs are common in cats. This may be owing to volume shifts, tachycardia, benign (DRVOTO) right ventricular outflow changes, trivial turbulence in any of the valvular apparatuses, or possibly excessive stethoscope pressure against the chest according to a recent study. These are physiologically benign and unrelated to specific pathology.





PATIENT

Soleil Eckler

SPECIES

Feline

BREED

Domestic Shorthair

SEX

Spayed female

AGE

6 years

WEIGHT

9.8 lbs

INTERPRETED BY

Eric Lindquist, DMV,
 DABVP, Cert. IVUSS,
 CEO of SonoPath.com

IMAGING PERFORMED BY

Eric Lindquist, DMV,
 DABVP, Cert. IVUSS,
 CEO of SonoPath.com

HOSPITAL NAME

Greenwood Lake AH

REFERRING VET

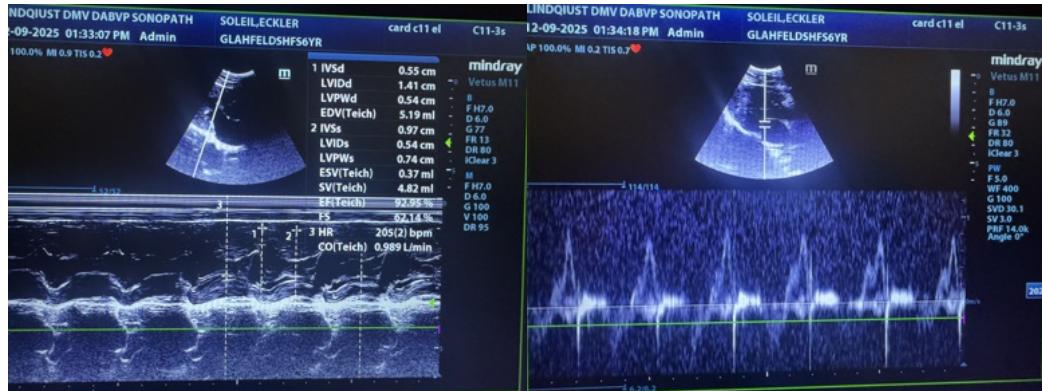Dr. Price

INVOICE

69411

DATE

12/9/25



The information and recommendations provided are based on the images presented by the referring veterinarian/sonographer. No evaluation can be communicated regarding pathology that was not visible in the image/video clips provided.

Thank you for this referral. If the clinical or image interpretation does not parallel your findings or if I can be of any further assistance please contact me.

Eric Lindquist, DMV, DABVP, Cert. IVUSS, CEO of SonoPath.com

Info@SonoPath.com