



PATIENT

Saige Dulude

SPECIES

Canine

BREED

Doberman

SEX

Spayed female

AGE

-

WEIGHT

-

PRESENTING CLINICAL SIGNS

History: Had 3 Doxorubicin Tx, just checking heart

ULTRASONOGRAPHIC EXAMINATION OF THE HEART

The echocardiogram in this patient demonstrated normal **left atrial** size based on 3 separate methods of LA evaluation. The cranial and caudal **mitral** valve leaflets presented normal linear structure, extension in systole, and union in diastole with normal kinesis. The **left ventricle** presented thicknesses with linear contour and was not dilated nor restricted. The **myocardium** presented normal echogenicity without subjective evidence of significant fibrotic or ischemic disease. **Contractility** of the ventricular walls was adequate and in normal range for this patient evidenced by the fractional shortening measurement and subjective evaluation of the different regions of the myocardium. The **left ventricular outflow** tract demonstrated normal laminar flow and subjective structural integrity. The **right atrium** and auricle revealed normal size, structure and content. No evidence of masses was noted. **Tricuspid** insufficiency was persistent and measured 2.4 m/sec. The **right ventricle** was of normal size (1/3 diameter of LV), chordae structure, myocardial echogenicity and thickness. **Pulmonary outflow** tract assessment revealed normal valve structure, laminar flow, and diameter (approx. 1:1 pa/ao ratio). No visible **pericardial** or free pleura fluid was noted. The cranial **mediastinum and pericardial and extra-cardiac regions** were free of masses in the visible window.

INTERPRETED BY

Eric Lindquist, DMV
 DABVP, Cert. IVUSS

IMAGING PERFORMED BY

Rebecca Hamilton

HOSPITAL NAME

The Gentle Vet

REFERRING VET

Dr. Dulude

INVOICE

69439

DATE

12/9/25

CANINE CARDIAC PARAMETERS	MR VMAX (m/s)	TR VMAX (m/s)	LA/AO	LA/AO (Heart Base)	FS (%)	EF (%)	EPSS (cm)
NORMAL PARAMETER	4.5-5.5	<2.7	1.3	<1.6	28-40	40-100	<0.6
PATIENT		2.4	1.0	1.1	40	90	0.2
CANINE CARDIAC PARAMETERS	HR (BPM)	AV VMAX (m/s)	PV MAX (m/s)	BODY WEIGHT (kg)	LA 2D short axis Base view (cm)	LVIDd Avg; 2D and m-mode short axis (cm)	LVIDs Avg; 2D and m-mode short axis (cm)
NORMAL PARAMETER	50-100	0.7-1.7	0.7-1.6	BELOW	BELOW	BELOW	BELOW
PATIENT	130	1.9	0.91		3.8	3.7	

ULTRASONOGRAPHIC FINDINGS

Normal echocardiogram with minor tricuspid insufficiency, essentially a normal variant.

INTERPRETATION OF THE FINDINGS & FURTHER RECOMMENDATIONS

There was no evidence of pathology. There was no evidence of DCM.



PATIENT

Saige Dulude

SPECIES

Canine

BREED

Doberman

SEX

Spayed female

AGE

-

WEIGHT

-

INTERPRETED BY

Eric Lindquist, DMV
 DABVP, Cert. IVUSS

IMAGING PERFORMED BY

Rebecca Hamilton

HOSPITAL NAME

The Gentle Vet

REFERRING VET

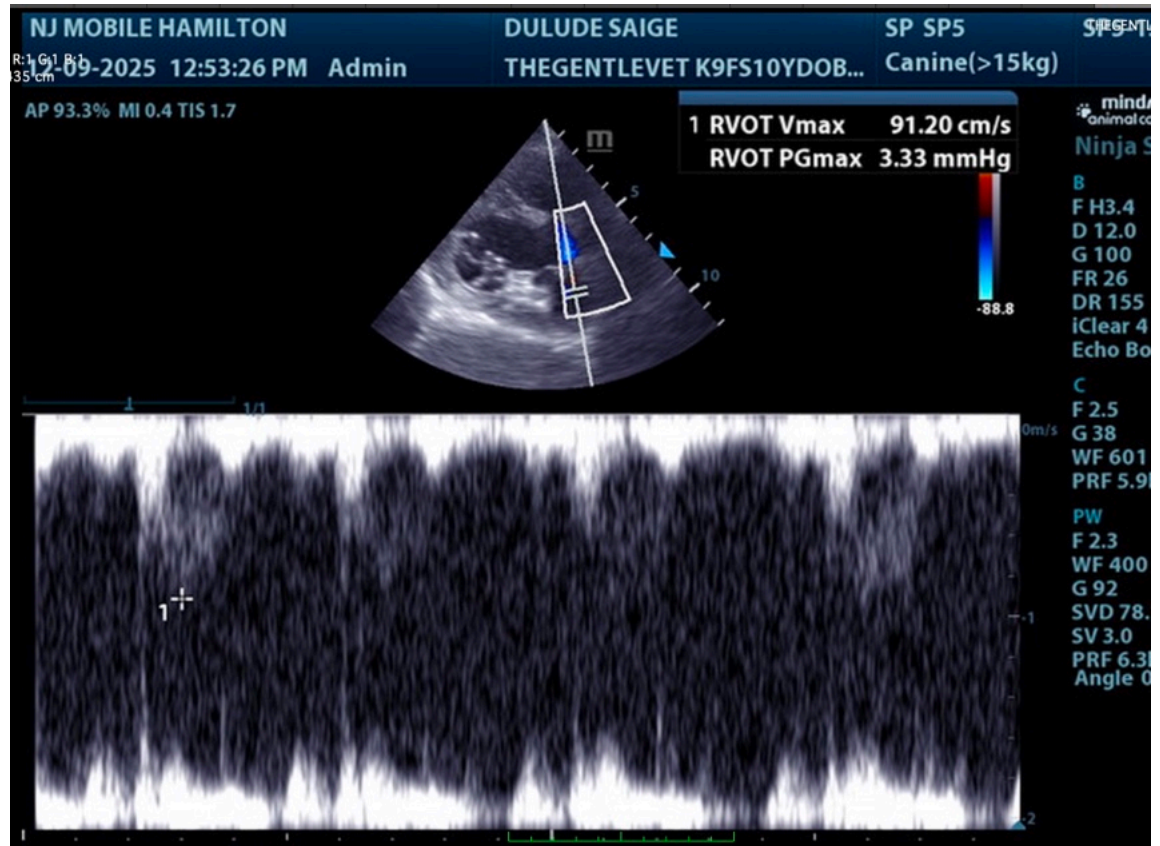
Dr. Dulude

INVOICE

69439

DATE

12/9/25





PATIENT

Saige Dulude

SPECIES

Canine

BREED

Doberman

SEX

Spayed female

AGE

-

WEIGHT

-

INTERPRETED BY

Eric Lindquist, DMV
 DABVP, Cert. IVUSS

IMAGING PERFORMED BY

Rebecca Hamilton

HOSPITAL NAME

The Gentle Vet

REFERRING VET

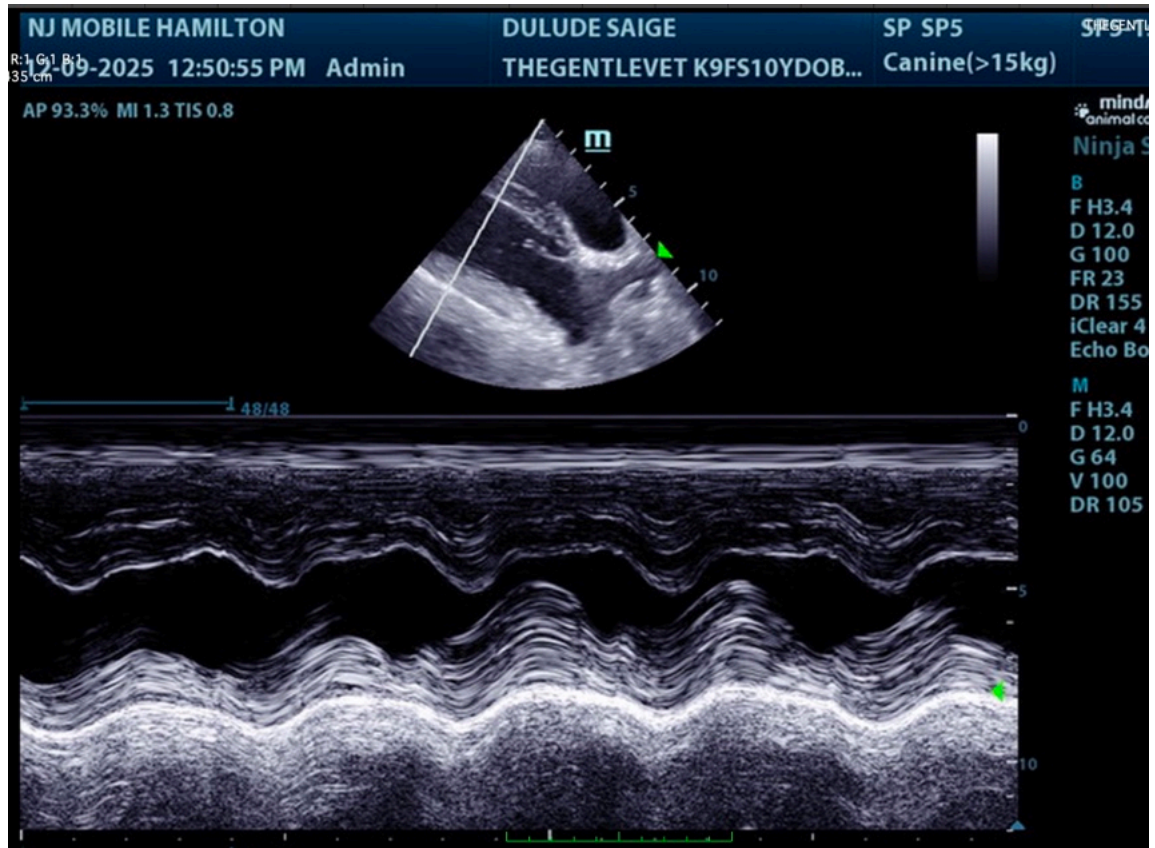
Dr. Dulude

INVOICE

69439

DATE

12/9/25





PATIENT

Saige Dulude

SPECIES

Canine

BREED

Doberman

SEX

Spayed female

AGE

-

WEIGHT

-

INTERPRETED BY

Eric Lindquist, DMV
 DABVP, Cert. IVUS

IMAGING PERFORMED BY

Rebecca Hamilton

HOSPITAL NAME

The Gentle Vet

REFERRING VET

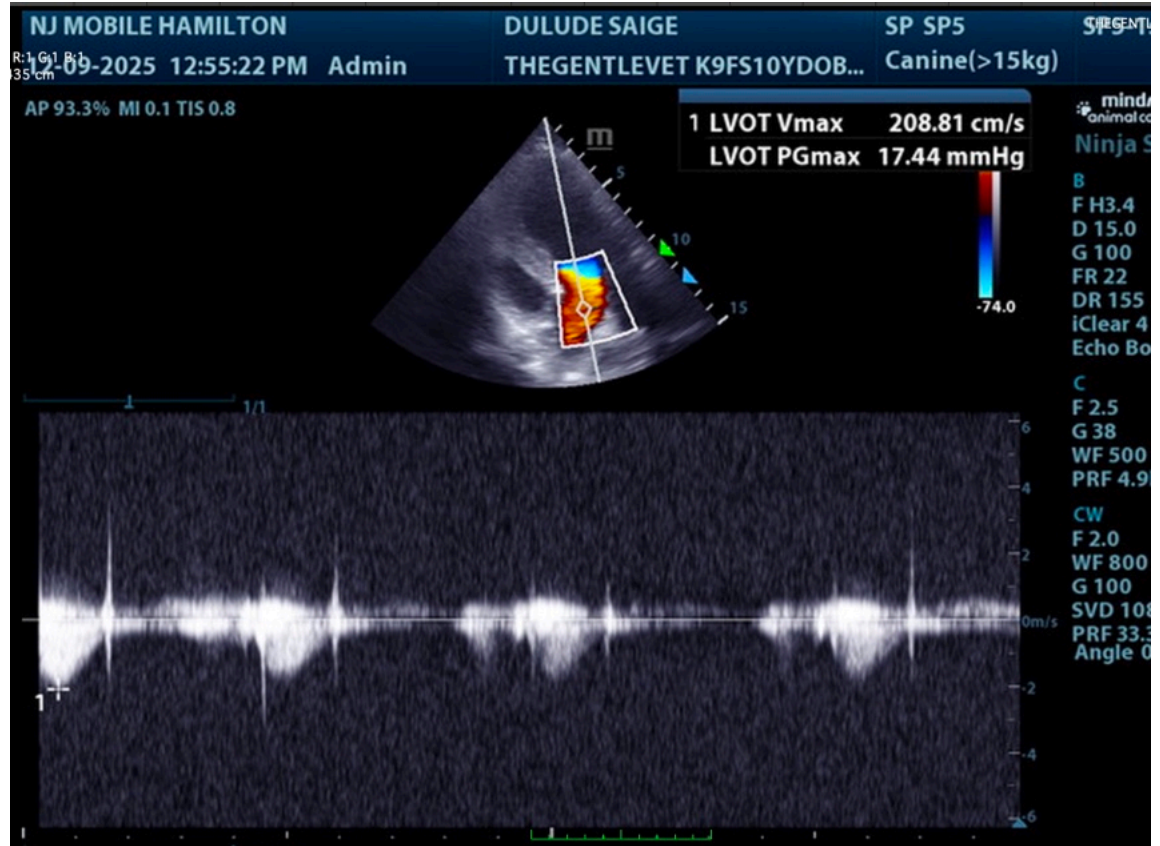
Dr. Dulude

INVOICE

69439

DATE

12/9/25





PATIENT

Saige Dulude

SPECIES

Canine

BREED

Doberman

SEX

Spayed female

AGE

-

WEIGHT

-

INTERPRETED BY

Eric Lindquist, DMV
 DABVP, Cert. IVUSS

IMAGING PERFORMED BY

Rebecca Hamilton

HOSPITAL NAME

The Gentle Vet

REFERRING VET

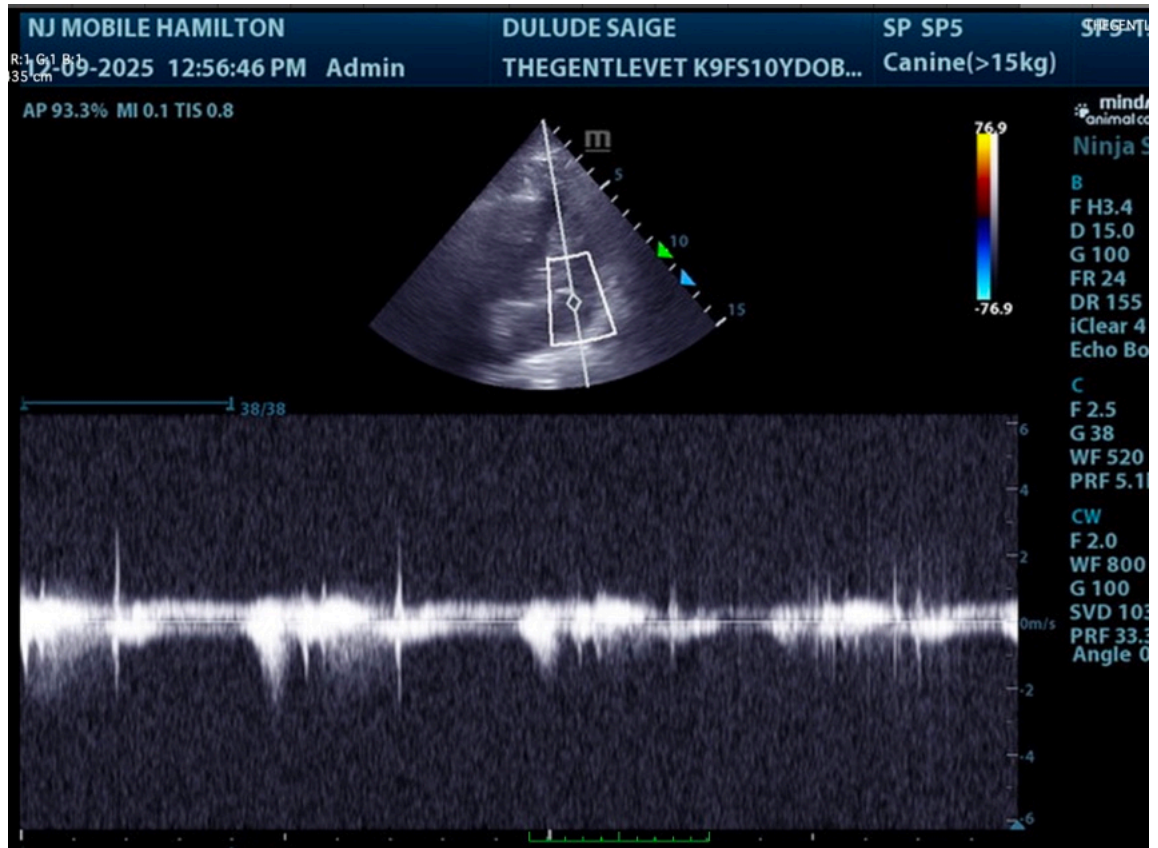
Dr. Dulude

INVOICE

69439

DATE

12/9/25





PATIENT

Saige Dulude

SPECIES

Canine

BREED

Doberman

SEX

Spayed female

AGE

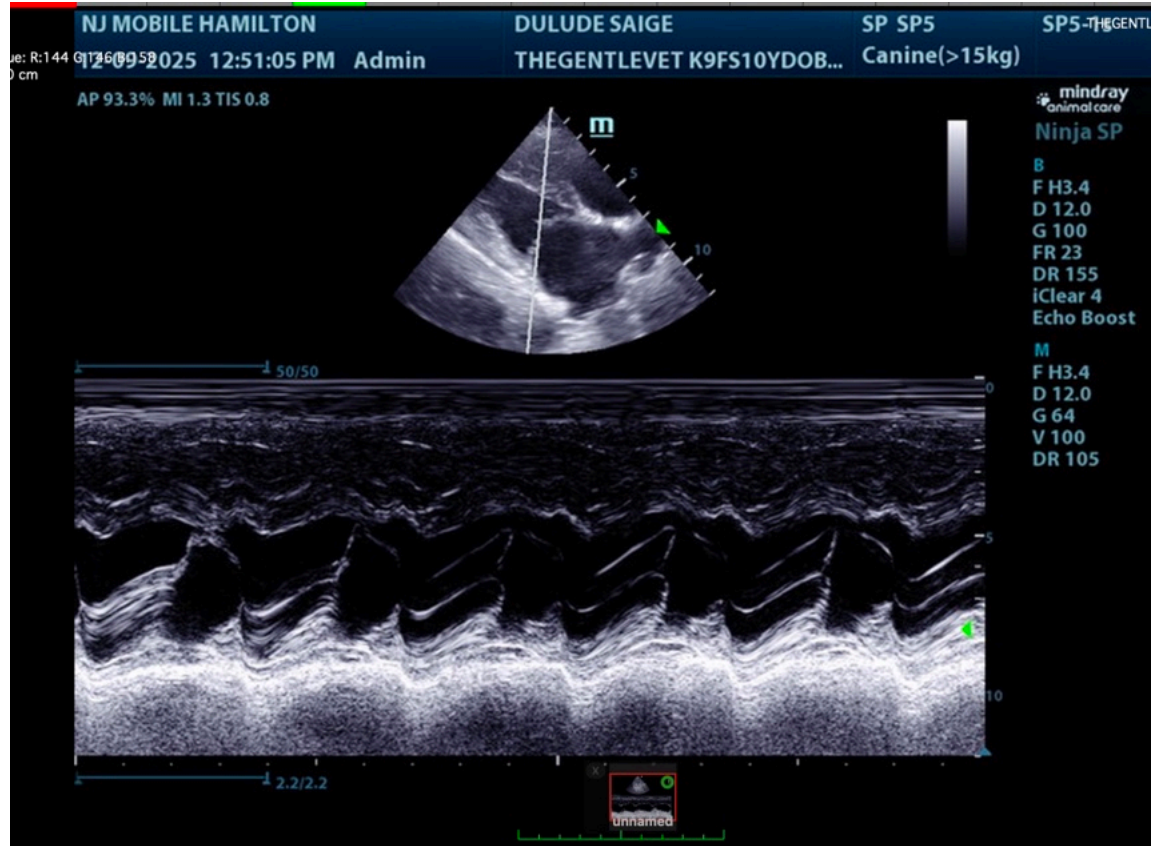
-

WEIGHT

-

INTERPRETED BY

Eric Lindquist, DMV
 DABVP, Cert. IVUSS



IMAGING PERFORMED BY

Rebecca Hamilton

HOSPITAL NAME

The Gentle Vet

REFERRING VET

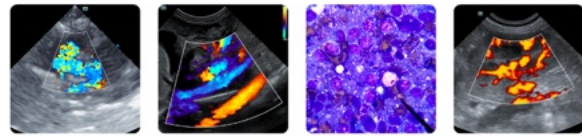
Dr. Dulude

INVOICE

69439

DATE

12/9/25



PATIENT

Saige Dulude

SPECIES

Canine

BREED

Doberman

SEX

Spayed female

AGE

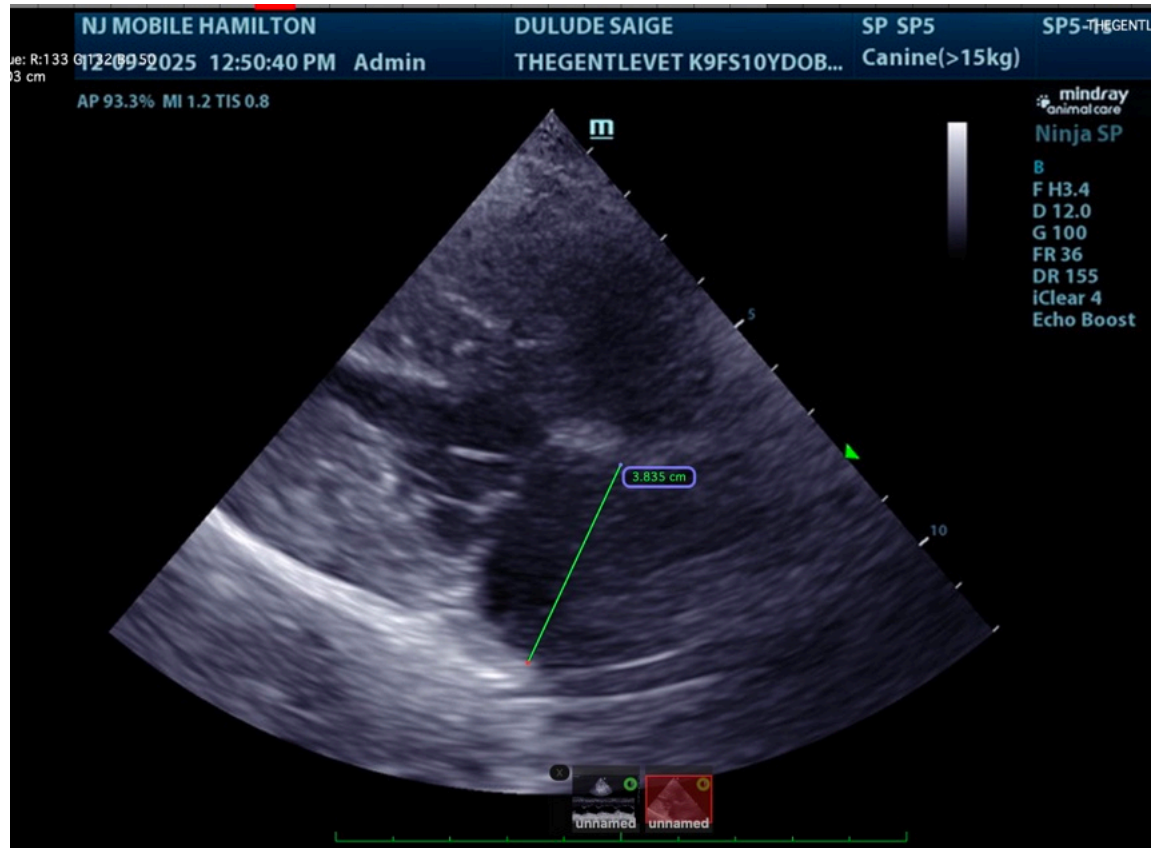
-

WEIGHT

-

INTERPRETED BY

Eric Lindquist, DMV
DABVP, Cert. IVUSS



IMAGING PERFORMED BY

Rebecca Hamilton

HOSPITAL NAME

The Gentle Vet

REFERRING VET

Dr. Dulude

INVOICE

69439

DATE

12/9/25

The information and recommendations provided are based on the images presented by the referring veterinarian/sonographer. No evaluation can be communicated regarding pathology that was not visible in the image/video clips provided.

Thank you for this referral. If the clinical or image interpretation does not parallel your findings or if I can be of any further assistance please contact me.

Eric Lindquist, DMV, DABVP, Cert. IVUSS, CEO of SonoPath.com

info@SonoPath.com