



## PATIENT

Lily Mullis

## SPECIES

Feline

## BREED

Domestic Shorthair

## SEX

Spayed female

## AGE

9 years

## WEIGHT

6 lbs

## INTERPRETED BY

Eric Lindquist, DMV,  
DABVP, Cert. IVUSS,  
CEO of SonoPath.com

## IMAGING PERFORMED BY

Eric Lindquist, DMV,  
DABVP, Cert. IVUSS,  
CEO of SonoPath.com

## HOSPITAL NAME

Franklin Lakes AH

## REFERRING VET

Dr. VH

## INVOICE

69416

## DATE

12/9/25

## PRESENTING CLINICAL SIGNS

Weight loss, suspected mass, generalized muscle wasting.

Albumin 2.2, globulin 7.1, glucose 311, WBC 19.1

## ULTRASONOGRAPHIC EXAMINATION OF THE ABDOMEN

### *Urinary System*

The **urinary bladder**, trigone, and pelvic urethra presented normal thicknesses and normal tone. The ureters were not visible which is normal. No uroliths or sediment were visualized and anechoic urine was present. No evidence of inflammatory or neoplastic changes was noted. Ureteral papillae were normal.

The **kidneys** revealed normal size and structure, corticomedullary definition and ratio for this age. The cortices presented largely uniform texture with normal echogenic relationship to liver and spleen. Medullary structure differed distinctly from the cortex and no evidence of pelvic dilation was present. The capsules were acceptably uniform without significant irregularities. The left kidney measured 4.3 cm. The right kidney measured 4.3 cm.

### *Adrenal Glands*

Both **adrenal glands** were visualized and recognized as having normal shape, size, position and echogenicity for this breed. The phrenic vasculature, glandular echogenicity and detail were unremarkable. Capsule, cortex, and medullary definition were normal for this age patient. The left adrenal gland measured 0.4 cm.

### *Spleen, Pancreas and Liver*

An undifferentiated parenchymal and cystic mass was noted in the cranial abdomen occupying the **spleen, pancreas and caudal liver** in the left and right medial liver as well as the portal hilus. The cranial liver and gallbladder were unremarkable. Regional lymph nodes were also enlarged.

### *Gastrointestinal*

The upper **gastrointestinal tract** was enveloped in the undifferentiated pathology. The distal small intestine and colon were unremarkable.

## ULTRASONOGRAPHIC FINDINGS

- Undifferentiated coalescing mass involving multiple organs in the cranial abdomen.
- Regional lymph nodes.



**PATIENT**

Lily Mullis

**SPECIES**

Feline

**BREED**

Domestic Shorthair

**SEX**

Spayed female

**AGE**

9 years

**WEIGHT**

6 lbs

**INTERPRETED BY**

Eric Lindquist, DMV,  
 DABVP, Cert. IVUSS,  
 CEO of SonoPath.com

**IMAGING PERFORMED BY**

Eric Lindquist, DMV,  
 DABVP, Cert. IVUSS,  
 CEO of SonoPath.com

**HOSPITAL NAME**

Franklin Lakes AH

**REFERRING VET**

Dr. VH

**INVOICE**

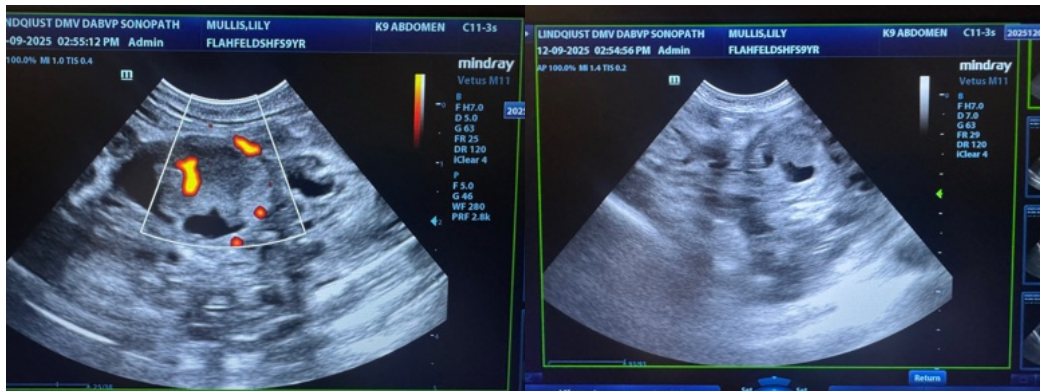
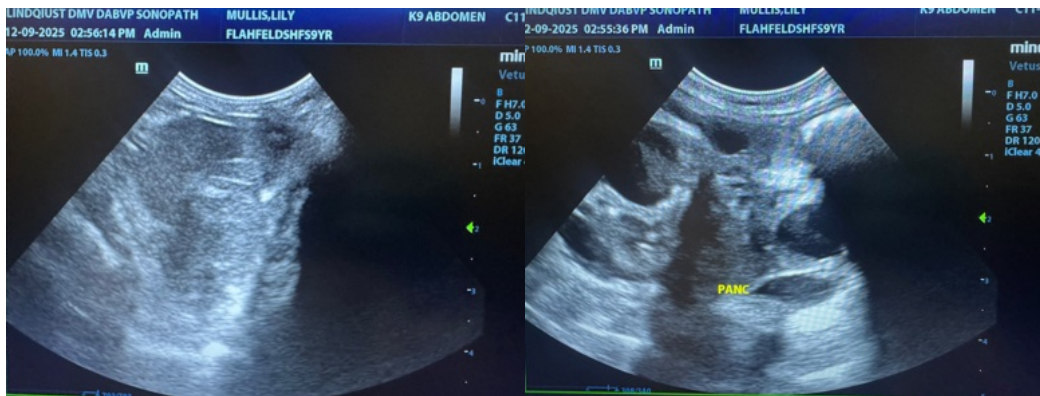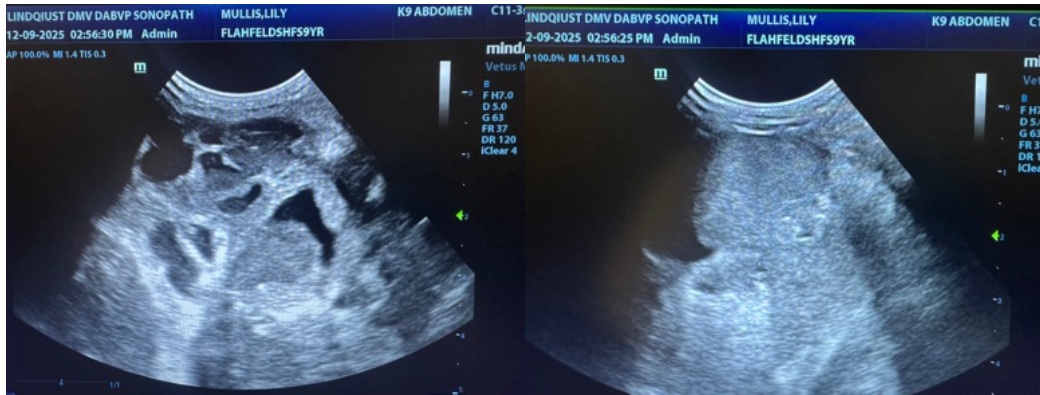
69416

**DATE**

12/9/25

**INTERPRETATION OF THE FINDINGS & FURTHER RECOMMENDATIONS**

FNA for eventual chemoreduction could be considered for further definition. This is not resectable. Undifferentiated neoplasia, carcinoma or sarcoma is suspected.





**PATIENT**

Lily Mullis

**SPECIES**

Feline

**BREED**

Domestic Shorthair

**SEX**

Spayed female

**AGE**

9 years

**WEIGHT**

6 lbs

**INTERPRETED BY**

Eric Lindquist, DMV,  
 DABVP, Cert. IVUSS,  
 CEO of SonoPath.com

**IMAGING PERFORMED BY**

Eric Lindquist, DMV,  
 DABVP, Cert. IVUSS,  
 CEO of SonoPath.com

**HOSPITAL NAME**

Franklin Lakes AH

**REFERRING VET**

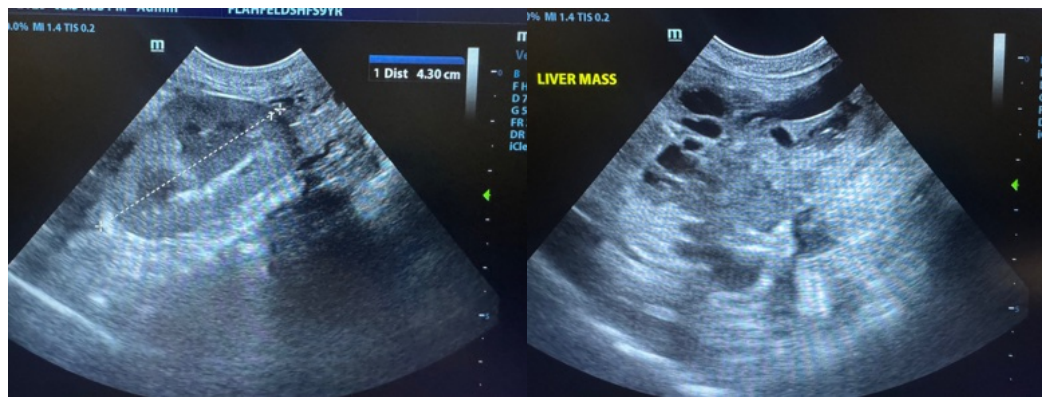
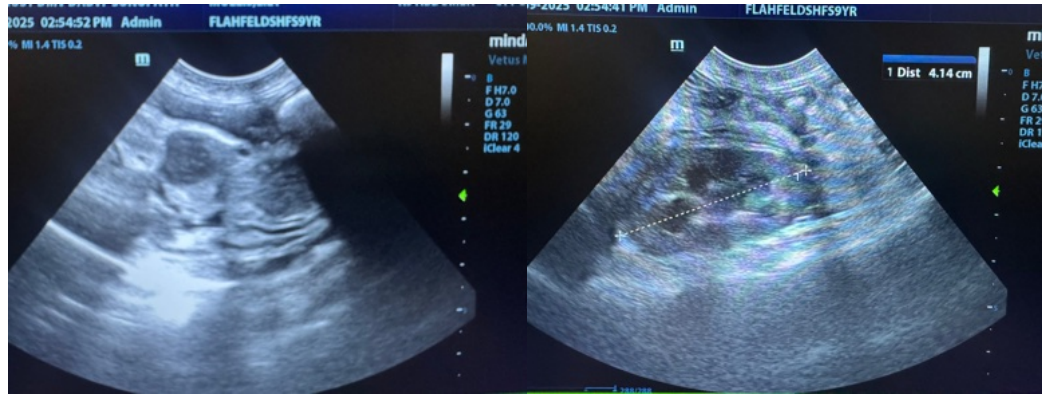
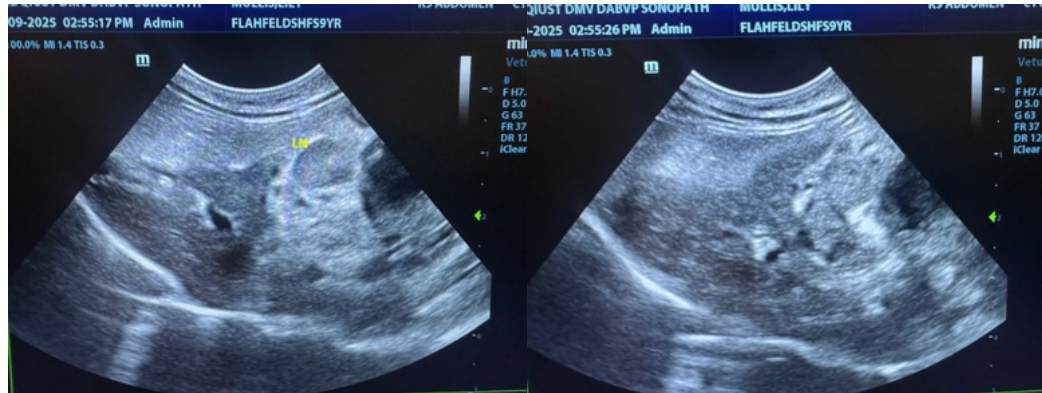
Dr. VH

**INVOICE**

69416

**DATE**

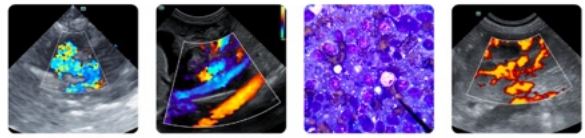
12/9/25



The information and recommendations provided are based on the images presented by the referring veterinarian/sonographer. No evaluation can be communicated regarding pathology that was not visible in the image/video clips provided.

Thank you for this referral. If the clinical or image interpretation does not parallel your findings or if I can be of any further assistance please contact me.

Eric Lindquist, DMV, DABVP, Cert. IVUSS, CEO of SonoPath.com



**PATIENT**

Info@SonoPath.com

Lily Mullis

**SPECIES**

Feline

**BREED**

Domestic Shorthair

**SEX**

Spayed female

**AGE**

9 years

**WEIGHT**

6 lbs

**INTERPRETED BY**

Eric Lindquist, DMV,  
DABVP, Cert. IVUSS,  
CEO of SonoPath.com

**IMAGING  
PERFORMED BY**

Eric Lindquist, DMV,  
DABVP, Cert. IVUSS,  
CEO of SonoPath.com

**HOSPITAL NAME**

Franklin Lakes AH

**REFERRING VET**

Dr. VH

**INVOICE**

69416

**DATE**

12/9/25