



## PATIENT

Princess Leia Olivia

## SPECIES

Canine

## BREED

Poodle Mix

## SEX

Spayed female

## AGE

6 ½ years

## WEIGHT

66.9 lbs

## INTERPRETED BY

Eric Lindquist, DMV,  
DABVP (CFM), Cert.  
IVUSS, CEO of  
SonoPath.com

## IMAGING PERFORMED BY

Vincent Ravancho

## HOSPITAL NAME

Montville AH

## REFERRING VET

Dr. Schubert

## INVOICE

69694

## DATE

12/30/25

## PRESENTING CLINICAL SIGNS

History: Systemic workup for Glaucoma Clinical Findings: Hx Glaucoma OU - Acute OD, Controlled OS w/Uveitis Current medications: Latanoprost, Dorzolamide, Timolol Sedated with Torb, Dexdorm

## ULTRASONOGRAPHIC EXAMINATION OF THE ABDOMEN

### Urinary System

The **urinary bladder**, trigone, and pelvic urethra presented normal thicknesses and normal tone. The ureters were not visible which is normal. No uroliths or sediment were visualized and anechoic urine was present. No evidence of inflammatory or neoplastic changes was noted. Ureteral papillae were normal.

The **kidneys** revealed normal size and structure, corticomedullary definition and ratio for this age. The cortices presented largely uniform texture with normal echogenic relationship to liver and spleen. Medullary structure differed distinctly from the cortex and no evidence of pelvic dilation was present. The capsules were acceptably uniform without significant irregularities. The left kidney measured 7.4 cm. The right kidney measured 5.7 cm.

### Adrenal Glands

Both **adrenal glands** were visualized and recognized as having normal shape, size, position and echogenicity for this breed. The phrenic vasculature, glandular echogenicity and detail were unremarkable. Capsule, cortex, and medullary definition were normal for this age patient. The left adrenal gland measured 2.14 x 0.47 cm at the cranial pole and 0.54 cm at the caudal pole. The right adrenal gland measured 1.2 x cm at the cranial pole and 0.6 cm at the caudal pole.

### Spleen

The **spleen** in this patient was mildly enlarged with uniform parenchyma and was folded upon itself caudally. This is a positional variant and is not pathological. There was no evidence of significant disease.

### Liver

The **liver** images submitted revealed subjectively normal liver size, contour, and structure. Parenchymal echogenicity was naturally coarse and hypoechoic to the spleen. Vascular and biliary tracts were of normal volume with no evidence of congestion. The gallbladder presented acceptably thin walls with primarily anechoic content. The cystic and common bile ducts were normal. No pathological hepatic lymphadenopathy was evident. No overt structural evidence of inflammatory, infiltrative or regenerative pathology was evident.



**PATIENT**

Princess Leia Olivia

**SPECIES**

Canine

**BREED**

Poodle Mix

**SEX**

Spayed female

**AGE**

6 ½ years

**WEIGHT**

66.9 lbs

**INTERPRETED BY**

Eric Lindquist, DMV,  
DABVP (CFM), Cert.  
IVUSS, CEO of  
SonoPath.com

**IMAGING PERFORMED BY**

Vincent Ravancho

**HOSPITAL NAME**

Montville AH

**REFERRING VET**

Dr. Schubert

**INVOICE**

69694

**DATE**

12/30/25

**Gastrointestinal**

Examination of the **gastrointestinal tract** revealed a stomach and intestine free of stasis, of normal wall thickness, acceptable curvilinear mural detail, and peristaltic activity. Small and large intestine demonstrated normal luminal chyme and stool consistency respectively. No obstructive or overt infiltrative disease was noted. No associated abnormal lymphatic activity was noted.

**Pancreas**

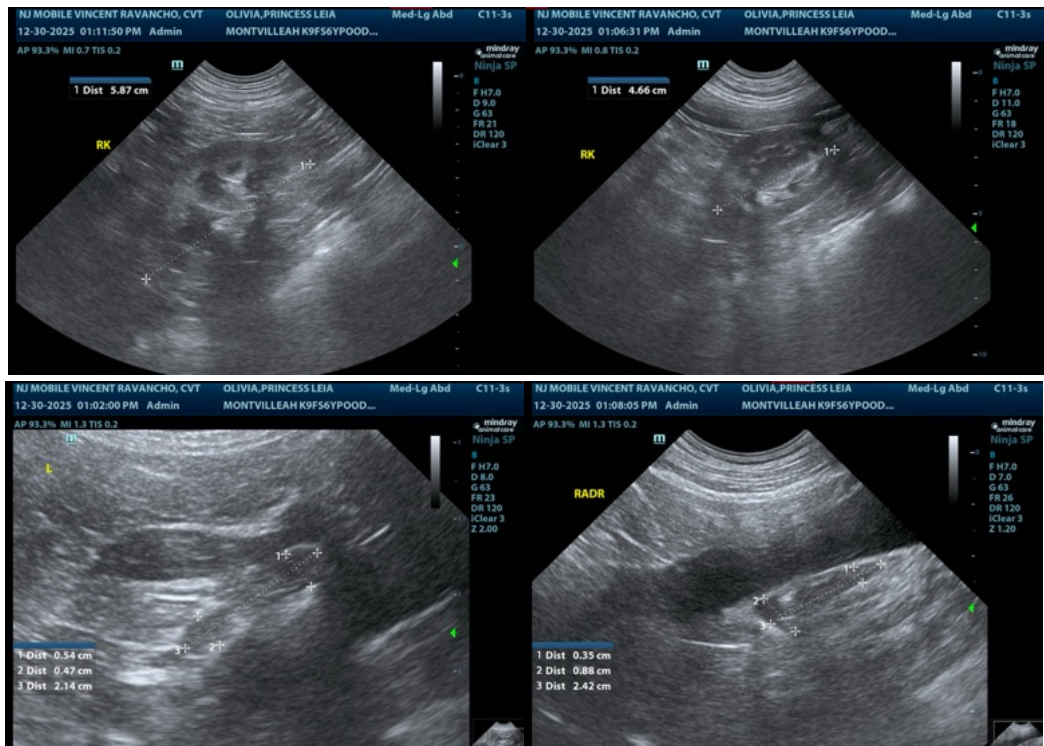
The base and limbs of the **pancreas** were observed to be largely isoechoic to surrounding omental fat. Pancreatic duct and capsular contour were acceptably normal and parenchyma respected normal curvilinear patterns. No overt evidence of active inflammatory or neoplastic disease was noted.

**ULTRASONOGRAPHIC FINDINGS**

Structurally normal abdomen.

**INTERPRETATION OF THE FINDINGS & FURTHER RECOMMENDATIONS**

There was no evidence of primary disease related to the glaucoma in this patient.





**PATIENT**

Princess Leia Olivia

**SPECIES**

Canine

**BREED**

Poodle Mix

**SEX**

Spayed female

**AGE**

6 ½ years

**WEIGHT**

66.9 lbs

**INTERPRETED BY**

Eric Lindquist, DMV,  
 DABVP (CFM), Cert. IVUSS, CEO of SonoPath.com

**IMAGING PERFORMED BY**

Vincent Ravancho

**HOSPITAL NAME**

Montville AH

**REFERRING VET**

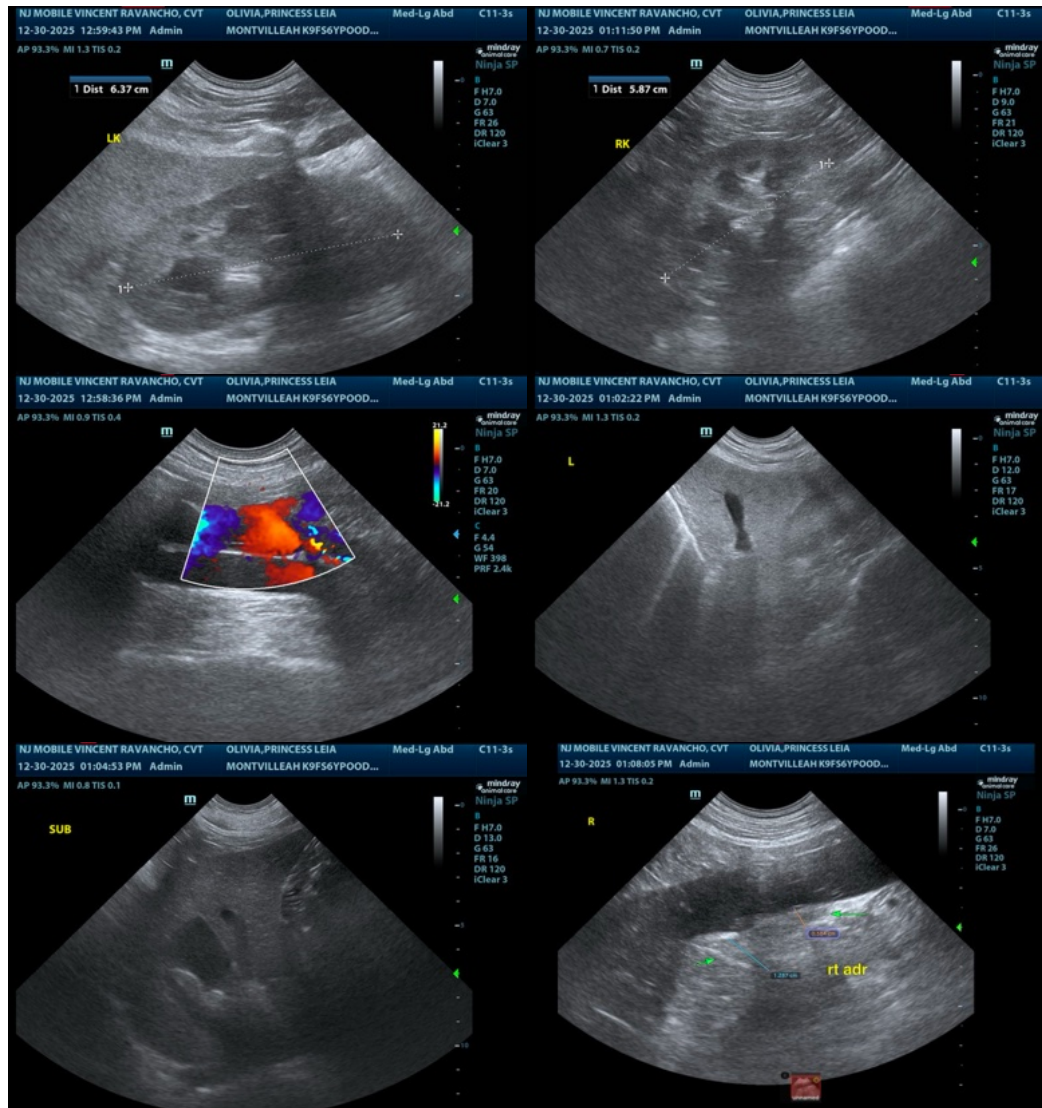
Dr. Schubert

**INVOICE**

69694

**DATE**

12/30/25



The information and recommendations provided are based on the images presented by the referring veterinarian/sonographer. No evaluation can be communicated regarding pathology that was not visible in the image/video clips provided.

Thank you for this referral. If the clinical or image interpretation does not parallel your findings or if I can be of any further assistance please contact me.

Eric Lindquist, DMV, DABVP (CFM), Cert. IVUSS, CEO of SonoPath.com

Info@SonoPath.com