



## PATIENT

Pickles Kelly

## SPECIES

Canine

## BREED

Mix

## SEX

Neutered male

## AGE

11 years

## WEIGHT

67 lbs

## INTERPRETED BY

Eric Lindquist, DMV,  
DABVP (CFM), Cert.  
IVUSS, CEO of  
SonoPath.com

## IMAGING PERFORMED BY

Vincent Ravancho

## HOSPITAL NAME

Bergen County VC

## REFERRING VET

Dr. Santo

## INVOICE

69300

## DATE

12/3/25

## PRESENTING CLINICAL SIGNS

History: VPC

## ULTRASONOGRAPHIC EXAMINATION OF THE ABDOMEN

### *Urinary System*

The **urinary bladder**, trigone, and pelvic urethra presented normal thicknesses and normal tone. The ureters were not visible which is normal. Non-shadowing, non-obstructive calculus was noted and measured 0.6 cm. No evidence of inflammatory or neoplastic changes was noted. Ureteral papillae were normal.

The **kidneys** revealed largely normal size and structure, corticomedullary definition and ratio (cortex 1/3 of medulla) were essentially maintained with some age-related loss of curvilinear patterns regarding the capsule and C/M junction. The cortices presented largely uniform texture with some increased echogenicity expected for this age patient. Medullary structure differed distinctly from that of the cortex and no evidence of pelvic dilation was present. The left kidney measured 5.35 cm. The right kidney measured 6.2 cm.

### *Adrenal Glands*

Both **adrenal glands** were visualized and recognized as having normal shape, size, position and echogenicity for this breed. The phrenic vasculature, glandular echogenicity and detail were unremarkable. Capsule, cortex, and medullary definition were normal for this age patient. The left adrenal gland measured 2.23 x 0.75 cm at the caudal pole and 0.66 cm at the cranial pole. The right adrenal gland measured 2.78 x 0.56 cm at the cranial pole and 0.58 cm at the caudal pole.

### *Spleen*

The **spleen** in this patient was mildly enlarged with uniform parenchyma and was folded upon itself cranially. This is a positional variant and is not pathological. There was no evidence of significant disease.

### *Liver*

The **liver** images from right and left intercostal as well as subcostal views revealed subjectively normal liver size, contour, and structure. Some age-related parenchymal remodeling was noted but likely not clinically significant at this time. Occasional, non-disruptive nodular change was noted. Vascular and biliary tracts were of normal volume and no evidence of congestion was noted. The gallbladder presented some dependent debris with essentially normal contour. The cystic and common bile ducts were normal. No overt evidence of active inflammatory, infiltrative or regenerative pathology was noted but should be paired with current or past LE elevations regarding any clinical significance to this presentation. The hepatic lymph nodes were unremarkable.



**PATIENT**

Pickles Kelly

**SPECIES**

Canine

**BREED**

Mix

**SEX**

Neutered male

**AGE**

11 years

**WEIGHT**

67 lbs

**INTERPRETED BY**

Eric Lindquist, DMV,  
DABVP (CFM), Cert.  
IVUSS, CEO of  
SonoPath.com

**IMAGING PERFORMED BY**

Vincent Ravancho

**HOSPITAL NAME**

Bergen County VC

**REFERRING VET**

Dr. Santo

**INVOICE**

69300

**DATE**

12/3/25

**Gastrointestinal**

There was some residual chyme and gas was noted in the **stomach**, yet not pathological. This is consistent with post prandial presentation. Transit of chyme into the small intestine was normal. Curvilinear patterns were maintained throughout the GI tract. No evidence of pathology. Small and large intestine demonstrated normal luminal chyme and stool consistency respectively. No obstructive or overt infiltrative disease was noted. No associated abnormal lymphatic activity was noted.

**Pancreas**

The base and limbs of the **pancreas** were observed to be largely isoechoic to surrounding omental fat. Some parenchymal remodeling, however, with mild deviation from curvilinear normalcy was observed. Pancreatic duct and capsular irregularities were present consistent with age related changes. If pain upon imaging (+ Murphy sign) was present or if the patient is focally painful in subxiphoid palpation then low-grade smoldering chronic pancreatitis should be suspected.

**ULTRASONOGRAPHIC FINDINGS**

Age related abdominal changes.

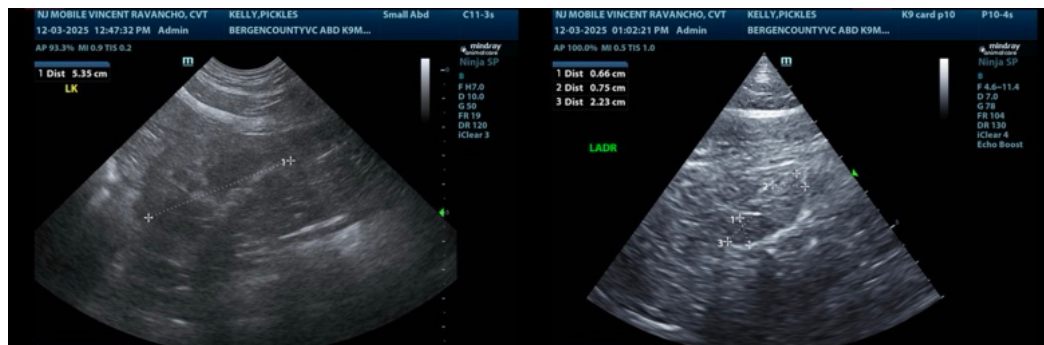
Slight, heterogenous nodular liver.

No evidence of primary disease influencing the arrhythmogenic activity.

Slight, non-shadowing bladder calculus, should be dissolvable with medical management.

**INTERPRETATION OF THE FINDINGS & FURTHER RECOMMENDATIONS**

Urinalysis work-up is warranted if not already performed.





**PATIENT**

Pickles Kelly

**SPECIES**

Canine

**BREED**

Mix

**SEX**

Neutered male

**AGE**

11 years

**WEIGHT**

67 lbs

**INTERPRETED BY**

Eric Lindquist, DMV,  
 DABVP (CFM), Cert.  
 IVUSS, CEO of  
 SonoPath.com

**IMAGING  
 PERFORMED BY**

Vincent Ravancho

**HOSPITAL NAME**

Bergen County VC

**REFERRING VET**

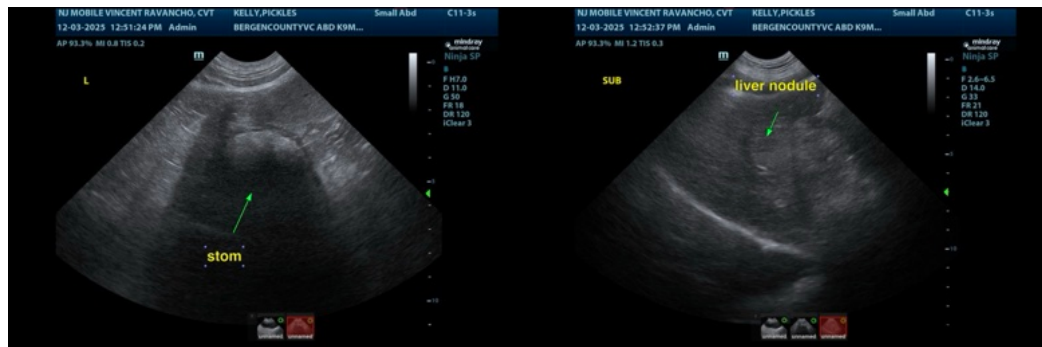
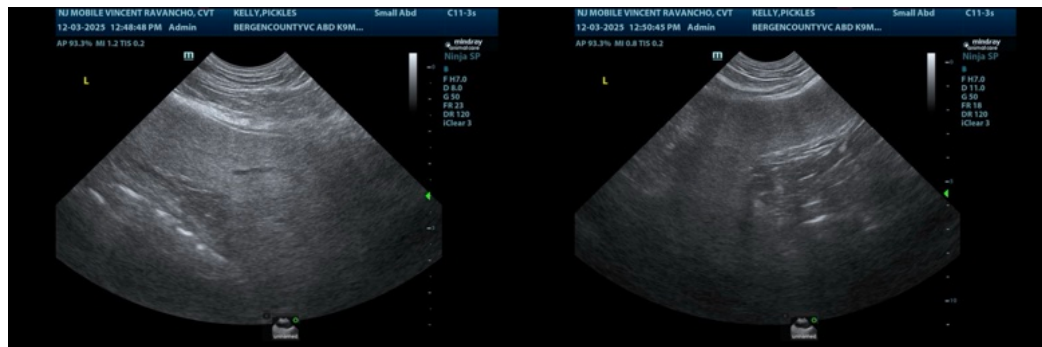
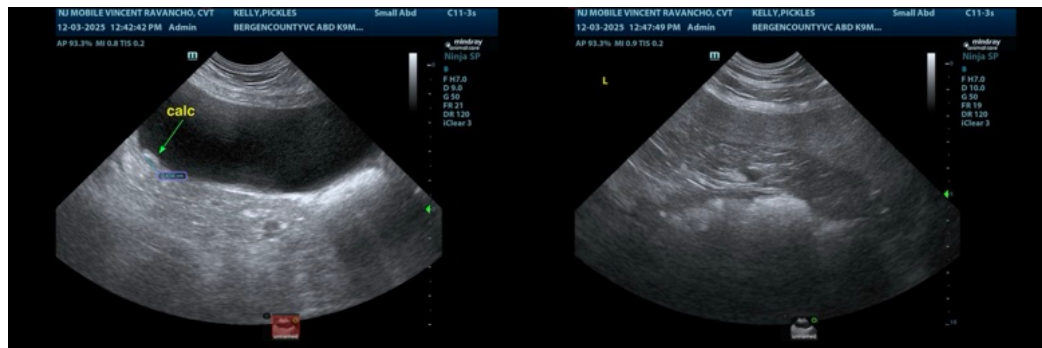
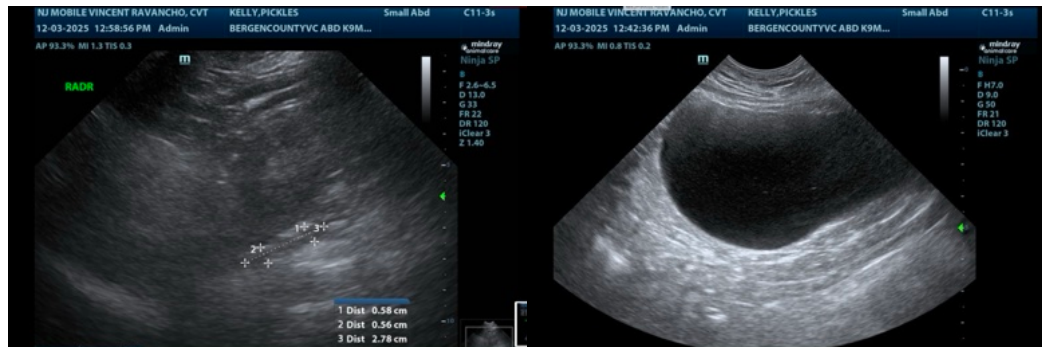
Dr. Santo

**INVOICE**

69300

**DATE**

12/3/25





**PATIENT**

Pickles Kelly

**SPECIES**

Canine

**BREED**

Mix

**SEX**

Neutered male

**AGE**

11 years

**WEIGHT**

67 lbs

**INTERPRETED BY**

Eric Lindquist, DMV,  
DABVP (CFM), Cert.  
IVUSS, CEO of  
SonoPath.com

**IMAGING  
PERFORMED BY**

Vincent Ravancho

**HOSPITAL NAME**

Bergen County VC

**REFERRING VET**

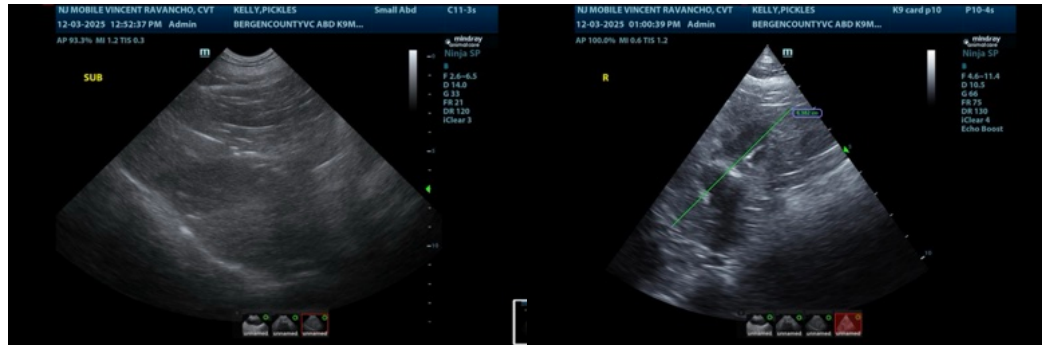
Dr. Santo

**INVOICE**

69300

**DATE**

12/3/25



The information and recommendations provided are based on the images presented by the referring veterinarian/sonographer. No evaluation can be communicated regarding pathology that was not visible in the image/video clips provided.

Thank you for this referral. If the clinical or image interpretation does not parallel your findings or if I can be of any further assistance please contact me.

Eric Lindquist, DMV, DABVP (CFM), Cert. IVUSS, CEO of SonoPath.com

Info@SonoPath.com