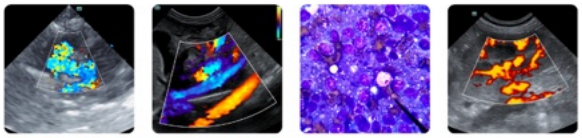

Clinical Sonography & Telecytology
Educational Teleconsultation Services™

PATIENT
Nova Stewart

SPECIES
Feline

BREED
Domestic Medium Hair

SEX
Neutered male

AGE
2 years

WEIGHT
16 lbs

INTERPRETED BY
Eric Lindquist, DMV, DABVP, Cert. IVUSS, CEO of SonoPath.com

IMAGING PERFORMED BY
Shari Reffi, CVT

HOSPITAL NAME
All Creatures Great and Small Denville

REFERRING VET
Dr. Ashmore

INVOICE
69610

DATE
12/29/25

PRESENTING CLINICAL SIGNS

History: Severe dyspnea episode 12/16/25. Dx w/HCM from rads. Current meds: Lasix 12.5mg bid; Enalapril 2.5mg s.i.d.
Abnormal PE/Chem/CBC/UA Results: WNL

ULTRASONOGRAPHIC EXAMINATION OF THE HEART

The echocardiogram in this patient demonstrated normal **left atrial** size based on 3 separate LA measurements. There was mild **mitral** valve insufficiency was noted. The **left ventricle** presented normal thicknesses with linear contour and was not dilated nor restricted. The **myocardium** presented normal echogenicity without subjective evidence of significant fibrotic or ischemic disease. **Contractility** of the ventricular walls was adequate and in normal range for this patient evidenced by the fractional shortening measurement and subjective evaluation of the different regions and angles of the myocardium. The **left ventricular outflow** tract demonstrated normal laminar flow and subjective structural integrity. The **right atrium** and auricle revealed normal size, structure and content. No evidence of masses was noted or chamber overload. **Tricuspid** valvular assessment demonstrated adequate linear morphology and kinetics. The **right ventricle** was of normal size (1/3 diameter of LV), chordae structure, myocardial echogenicity and thickness. **Pulmonic** tract assessment revealed normal valve structure, laminar flow, and diameter (approx.1:1 pa/ao ratio). No visible **pericardial** or free pleura fluid was noted or extra cardiac pathology in the visible planes. The cranial **mediastinum and pericardial regions** were free of masses in the visible window. A large amount of thoracic fat was noted in this patient.

E Wave Velocity 0.8 m/sec

FELINE CARDIAC PARAMETERS	BODY WEIGHT	HR (BPM)	IVSd (cm)	LVIDd (cm)	LVWd (cm)	FS (%)	EF (%)
NORMAL PARAMETER	------	150-240	0.3-0.6	1.0-2.1	0.25-0.6	35-67	80-100
PATIENT	16 lbs	164	0.54	1.83	0.58	28	58
FELINE CARDIAC PARAMETERS	**LA/AO** (M-mode)	**LA/AO HEART BASE** (Sisson)	**LAD** LA MAX 4 Chamber		**LVOT VEL.** (m/s)	**RVOT VEL.** (m/s)	**IVRT** (m/)
NORMAL PARAMETER	<1.5	1.6	0.7-1.7		<1.6	<1.3	40-60
PATIENT	1.4	1.4	1.2		1.9	0.9	NM

Adapted from June Boon,Veterinary Echocardiography,1998
Sisson D et al. JVIM 1991; 5: 232, Jacobs et al. Am J Vet Res 1985; 46:1705

ULTRASONOGRAPHIC FINDINGS

Normal echocardiogram with mitral insufficiency. Structurally and functionally normal heart.

PATIENT

Nova Stewart

SPECIES

Feline

BREED

Domestic Medium Hair

SEX

Neutered male

AGE

2 years

WEIGHT

16 lbs

INTERPRETED BY

Eric Lindquist, DMV, DABVP, Cert. IVUSS, CEO of SonoPath.com

IMAGING PERFORMED BY

Shari Reffi, CVT

HOSPITAL NAME

All Creatures Great and Small Denville

REFERRING VET

Dr. Ashmore

INVOICE

69610

DATE

12/29/25

INTERPRETATION OF THE FINDINGS & FURTHER RECOMMENDATIONS

A large amount of thoracic fat was noted. This may be creating the appearance of cardiomegaly. However, the volumes appear to be contained at the time of the sonogram.

No current volume overload or significant changes consistent with cardiomyopathy. Other causes of respiratory distress such as pain related disease or primary respiratory disease should be considered unless definitive radiographic findings demonstrate heart failure. I recommend diminishing the diuretic dose and stopping Enalapril unless hypertension is an issue. There is mitral insufficiency, yet this is well contained at this time. After diminishing the cardiac medications, I recommend a recheck echocardiogram in 2 weeks. If congestive heart failure is definitive on radiographs at the time of presentation then other causes of congestive heart failure such as myocarditis should be considered.

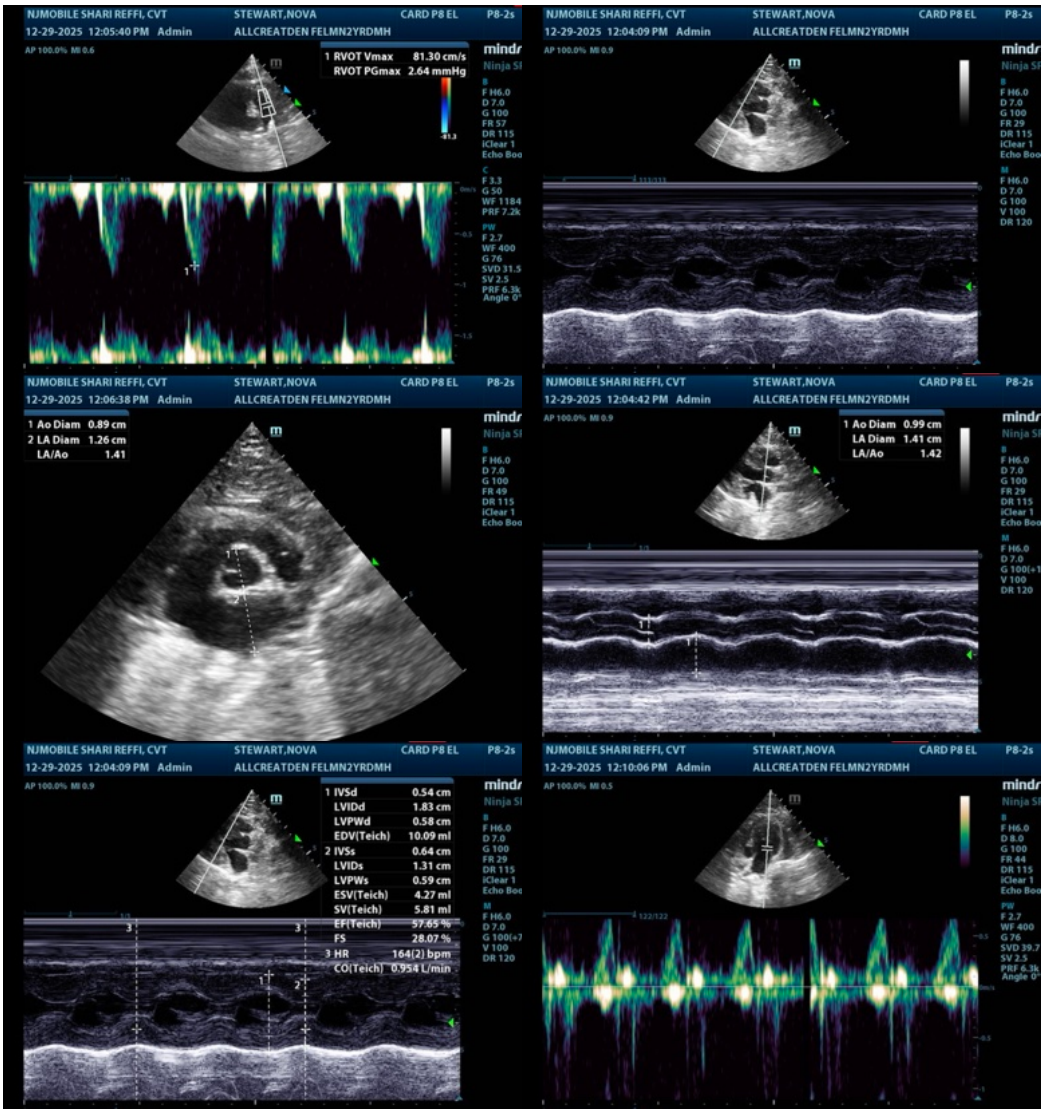

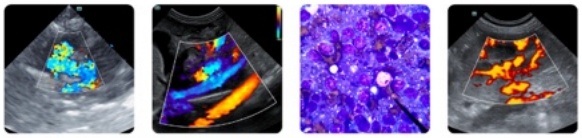

PATIENT

Nova Stewart

SPECIES

Feline

BREED

Domestic Medium Hair

SEX

Neutered male

AGE

2 years

WEIGHT

16 lbs

INTERPRETED BY

Eric Lindquist, DMV, DABVP, Cert. IVUSS, CEO of SonoPath.com

IMAGING PERFORMED BY

Shari Reffi, CVT

HOSPITAL NAME

All Creatures Great and Small Denville

REFERRING VET

Dr. Ashmore

INVOICE

69610

DATE

12/29/25

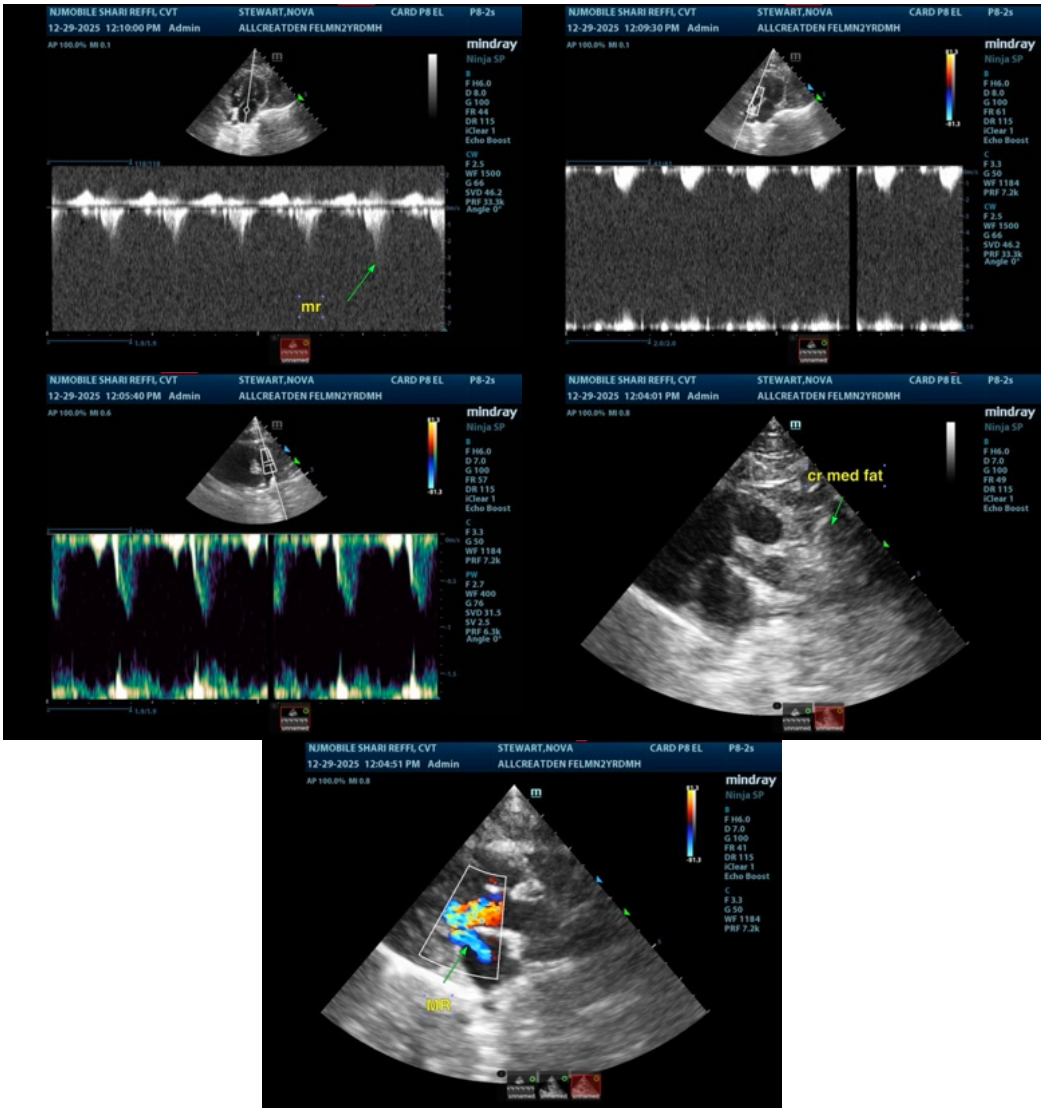

The information and recommendations provided are based on the images presented by the referring veterinarian/sonographer. No evaluation can be communicated regarding pathology that was not visible in the image/video clips provided.

Thank you for this referral. If the clinical or image interpretation does not parallel your findings or if I can be of any further assistance please contact me.

Eric Lindquist, DMV, DABVP, Cert. IVUSS, CEO of SonoPath.com

Info@SonoPath.com