



PATIENT

Buddy Tibbetts

SPECIES

Canine

BREED

Boxer Mix

SEX

Neutered male

AGE

11 years

WEIGHT

70 lbs

INTERPRETED BY

Eric Lindquist, DMV,
DABVP (CFM), Cert.
IVUSS, CEO of
SonoPath.com

IMAGING PERFORMED BY

Vincent Ravancho

HOSPITAL NAME

Park Ridge AH

REFERRING VET

Dr. Rosenblum

INVOICE

69237

DATE

12/2/25

PRESENTING CLINICAL SIGNS

History: Abdominal Rads: mild generalized hepatomegaly, mineralizing of gastric material. Hx of pancreatitis
Clinical findings: uncomfortable lying down, groaning and shifting position, tense palpitation but not reactive. Meds: Heartgard, soresto collar
^ ALT 129, ^ALP 599, ^Lipase 1061, ^chol 382, specCPL 1020

ULTRASONOGRAPHIC EXAMINATION OF THE ABDOMEN

Urinary System

The **urinary bladder**, trigone, and pelvic urethra presented normal thicknesses and normal tone. The ureters were not visible which is normal. No uroliths or sediment were visualized and anechoic urine was present. No evidence of inflammatory or neoplastic changes was noted. Ureteral papillae were normal.

The **kidneys** revealed normal size and structure, corticomedullary definition and ratio for this age. The cortices presented largely uniform texture with normal echogenic relationship to liver and spleen. Medullary structure differed distinctly from the cortex and no evidence of pelvic dilation was present. The capsules were acceptably uniform without significant irregularities. The left kidney measured 6.5 cm. The right kidney measured 6.22 cm.

Adrenal Glands

Both **adrenal glands** were visualized and recognized as having normal shape, size, position and echogenicity for this breed. The phrenic vasculature, glandular echogenicity and detail were unremarkable. Capsule, cortex, and medullary definition were normal for this age patient. The left adrenal gland 1.26 x 0.56 cm. The right adrenal gland measured 1.3 cm at the cranial pole and 0.7 cm at the caudal pole.

Spleen

The **spleen** presented a smooth homogeneous parenchyma hyperechoic to liver and renal cortical parenchyma. The capsule was smooth without noticeable expansion or deviation from within the spleen or adjacent pathology. The splenic vasculature demonstrated normal volume without signs of congestion or thrombosis. No sonographic evidence of acute or chronic inflammatory, neoplastic, or infarctual changes was noted.

Liver

The **liver** images from right and left intercostal as well as subcostal views revealed subjectively normal liver size, contour, and structure. Some age-related parenchymal remodeling was noted but likely not clinically significant at this time. Vascular and biliary tracts were of normal volume and no evidence of congestion was noted. The gallbladder presented some dependent debris with essentially normal contour. The cystic and common bile ducts were normal. No overt evidence of active inflammatory,



PATIENT

Buddy Tibbetts

SPECIES

Canine

BREED

Boxer Mix

SEX

Neutered male

AGE

11 years

WEIGHT

70 lbs

INTERPRETED BY

Eric Lindquist, DMV,
DABVP (CFM), Cert.
IVUSS, CEO of
SonoPath.com

IMAGING PERFORMED BY

Vincent Ravancho

HOSPITAL NAME

Park Ridge AH

REFERRING VET

Dr. Rosenblum

INVOICE

69237

DATE

12/2/25

infiltrative or regenerative pathology was noted but should be paired with current or past LE elevations regarding any clinical significance to this presentation. The hepatic lymph nodes were unremarkable.

Gastrointestinal

Examination of the **gastrointestinal tract** revealed a stomach and intestine free of stasis, of normal wall thickness, acceptable curvilinear mural detail, and peristaltic activity. Small and large intestine demonstrated normal luminal chyme and stool consistency respectively. No obstructive or overt infiltrative disease was noted. No associated abnormal lymphatic activity was noted.

Pancreas

The base and limbs of the **pancreas** were observed to be largely isoechoic to surrounding omental fat. Pancreatic duct and capsular contour were acceptably normal and parenchyma respected normal curvilinear patterns. No overt evidence of active inflammatory or neoplastic disease was noted.

Free Abdomen

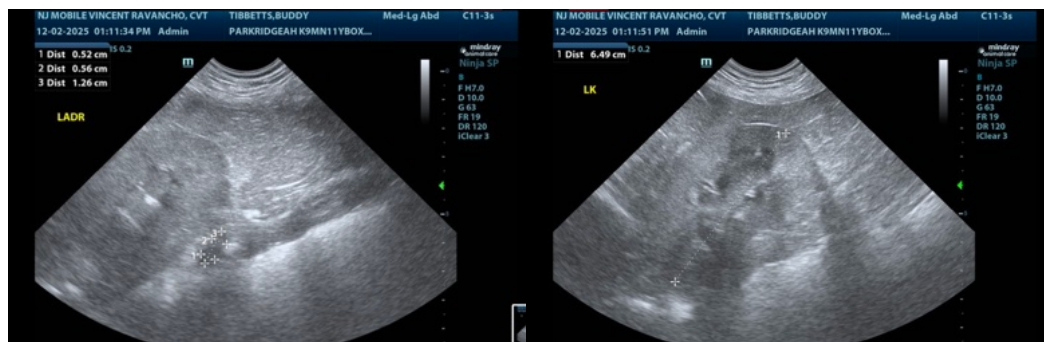
A large amount of abdominal fat was noted in this patient.

ULTRASONOGRAPHIC FINDINGS

Structurally unremarkable abdomen, post prandial presentation.

INTERPRETATION OF THE FINDINGS & FURTHER RECOMMENDATIONS

If the patient was n.p.o. at the time of the sonogram. I cannot rule out soft foreign matter within the stomach, yet visibility of the gastric content was poor owing to the presence of ingesta.





PATIENT

Buddy Tibbetts

SPECIES

Canine

BREED

Boxer Mix

SEX

Neutered male

AGE

11 years

WEIGHT

70 lbs

INTERPRETED BY

Eric Lindquist, DMV,
 DABVP (CFM), Cert.
 IVUSS, CEO of
 SonoPath.com

**IMAGING
 PERFORMED BY**

Vincent Ravancho

HOSPITAL NAME

Park Ridge AH

REFERRING VET

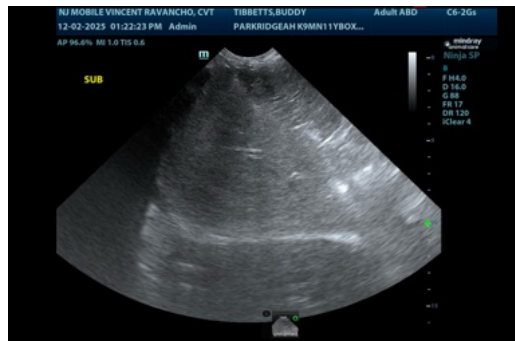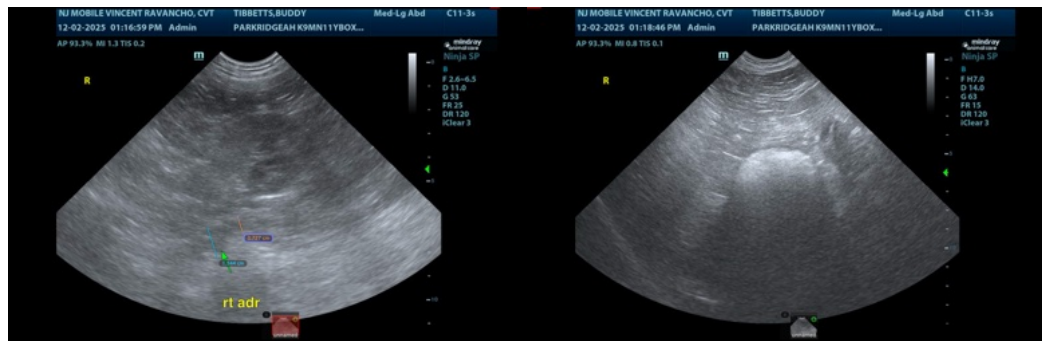
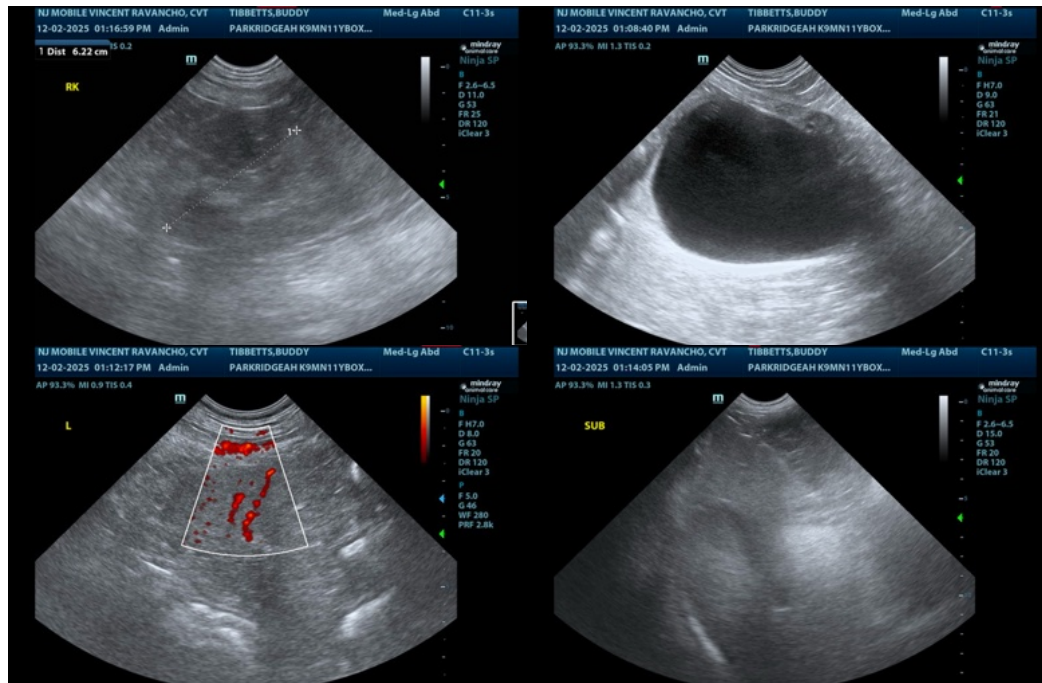
Dr. Rosenblum

INVOICE

69237

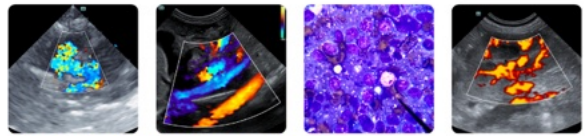
DATE

12/2/25



The information and recommendations provided are based on the images presented by the referring veterinarian/sonographer. No evaluation can be communicated regarding pathology that was not visible in the image/video clips provided.

Thank you for this referral. If the clinical or image interpretation does not parallel your findings or if I



PATIENT

can be of any further assistance please contact me.

Buddy Tibbetts

Eric Lindquist, DMV, DABVP (CFM), Cert. IVUSS, CEO of SonoPath.com

SPECIES

Info@SonoPath.com

Canine

BREED

Boxer Mix

SEX

Neutered male

AGE

11 years

WEIGHT

70 lbs

INTERPRETED BY

Eric Lindquist, DMV,
DABVP (CFM), Cert.
IVUSS, CEO of
SonoPath.com

**IMAGING
PERFORMED BY**

Vincent Ravancho

HOSPITAL NAME

Park Ridge AH

REFERRING VET

Dr. Rosenblum

INVOICE

69237

DATE

12/2/25