**PATIENT**

Chubbs Stewart

**SPECIES**

Canine

**BREED**

Pug

**SEX**

Neutered male

**AGE**

7 years

**WEIGHT**

17.2 lbs

**INTERPRETED BY**

Eric Lindquist, DMV, DABVP (CFM), Cert. IVUSS, CEO of SonoPath.com

**IMAGING PERFORMED BY**

Kerri Becker

**HOSPITAL NAME**

Park Ridge AH

**REFERRING VET**

Dr. Doyle

**INVOICE**

69463

**DATE**

12/19/25

## PRESENTING CLINICAL SIGNS

History: Recheck splenic nodules, no changes at home. HX splenic nodules found incidentally on AUS and monitoring. HX urinary incontinence. Proin and apoquel.

## ULTRASONOGRAPHIC EXAMINATION OF THE ABDOMEN

### *Urinary System*

The **urinary bladder**, trigone, and pelvic urethra presented normal thicknesses and normal tone. The pelvic urethra was imaged 2.0 cm beyond the cystourethral junction and appeared normal. The ureters were not visible which is normal. No uroliths or sediment were visualized and anechoic urine was present. No evidence of inflammatory or neoplastic changes was noted. Ureteral papillae were normal.

The **kidneys** revealed normal size and structure, corticomedullary definition and ratio for this age. The cortices presented largely uniform texture with normal echogenic relationship to liver and spleen. Medullary structure differed distinctly from the cortex and no evidence of pelvic dilation was present. The capsules were acceptably uniform without significant irregularities. The right kidney measured 3.7 cm. The left kidney measured 4.08 cm.

### *Adrenal Glands*

Both **adrenal glands** were visualized and recognized as having normal shape, size, position and echogenicity for this breed. The phrenic vasculature, glandular echogenicity and detail were unremarkable. Capsule, cortex, and medullary definition were normal for this age patient. The left adrenal gland measured 1.7 x 0.44 cm at the cranial pole and 0.38 cm at the caudal pole. The right adrenal gland measured 1.8 x 0.73 cm at the cranial pole and 0.39 cm at the caudal pole.

### *Spleen*

The **spleen** was largely normal with no overt evidence of pathology other than subtle, heterogenous changes. No overt nodules are present. The spleen was slightly subnormal in size.

### *Liver*

The **liver** images submitted revealed subjectively normal liver size, contour, and structure. Parenchymal echogenicity was naturally coarse and hypoechoic to the spleen. Vascular and biliary tracts were of normal volume with no evidence of congestion. The gallbladder presented acceptably thin walls with primarily anechoic content. The cystic and common bile ducts were normal. No pathological hepatic lymphadenopathy was evident. No overt structural evidence of inflammatory, infiltrative or regenerative pathology was evident.

**PATIENT**

Chubbs Stewart

**SPECIES**

Canine

**BREED**

Pug

**SEX**

Neutered male

**AGE**

7 years

**WEIGHT**

17.2 lbs

**INTERPRETED BY**

Eric Lindquist, DMV, DABVP (CFM), Cert. IVUSS, CEO of SonoPath.com

**IMAGING PERFORMED BY**

Kerri Becker

**HOSPITAL NAME**

Park Ridge AH

**REFERRING VET**

Dr. Doyle

**INVOICE**

69463

**DATE**

12/19/25

### *Gastrointestinal*

Examination of the **gastrointestinal tract** revealed a stomach and intestine free of stasis, of normal wall thickness, acceptable curvilinear mural detail, and peristaltic activity. Small and large intestine demonstrated normal luminal chyme and stool consistency respectively. No obstructive or overt infiltrative disease was noted. No associated abnormal lymphatic activity was noted.

### *Pancreas*

The base and limbs of the **pancreas** were observed to be largely isoechoic to surrounding omental fat. Pancreatic duct and capsular contour were acceptably normal and parenchyma respected normal curvilinear patterns. No overt evidence of active inflammatory or neoplastic disease was noted.

## ULTRASONOGRAPHIC FINDINGS

Resolved splenic presentation, likely sinusoidal nodules.

## INTERPRETATION OF THE FINDINGS & FURTHER RECOMMENDATIONS

Splenic nodules can come and go as it is a sinusoidal organ can create a nodular appearance, yet may be temporary. That is likely the case in this patient. There was no evidence of significant disease. There is no necessity for recheck. The spleen was slightly small, vascular status in this patient may play a role in the sinusoidal accumulation or nodular appearance. However, there was no evidence of nodular change at this time and no evidence of pathology.

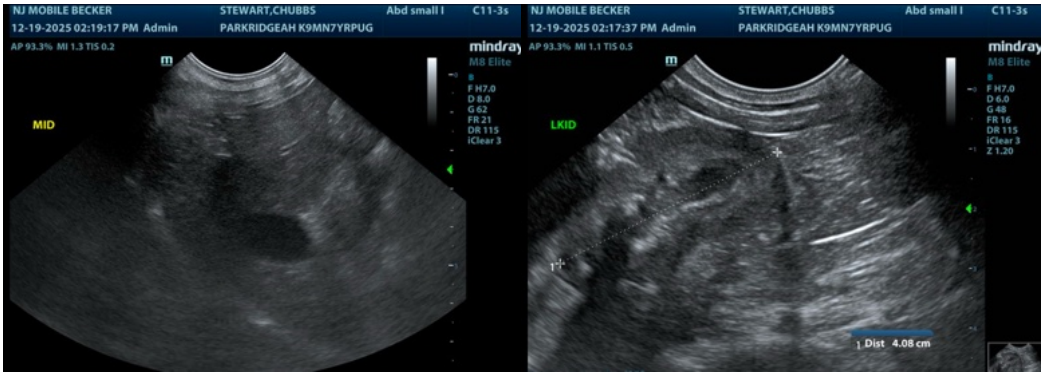

New Jersey Mobile
FUELED BY SONOPATH VETERINARY ULTRASOUND

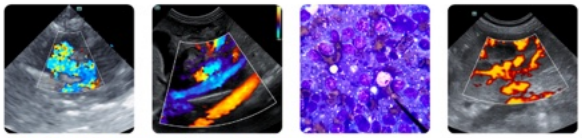

Clinical Sonography & Telecytology
Educational Teleconsultation Services™

SonoPath
FOSTERING THE ART OF VETERINARY MEDICINE™
www.SonoPath.com
info@sonopath.com 800.838.4268

**PATIENT**

Chubbs Stewart

**SPECIES**

Canine

**BREED**

Pug

**SEX**

Neutered male

**AGE**

7 years

**WEIGHT**

17.2 lbs

**INTERPRETED BY**

Eric Lindquist, DMV, DABVP (CFM), Cert. IVUSS, CEO of SonoPath.com

**IMAGING PERFORMED BY**

Kerri Becker

**HOSPITAL NAME**

Park Ridge AH

**REFERRING VET**

Dr. Doyle

**INVOICE**

69463

**DATE**

12/19/25

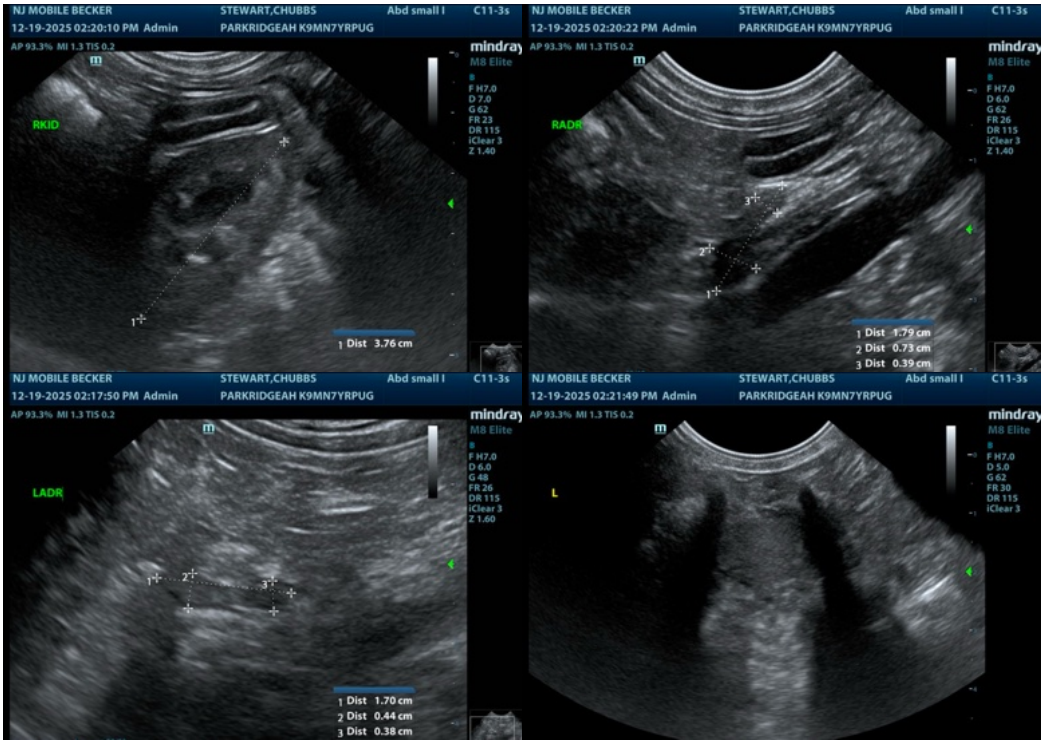


**The information and recommendations provided are based on the images presented by the referring veterinarian/sonographer. No evaluation can be communicated regarding pathology that was not visible in the image/video clips provided.**

Thank you for this referral. If the clinical or image interpretation does not parallel your findings or if I can be of any further assistance please contact me.

Eric Lindquist, DMV, DABVP (CFM), Cert. IVUSS, CEO of SonoPath.com

Info@SonoPath.com