



PATIENT

Louie Bolkema

SPECIES

Feline

BREED

Domestic Shorthair

SEX

Neutered male

AGE

16 year

WEIGHT

11.5 lbs

INTERPRETED BY

Eric Lindquist, DMV
DABVP, Cert. IVUS

IMAGING PERFORMED BY

Rebecca Hamilton

HOSPITAL NAME

Ramapo Valley AH

REFERRING VET

Dr. Katara

INVOICE

69540

DATE

12/11/25

PRESENTING CLINICAL SIGNS

History: Primary cardiac Dz? Atelectasis lesion of TxR, ^ BV sounds. was tx w/ Clavamox and Pradofloxacin. Then tx w/ Convenia. Significant lung pathology on TxRs.
Abnormal PE/Chem/CBC/UA Results: 11/19/25 WNL (T4 not on rDVM BW)

ULTRASONOGRAPHIC EXAMINATION OF THE HEART

The echocardiogram in this patient demonstrated normal **left atrial** size based on 3 separate LA measurements. The cranial and caudal **mitral** valve leaflets presented normal linear structure and kinetics. The **left ventricle** presented normal thicknesses with linear contour and was not dilated nor restricted. The **myocardium** presented normal echogenicity without subjective evidence of significant fibrotic or ischemic disease. **Contractility** of the ventricular walls was adequate and in normal range for this patient evidenced by the fractional shortening measurement and subjective evaluation of the different regions and angles of the myocardium. The **left ventricular outflow** tract demonstrated normal laminar flow and subjective structural integrity. The **right atrium** and auricle revealed normal size, structure and content. No evidence of masses was noted or chamber overload. **Tricuspid** valvular assessment demonstrated adequate linear morphology and kinetics. The **right ventricle** was of normal size (1/3 diameter of LV), chordae structure, myocardial echogenicity and thickness. **Pulmonic** tract assessment revealed normal valve structure, laminar flow, and diameter (approx.1:1 pa/ao ratio). No visible **pericardial** or free pleura fluid was noted or extra cardiac pathology in the visible planes. The cranial **mediastinum and pericardial regions** were free of masses in the visible window. Areas of lung consolidation were noted in this patient.

FELINE CARDIAC PARAMETERS	BODY WEIGHT	HR (BPM)	IVSd (cm)	LVIDd (cm)	LVWd (cm)	FS (%)	EF (%)
NORMAL PARAMETER	-----	150-240	0.3-0.6	1.0-2.1	0.25-0.6	35-67	80-100
PATIENT	11.5 lbs	200	0.48	1.45	0.43	45	90
FELINE CARDIAC PARAMETERS	LA/AO (M-mode)	LA/AO HEART BASE (Sisson)	LAD LA MAX 4 Chamber		LVOT VEL. (m/s)	RVOT VEL. (m/s)	IVRT (m/)
NORMAL PARAMETER	<1.5	1.6	0.7-1.7		<1.6	<1.3	40-60
PATIENT	1.3	1.4	1.4		1.0	0.8	NM
Adapted from June Boon, Veterinary Echocardiography, 1998 Sisson D et al. JVIM 1991; 5: 232, Jacobs et al. Am J Vet Res 1985; 46:1705							



PATIENT

Louie Bolkema

ULTRASONOGRAPHIC FINDINGS

Non-cardiogenic lung consolidations.

SPECIES

Feline

INTERPRETATION OF THE FINDINGS & FURTHER RECOMMENDATIONS

No consolidation was evident that was accessible for FNA. An abdominal sonogram is recommended to assess for primary disease and chest CT would be ideal in this patient. Management for bronchioalveolar infection is warranted if no evidence of neoplasia is noted in the abdomen. If the patient is not responding then chest CT and potential ultrasound-guided FNA under sedation for CT would be appropriate.

BREED

Domestic Shorthair

SEX

Neutered male

ABOUT SONOPATH CT SERVICES:

SonoPath CT Services are offered at the SonoPath Imaging and Veterinary Education Center, 141 Main St (rt 206), Andover, New Jersey, a 20-minute drive west on route 80/206 North from the route 80/287 interchange/Parsippany, New Jersey. More information can be found at <https://sonopath.com/services/vetimaging/>

AGE

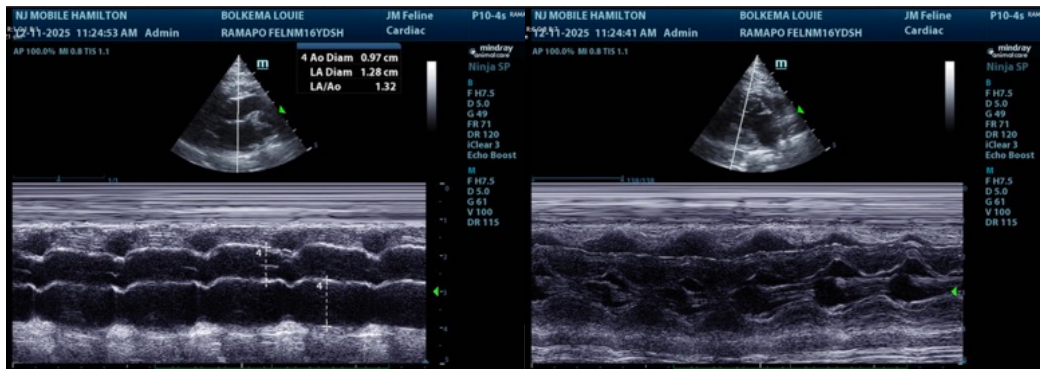16 year

WEIGHT

11.5 lbs

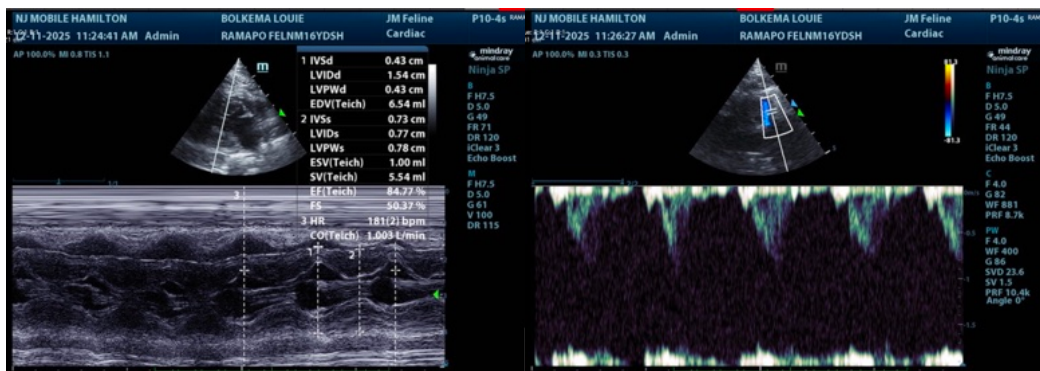
INTERPRETED BY

Eric Lindquist, DMV DABVP, Cert. IVUSS



IMAGING PERFORMED BY

Rebecca Hamilton



HOSPITAL NAME

Ramapo Valley AH

REFERRING VET

Dr. Katara

INVOICE

69540

DATE

12/11/25



PATIENT

Louie Bolkema

SPECIES

Feline

BREED

Domestic Shorthair

SEX

Neutered male

AGE

16 year

WEIGHT

11.5 lbs

INTERPRETED BY

Eric Lindquist, DMV
DABVP, Cert. IVUSS

IMAGING PERFORMED BY

Rebecca Hamilton

HOSPITAL NAME

Ramapo Valley AH

REFERRING VET

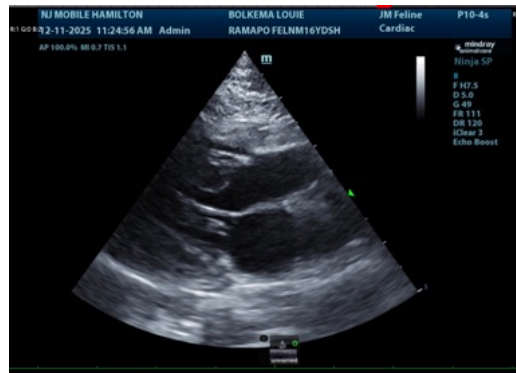
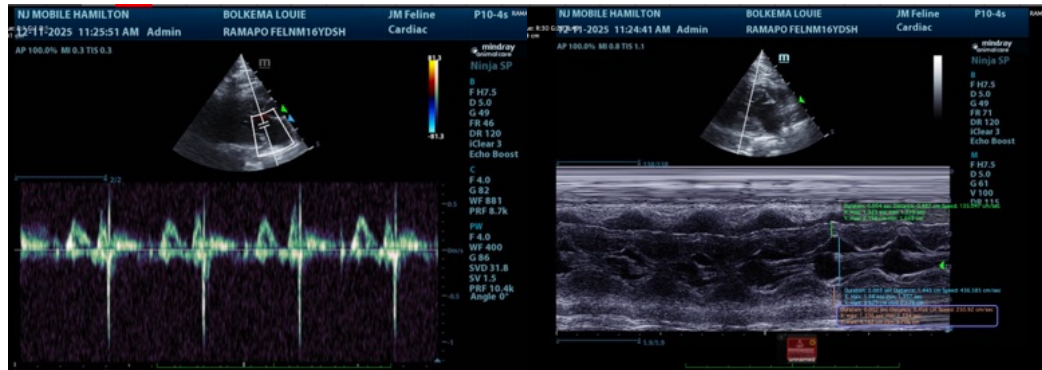
Dr. Katara

INVOICE

69540

DATE

12/11/25



The information and recommendations provided are based on the images presented by the referring veterinarian/sonographer. No evaluation can be communicated regarding pathology that was not visible in the image/video clips provided.

Thank you for this referral. If the clinical or image interpretation does not parallel your findings or if I can be of any further assistance please contact me.

Eric Lindquist, DMV, DABVP, Cert. IVUSS, CEO of SonoPath.com

info@SonoPath.com