



**PATIENT**

Hanuman Borrero

**SPECIES**

Canine

**BREED**

Pomeranian Mix

**SEX**

Male

**AGE**

7 months

**WEIGHT**

13.6 lbs

**INTERPRETED BY**

Eric Lindquist, DMV,  
DABVP (CFM), Cert.  
IVUSS, CEO of  
SonoPath.com

**IMAGING PERFORMED BY**

Kerri Becker

**HOSPITAL NAME**

Englewood VC

**REFERRING VET**

Dr. Ezik

**INVOICE**

68421

**DATE**

11/7/25

**PRESENTING CLINICAL SIGNS**

History: Newly diagnosed HM grade 5 both sided.

**ULTRASONOGRAPHIC EXAMINATION OF THE HEART**

The echocardiogram in this patient presented mild volume overload of the **left atrium** and **left ventricle** with **mitral** insufficiency. Moderate filling of the left atrium was noted with thickened and prolapse of the mitral valve leaflet. The posterior leaflet appeared stiffened. The anterior mitral valve was vegetative. The mitral insufficiency was moderate and eccentric. The **right atrium** and auricle revealed normal size, structure and content. No evidence of masses was noted. **Tricuspid** valvular assessment demonstrated adequate linear morphology and kinesis. The **right ventricle** was of normal size (1/3 diameter of LV), chordae structure, myocardial echogenicity and thickness. **Pulmonary outflow** tract assessment revealed normal valve structure, laminar flow, and diameter (approx. 1:1 pa/ao ratio). No visible **pericardial** or free pleura fluid was noted. The cranial **mediastinum and pericardial and extra-cardiac regions** were free of masses in the visible window. The hepatic veins were not dilated.

CANINE CARDIAC PARAMETERS	MR VMAX (m/s)	TR VMAX (m/s)	LA/AO	LA/AO (Heart Base)	FS (%)	EF (%)	EPSS (cm)
NORMAL PARAMETER	4.5-5.5	<2.7	1.3	<1.6	28-40	40-100	<0.6
PATIENT	6.0		1.3	12.0	30	50	0.2
CANINE CARDIAC PARAMETERS	HR (BPM)	AV VMAX (m/s)	PV MAX (m/s)	BODY WEIGHT	LA 2D short axis Base view (cm)	LVIDd Avg; 2D and m-mode short axis (cm)	LVIDs Avg; 2D and m-mode short axis (cm)
NORMAL PARAMETER	50-100	0.7-1.7	0.7-1.6	BELOW	BELOW	BELOW	BELOW
PATIENT		1.3	0.5	13.6 lbs	3.9	3.15	

**ULTRASONOGRAPHIC FINDINGS**

Mitral insufficiency, possible endocarditis or primary mitral valve dysplasia with mild volume overload of the left atrium and left ventricle.

Stage B2 valvular disease.

**INTERPRETATION OF THE FINDINGS & FURTHER RECOMMENDATIONS**

I cannot rule out an underlying endocarditis. I recommend initiating Pimobendan at 0.3 mg/kg b.i.d. EKG and blood pressure measurements are warranted. Blood culture would be ideal as well to assess for occult infection/endocarditis. Cardiologist review may be optimal in this patient especially given the



**PATIENT**

potential breeding line implications.

Hanuman Borrero

The heart has minor volume overload and is working to compensate for the valvular insufficiency. Target respiratory rate is < 20 resp/minute after therapy. After initiating or adjusting therapy, I recommend recheck on the clinical exam, BUN, Creatinine, USG, Chest radiographs & Blood pressure in 5-7 days. Recheck echo in 3-6 months, earlier if clinical decompensation is occurring. Minor anesthetic risk for a brief procedure at this time. Repeat preanesthetic echo is ideal if anesthesia is eventually necessary. A suggested anesthetic combination would involve Torbutrol premed, propofol induction, Isoflurane maintenance or equivalent protocol.

**SPECIES**

Canine

**BREED**

Pomeranian Mix

**SEX**

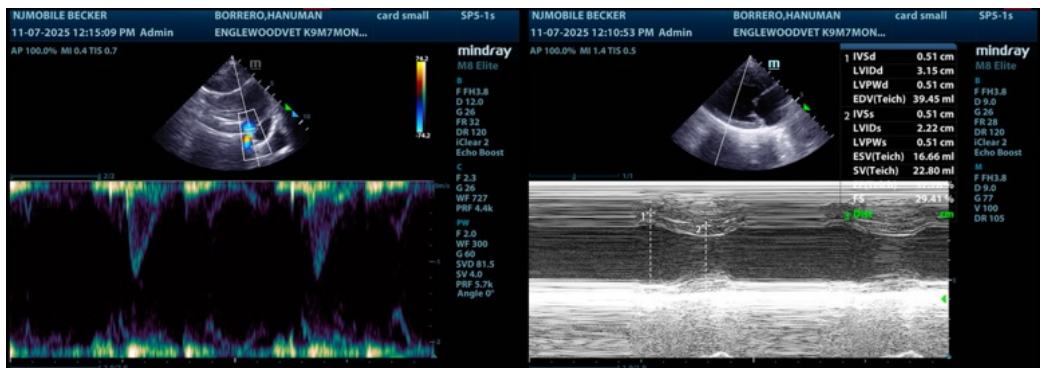
Male

**AGE**

7 months

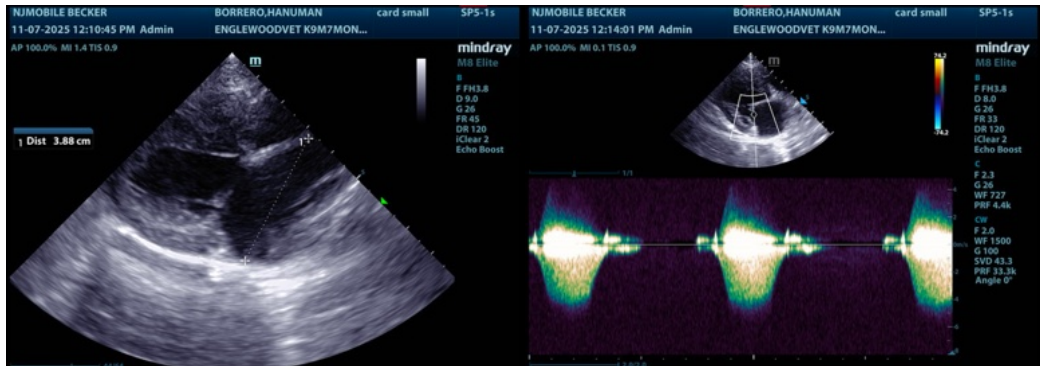
**WEIGHT**

13.6 lbs



**INTERPRETED BY**

Eric Lindquist, DMV,  
 DABVP (CFM), Cert.  
 IVUSS, CEO of  
 SonoPath.com



**IMAGING PERFORMED BY**

Kerri Becker

**HOSPITAL NAME**

Englewood VC

**REFERRING VET**

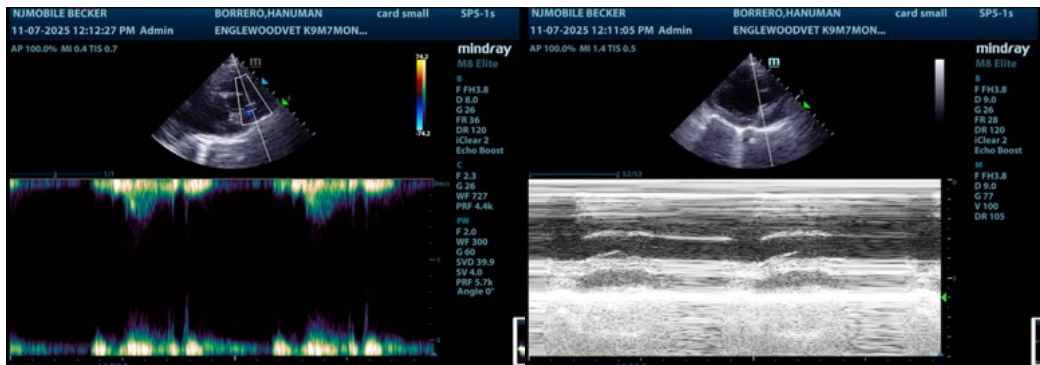
Dr. Ezik

**INVOICE**

68421

**DATE**

11/7/25





**PATIENT**

Hanuman Borrero

**SPECIES**

Canine

**BREED**

Pomeranian Mix

**SEX**

Male

**AGE**

7 months

**WEIGHT**

13.6 lbs

**INTERPRETED BY**

Eric Lindquist, DMV, DABVP (CFM), Cert. IVUSS, CEO of SonoPath.com

**IMAGING PERFORMED BY**

Kerri Becker

**HOSPITAL NAME**

Englewood VC

**REFERRING VET**

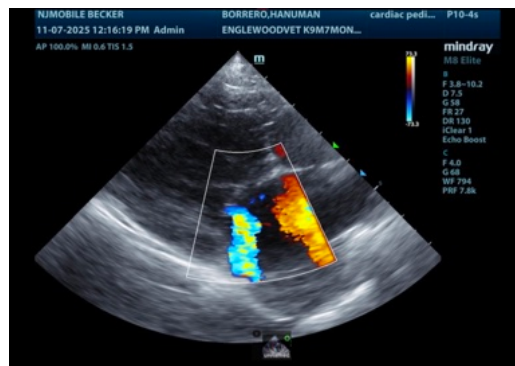
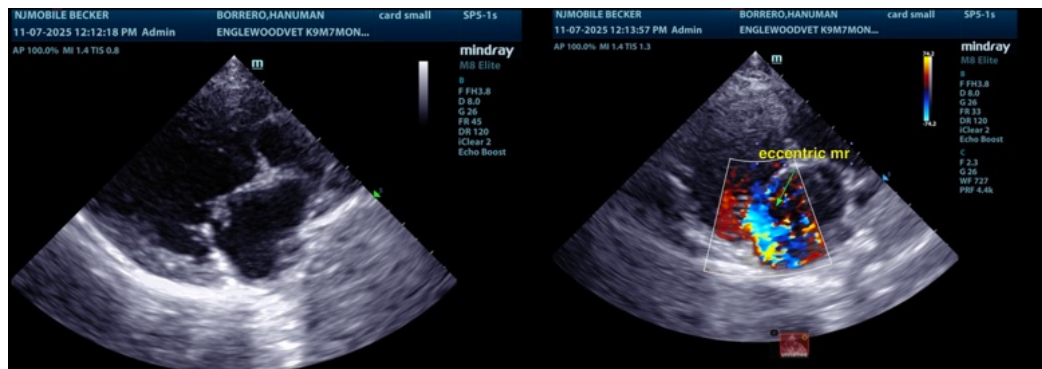
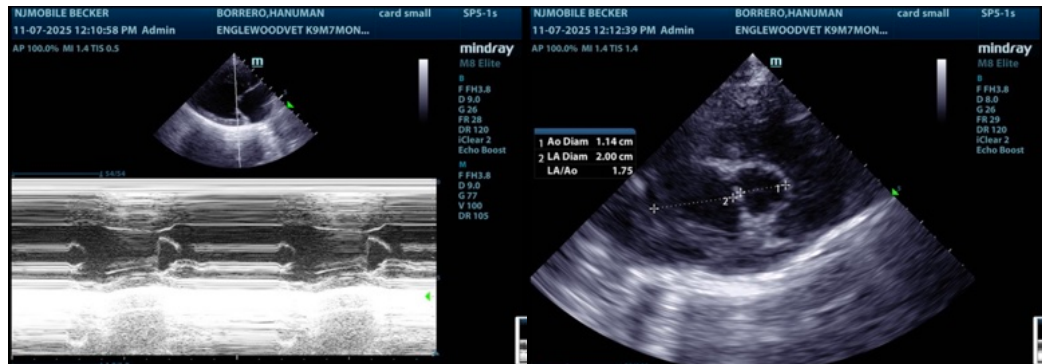
Dr. Ezik

**INVOICE**

68421

**DATE**

11/7/25



The information and recommendations provided are based on the images presented by the referring veterinarian/sonographer. No evaluation can be communicated regarding pathology that was not visible in the image/video clips provided.

Thank you for this referral. If the clinical or image interpretation does not parallel your findings or if I can be of any further assistance please contact me.

Eric Lindquist, DMV, DABVP (CFM), Cert. IVUSS, CEO of SonoPath.com

Info@SonoPath.com