



**PATIENT**

Oliver Luftman

**SPECIES**

Canine

**BREED**

Shih Tzu

**SEX**

Neutered male

**AGE**

7 years

**WEIGHT**

11.8 lbs

**INTERPRETED BY**

Eric Lindquist, DMV  
DABVP, Cert. IVUSS

**IMAGING PERFORMED BY**

Rebecca Hamilton

**HOSPITAL NAME**

GlenRock VH

**REFERRING VET**

Dr. Stekler

**INVOICE**

68397

**DATE**

11/6/25

**PRESENTING CLINICAL SIGNS**

History: Increased SGPT  
Abnormal PE/Chem/CBC/UA Results: AST (SGOT) 91, ALT (SGPT) 435

**ULTRASONOGRAPHIC EXAMINATION OF THE ABDOMEN**

**Urinary System**

The **urinary bladder**, trigone, and pelvic urethra presented normal thicknesses and normal tone. The pelvic urethra was imaged 3.0 cm beyond the cystourethral junction and appeared normal. The ureters were not visible which is normal. No uroliths or sediment were visualized and anechoic urine was present. No evidence of inflammatory or neoplastic changes was noted. Ureteral papillae were normal.

The **kidneys** revealed normal size and structure, corticomedullary definition and ratio for this age. The cortices presented largely uniform texture with normal echogenic relationship to liver and spleen. Medullary structure differed distinctly from the cortex and no evidence of pelvic dilation was present. The capsules were acceptably uniform without significant irregularities. The left kidney measured 3.75 cm. The right kidney measured 4.22 cm.

**Adrenal Glands**

Both **adrenal glands** were visualized and recognized as having normal shape, size, position and echogenicity for this breed. The phrenic vasculature, glandular echogenicity and detail were unremarkable. Capsule, cortex, and medullary definition were normal for this age patient. The right adrenal gland measured 2.17 x 0.77 cm at the cranial pole and 0.49 cm at the caudal pole. The left adrenal gland measured 1.5 x 0.43 cm.

**Spleen**

The **spleen** presented a smooth homogeneous parenchyma hyperechoic to liver and renal cortical parenchyma. The capsule was smooth without noticeable expansion or deviation from within the spleen or adjacent pathology. The splenic vasculature demonstrated normal volume without signs of congestion or thrombosis. No sonographic evidence of acute or chronic inflammatory, neoplastic, or infarctual changes was noted.

**Liver**

The **liver** was normal in size with normal vascularity. There was no evidence of intrahepatic or extrahepatic shunting. The liver revealed coarse architecture with a mild amount of remodeling. The gallbladder and common bile duct were unremarkable. The hepatic lymph nodes were unremarkable.



**PATIENT**

Oliver Luftman

**SPECIES**

Canine

**BREED**

Shih Tzu

**SEX**

Neutered male

**AGE**

7 years

**WEIGHT**

11.8 lbs

**INTERPRETED BY**

Eric Lindquist, DMV  
DABVP, Cert. IVUSS

**IMAGING PERFORMED BY**

Rebecca Hamilton

**HOSPITAL NAME**

GlenRock VH

**REFERRING VET**

Dr. Stekler

**INVOICE**

68397

**DATE**

11/6/25

**Gastrointestinal**

There was some residual chyme and gas was noted in the **stomach**, yet not pathological. This is consistent with post prandial presentation. Transit of chyme into the small intestine was normal. Curvilinear patterns were maintained throughout the GI tract. No evidence of pathology. Small and large intestine demonstrated normal luminal chyme and stool consistency respectively. No obstructive or overt infiltrative disease was noted. No associated abnormal lymphatic activity was noted.

**Pancreas**

The base and limbs of the **pancreas** were observed to be largely isoechoic to surrounding omental fat. Pancreatic duct and capsular contour were acceptably normal and parenchyma respected normal curvilinear patterns. No overt evidence of active inflammatory or neoplastic disease was noted.

**ULTRASONOGRAPHIC FINDINGS**

Structurally unremarkable abdomen.  
Benign hepatopathy.

**INTERPRETATION OF THE FINDINGS & FURTHER RECOMMENDATIONS**

There was no evidence of significant disease. The patient likely has a history of cholangiohepatitis. FNA of the liver can be considered for further definition. Leptospirosis titers are indicated to ensure underlying occult infection is not an issue.

**Hepatic Support for Bile Acid Elevation +/- Hepatic Encephalopathy**

**Royal Canin Hepatic Support diet or Hills L/D, Metronidazole** (7.5 mg/kg PO bid) over the next 14 days, **Lactulose** (Oral: 3.1-3.7 g/5 ml lactulose in a syrup base) long term to target 2-3 soft stools/day, with a **high-quality protein supplement** of minor amount of **yogurt or cheddar cheese**. Monitor bile acids, with attention paid to dropping albumin, BUN or cholesterol. SAME and nutraceuticals as needed. **Ursodiol** (10-15 mg/kg p.o. q24h) can be considered as hepatoprotectant and to enhance bile flow. **Zinc** serum level keep between 200–500 ug/dl. If deficient then Tx zinc acetate 1-3 mg/kg/day. Gastrointestinal protectants are recommended if the patient is anorexic.

Internal medicine consult can be utilized through Sonopath.com. You can select the internal medicine drop down at <http://spa.sonopath.com/>.

One of the world's top internists & SonoPath associate Dr. Remo Lobetti BVSc, MMedVet, PhD, DECVIM can evaluate your case through SonoPath. <https://sonopath.com/resources/sonopath-services/internal-medicine-teleconsultation-services>



**PATIENT**

Oliver Luftman

**SPECIES**

Canine

**BREED**

Shih Tzu

**SEX**

Neutered male

**AGE**

7 years

**WEIGHT**

11.8 lbs

**INTERPRETED BY**

Eric Lindquist, DMV  
 DABVP, Cert. IVUSS

**IMAGING PERFORMED BY**

Rebecca Hamilton

**HOSPITAL NAME**

GlenRock VH

**REFERRING VET**

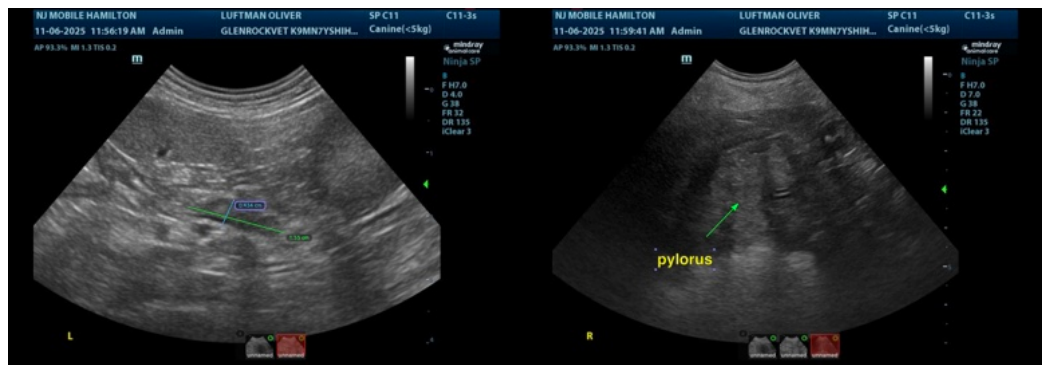
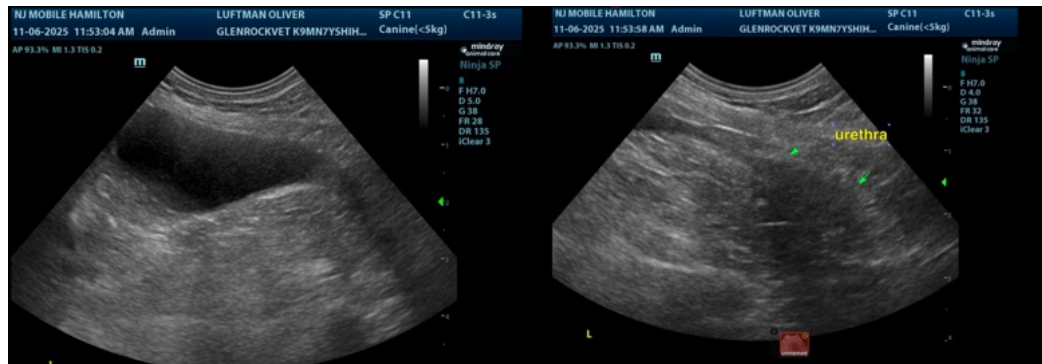
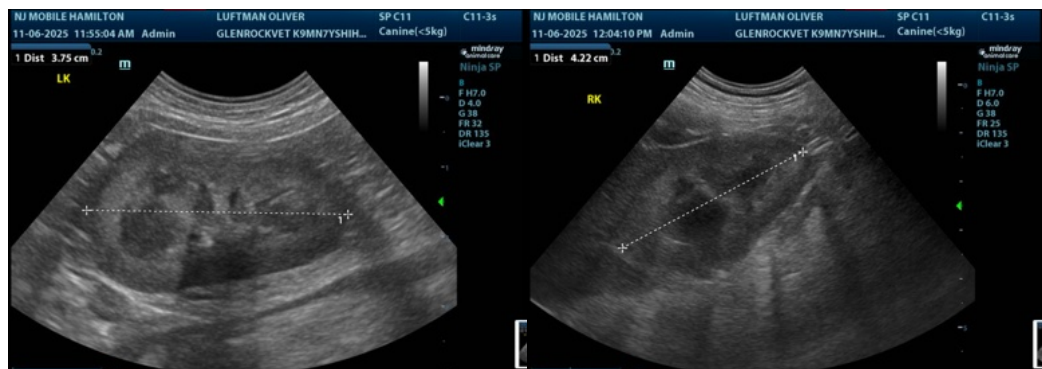
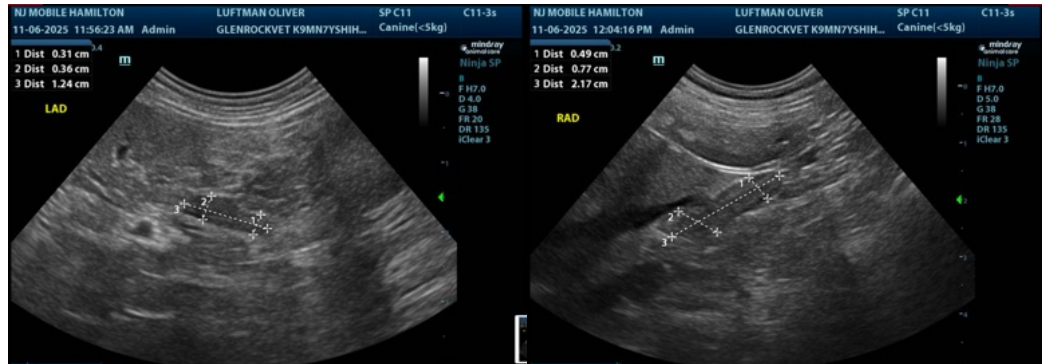
Dr. Stekler

**INVOICE**

68397

**DATE**

11/6/25





**PATIENT**

Oliver Luftman

**SPECIES**

Canine

**BREED**

Shih Tzu

**SEX**

Neutered male

**AGE**

7 years

**WEIGHT**

11.8 lbs

**INTERPRETED BY**

Eric Lindquist, DMV  
 DABVP, Cert. IVUSS

**IMAGING PERFORMED BY**

Rebecca Hamilton

**HOSPITAL NAME**

GlenRock VH

**REFERRING VET**

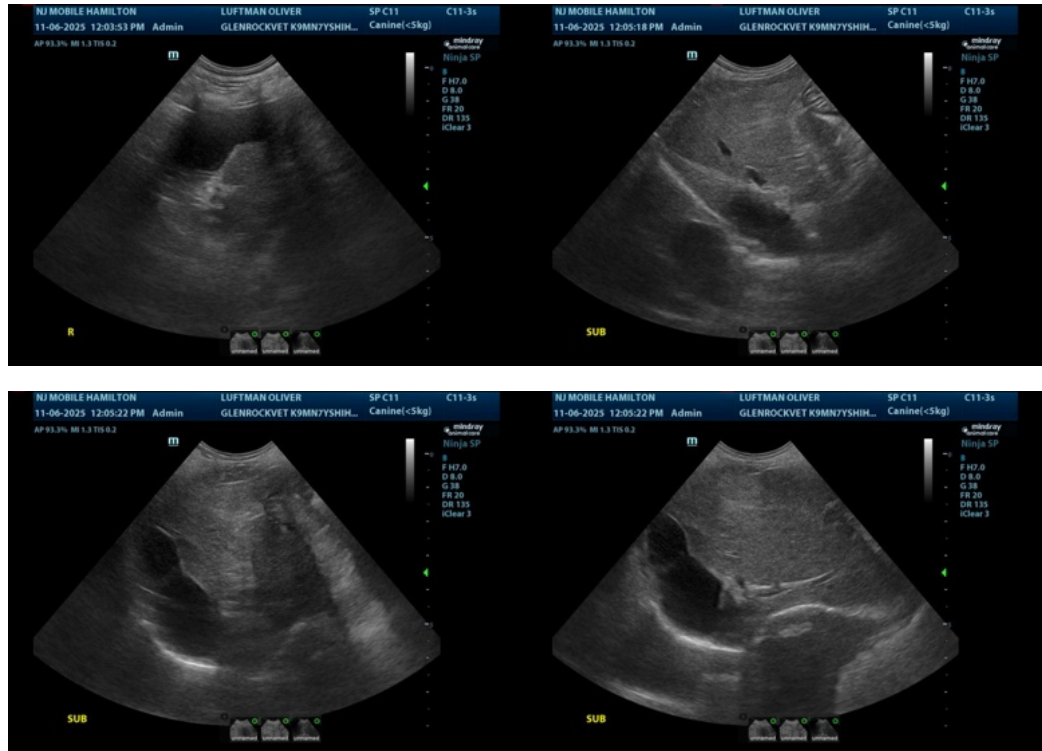
Dr. Stekler

**INVOICE**

68397

**DATE**

11/6/25



The information and recommendations provided are based on the images presented by the referring veterinarian/sonographer. No evaluation can be communicated regarding pathology that was not visible in the image/video clips provided.

Thank you for this referral. If the clinical or image interpretation does not parallel your findings or if I can be of any further assistance please contact me.

**Eric Lindquist, DMV, DABVP, Cert. IVUSS, CEO of SonoPath.com**

[info@SonoPath.com](mailto:info@SonoPath.com)