

**PATIENT**

Abby Foglio

**SPECIES**

Canine

**BREED**

Morkie

**SEX**

Spayed female

**AGE**

10 years

**WEIGHT**

13.8 lbs

**INTERPRETED BY**

Eric Lindquist, DMV,  
DABVP, Cert. IVUSS,  
CEO of SonoPath.com

**IMAGING PERFORMED BY**

Shari Reffi, CVT

**HOSPITAL NAME**

Smithfield AH

**REFERRING VET**

Dr. Boe

**INVOICE**

68395

**DATE**

11/6/25

**PRESENTING CLINICAL SIGNS**

History: Elevated T4, concern for neoplasia. Received Torb for scan.  
Free T4 >6; cTSH 0.16; BUN 33; K 3.9; NA/K 38; Alb 4; Trigs 241; CK 327

**ULTRASONOGRAPHIC EXAMINATION OF THE THYROID**

The left thyroid lobe was normal and uniform measuring 1.5 x 0.4 cm with visible parathyroids that were unremarkable and measured up to 0.25 cm. Regional tissue such as salivary gland, carotid, trachea and esophagus were all normal.

The right thyroid lobe was largely uniform, yet a hypoechoic nodule was noted and measured 0.34 cm at the mid body of the parathyroid. This is non-disruptive and not likely to be neoplastic. However, it should be monitored.

**ULTRASONOGRAPHIC FINDINGS**

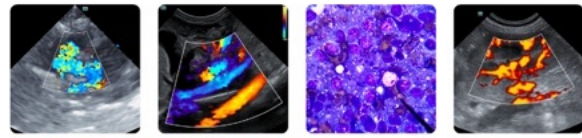
Right thyroid nodule. Parathyroid adenoma versus nodular hyperplasia is likely.

**INTERPRETATION OF THE FINDINGS & FURTHER RECOMMENDATIONS**

There is a mild potential for emerging neoplasia. This should be monitored. Ultrasound-guided FNA could be attempted. Other causes of hyperthyroidism such as ingestion of neck meat or ectopic thyroid tissue should also be considered. Chest radiographs are warranted if not already performed to assess cranial mediastinum for densities. Recheck sonogram of the right thyroid lobe is recommended in 2-3 weeks to assess for any growth of the nodule. If growth occurs either surgical removal or ultrasound-guided 25-gauge FNA would be appropriate if accessible by the sonographer.

Internal medicine consult can be utilized through Sonopath.com. You can select the internal medicine drop down at <http://spa.sonopath.com/>.

One of the world's top internists & SonoPath associate Dr. Remo Lobetti BVSc, MMedVet, PhD, DECVIM can evaluate your case through SonoPath. <https://sonopath.com/resources/sonopath-services/internal-medicine-teleconsultation-services>



**PATIENT**

Abby Foglio

**SPECIES**

Canine

**BREED**

Morkie

**SEX**

Spayed female

**AGE**

10 years

**WEIGHT**

13.8 lbs

**INTERPRETED BY**

Eric Lindquist, DMV,  
 DABVP, Cert. IVUSS,  
 CEO of SonoPath.com

**IMAGING PERFORMED BY**

Shari Reffi, CVT

**HOSPITAL NAME**

Smithfield AH

**REFERRING VET**

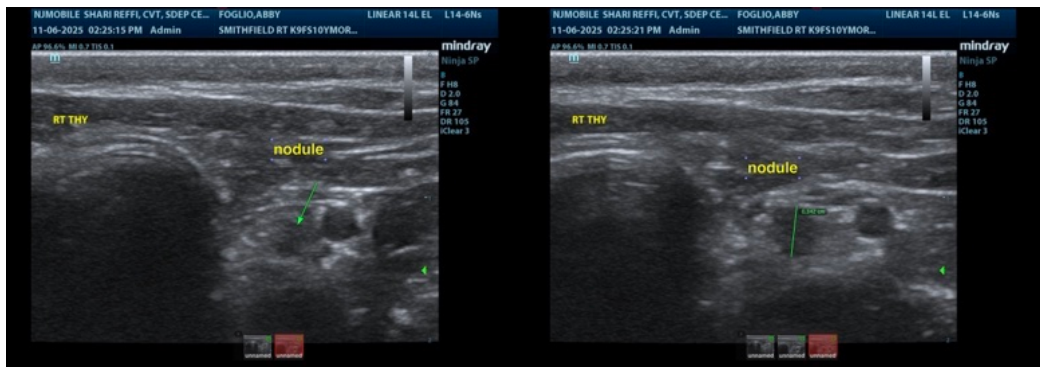
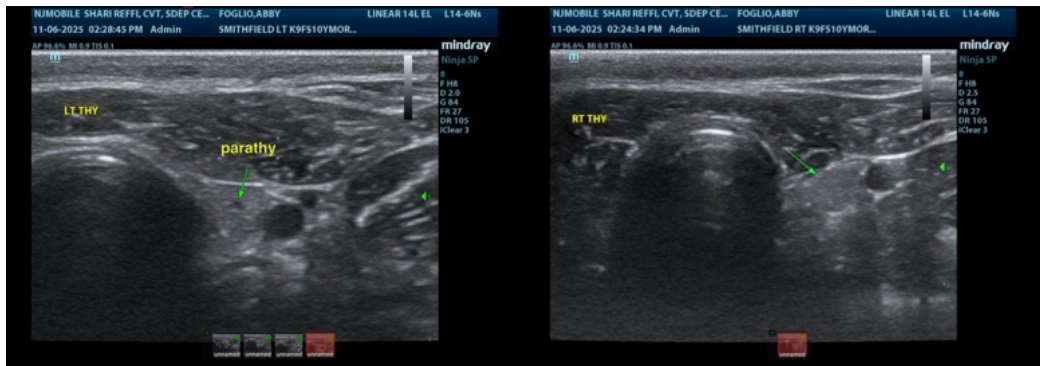
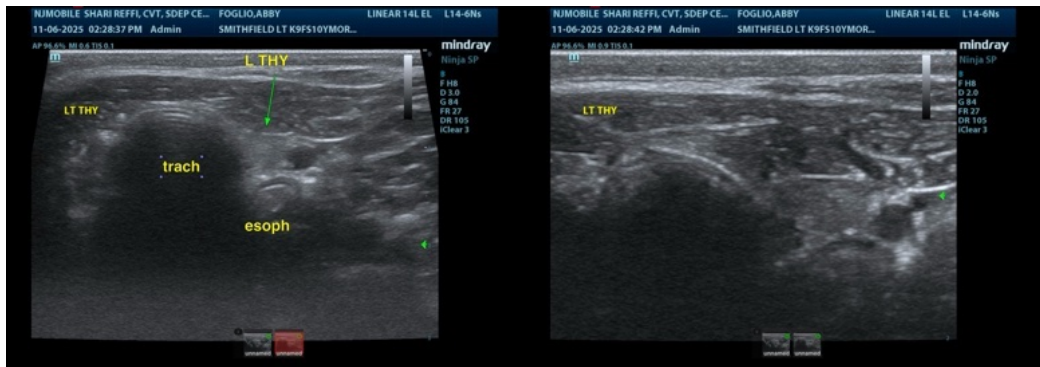
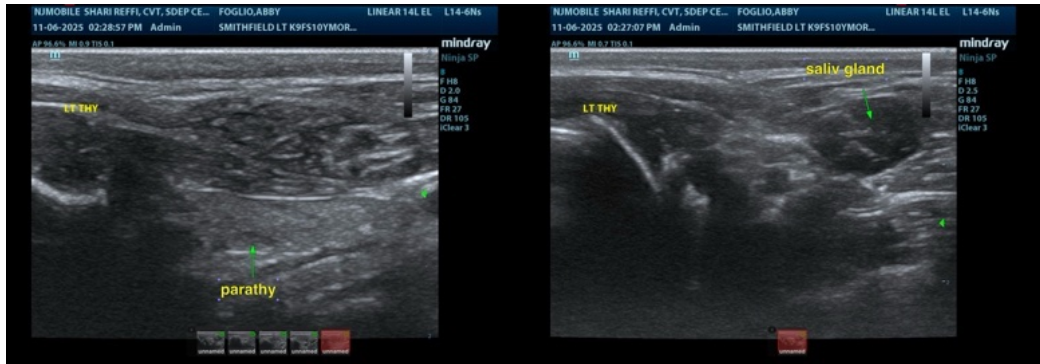
Dr. Boe

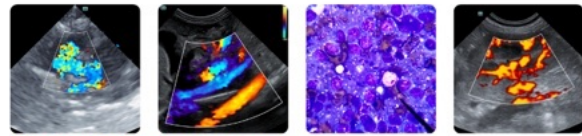
**INVOICE**

68395

**DATE**

11/6/25





**PATIENT**

Abby Foglio

**SPECIES**

Canine

**BREED**

Morkie

**SEX**

Spayed female

**AGE**

10 years

**WEIGHT**

13.8 lbs

**INTERPRETED BY**

Eric Lindquist, DMV,  
DABVP, Cert. IVUSS,  
CEO of SonoPath.com

**IMAGING PERFORMED BY**

Shari Reffi, CVT

**HOSPITAL NAME**

Smithfield AH

**REFERRING VET**

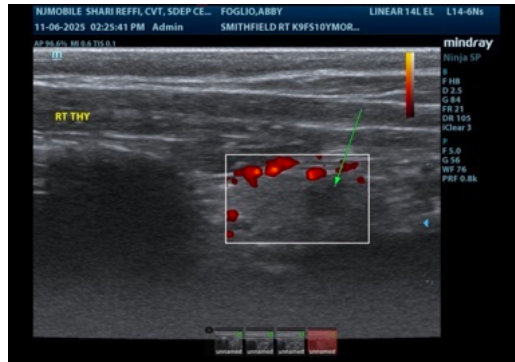
Dr. Boe

**INVOICE**

68395

**DATE**

11/6/25



The information and recommendations provided are based on the images presented by the referring veterinarian/sonographer. No evaluation can be communicated regarding pathology that was not visible in the image/video clips provided.

Thank you for this referral. If the clinical or image interpretation does not parallel your findings or if I can be of any further assistance please contact me.

Eric Lindquist, DMV, DABVP, Cert. IVUSS, CEO of SonoPath.com

[Info@SonoPath.com](mailto:Info@SonoPath.com)