



PATIENT

Kiki Carragher

SPECIES

Feline

BREED

Domestic Shorthair

SEX

Spayed female

AGE

2 year

WEIGHT

5.68 lbs

INTERPRETED BY

Eric Lindquist, DMV
DABVP, Cert. IVUSS

IMAGING PERFORMED BY

Rebecca Hamilton

HOSPITAL NAME

Verona AH

REFERRING VET

Dr. McConnell

INVOICE

68339

DATE

11/5/25

PRESENTING CLINICAL SIGNS

History: Concern for Ovarian remnant. Healthy, but signs of Estrus- yowling, vocalizing, etc.
Abnormal PE/Chem/CBC/UA Results: AMH 1.8ng/ml (spayed+ 0.01-0.16; Intact 0.27-18.9) Felv/FIV neg.

ULTRASONOGRAPHIC EXAMINATION OF THE ABDOMEN

Urinary System

The **urinary bladder**, trigone, and pelvic urethra presented normal thicknesses and normal tone. The ureters were not visible which is normal. No uroliths or sediment were visualized and anechoic urine was present. No evidence of inflammatory or neoplastic changes was noted. Ureteral papillae were normal.

The **kidneys** revealed normal size and structure, corticomedullary definition and ratio for this age. The cortices presented largely uniform texture with normal echogenic relationship to liver and spleen. Medullary structure differed distinctly from the cortex and no evidence of pelvic dilation was present. The capsules were acceptably uniform without significant irregularities. The right kidney measured 3.47 cm and the left kidney measured 3.42 cm.

The region of the left ovarian fossa revealed a 1.3 cm heterogenous structure. This is consistent with ovarian remnant with microcystic changes. The region of the right ovarian fossa was unremarkable. The uterine stump appeared quiescent measuring 0.4 cm. I cannot rule out further residual reproductive tissue and this should be examined at surgery.

Adrenal Glands

Both **adrenal glands** were visualized and recognized as having normal shape, size, position and echogenicity for this breed. The phrenic vasculature, glandular echogenicity and detail were unremarkable. Capsule, cortex, and medullary definition were normal for this age patient. The left adrenal gland measured 0.29 cm. The right adrenal gland measured 0.5 cm.

Spleen

The **spleen** presented a smooth homogeneous parenchyma hyperechoic to liver and renal cortical parenchyma. The capsule was smooth without noticeable expansion or deviation from within the spleen or adjacent pathology. The splenic vasculature demonstrated normal volume without signs of congestion or thrombosis. No sonographic evidence of acute or chronic inflammatory, neoplastic, or infarctual changes was noted.

Liver

The **liver** images submitted revealed subjectively normal liver size, contour, and structure. Parenchymal echogenicity was naturally coarse and hypoechoic to the spleen. Vascular and biliary tracts were of



PATIENT

Kiki Carragher

SPECIES

Feline

BREED

Domestic Shorthair

SEX

Spayed female

AGE

2 year

WEIGHT

5.68 lbs

INTERPRETED BY

Eric Lindquist, DMV
DABVP, Cert. IVUSS

IMAGING PERFORMED BY

Rebecca Hamilton

HOSPITAL NAME

Verona AH

REFERRING VET

Dr. McConnell

INVOICE

68339

DATE

11/5/25

normal volume with no evidence of congestion. The gallbladder presented acceptably thin walls with primarily anechoic content. The cystic and common bile ducts were normal. No pathological hepatic lymphadenopathy was evident. No overt structural evidence of inflammatory, infiltrative or regenerative pathology was evident.

Gastrointestinal

Examination of the **gastrointestinal tract** revealed a stomach and intestine free of stasis, of normal wall thickness, acceptable curvilinear mural detail, and peristaltic activity. Small and large intestine demonstrated normal luminal chyme and stool consistency respectively. No obstructive or overt infiltrative disease was noted. No associated abnormal lymphatic activity was noted.

Pancreas

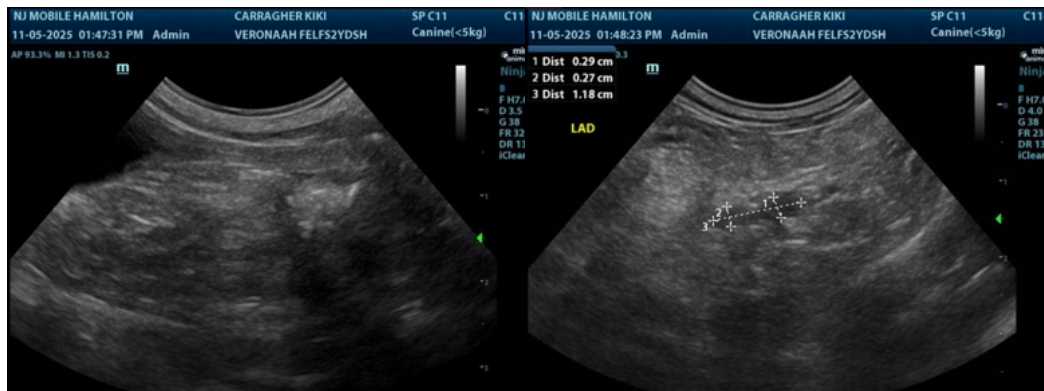
The base and limbs of the **pancreas** were observed to be largely isoechoic to surrounding omental fat. Pancreatic duct and capsular contour were acceptably normal and parenchyma respected normal curvilinear patterns. No overt evidence of active inflammatory or neoplastic disease was noted.

ULTRASONOGRAPHIC FINDINGS

Left ovarian remnant, potential residual reproductive tissue.

INTERPRETATION OF THE FINDINGS & FURTHER RECOMMENDATIONS

Surgical intervention is recommended. Given that there was no gross pathology noted. I cannot completely rule out further residual reproductive tissue should be examined at surgery.





PATIENT

Kiki Carragher

SPECIES

Feline

BREED

Domestic Shorthair

SEX

Spayed female

AGE

2 year

WEIGHT

5.68 lbs

INTERPRETED BY

Eric Lindquist, DMV
 DABVP, Cert. IVUSS

IMAGING PERFORMED BY

Rebecca Hamilton

HOSPITAL NAME

Verona AH

REFERRING VET

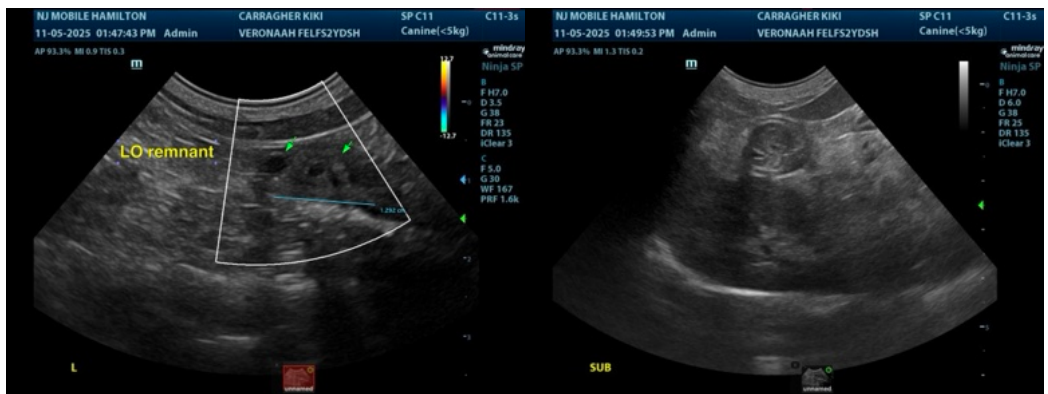
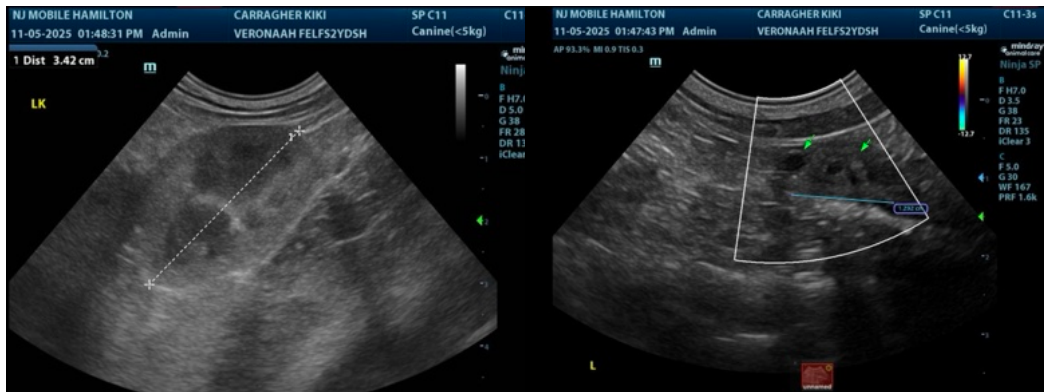
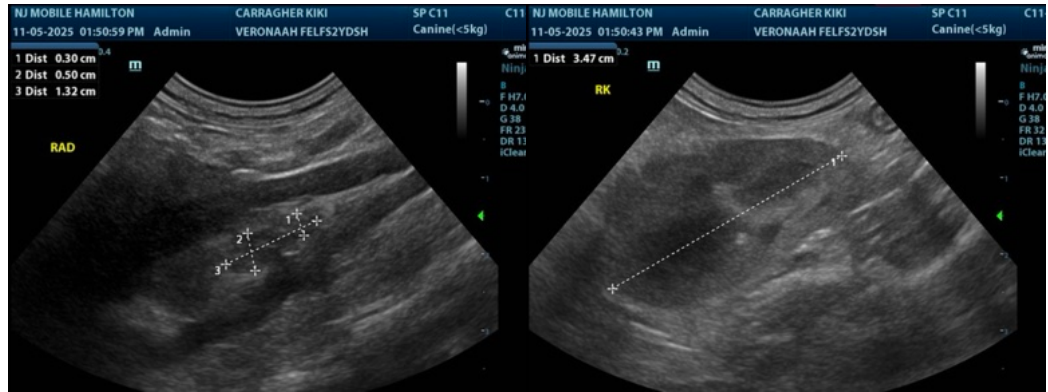
Dr. McConnell

INVOICE

68339

DATE

11/5/25





PATIENT

Kiki Carragher

SPECIES

Feline

BREED

Domestic Shorthair

SEX

Spayed female

AGE

2 year

WEIGHT

5.68 lbs

INTERPRETED BY

Eric Lindquist, DMV
 DABVP, Cert. IVUSS

IMAGING PERFORMED BY

Rebecca Hamilton

HOSPITAL NAME

Verona AH

REFERRING VET

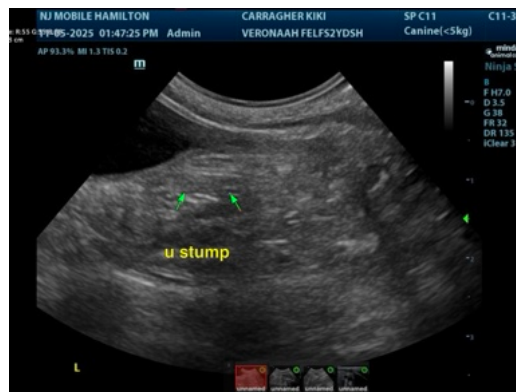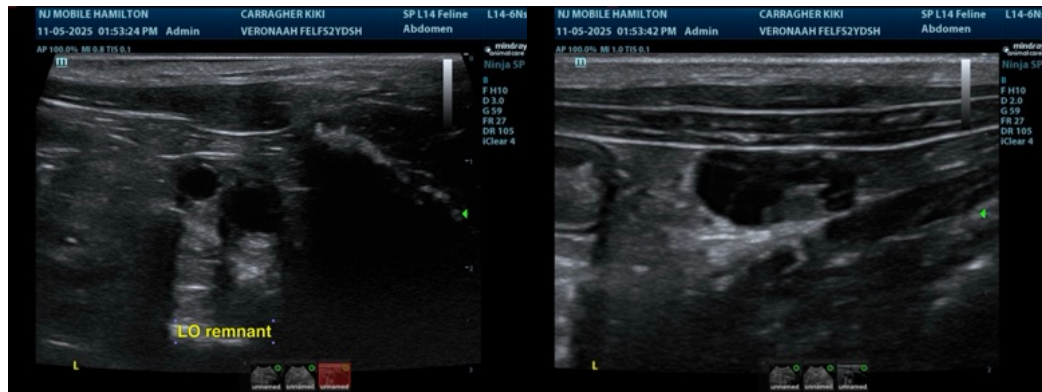
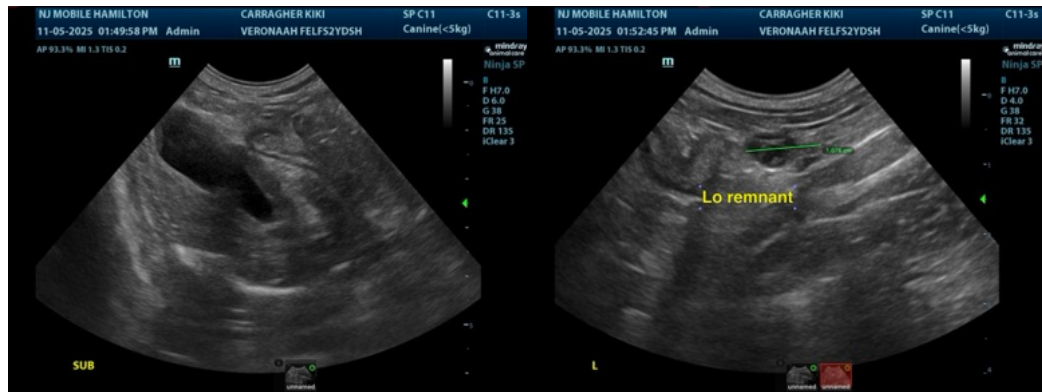
Dr. McConnell

INVOICE

68339

DATE

11/5/25



The information and recommendations provided are based on the images presented by the referring veterinarian/sonographer. No evaluation can be communicated regarding pathology that was not visible in the image/video clips provided.

Thank you for this referral. If the clinical or image interpretation does not parallel your findings or if I can be of any further assistance please contact me.

Eric Lindquist, DMV, DABVP, Cert. IVUSS, CEO of SonoPath.com

info@SonoPath.com