



PATIENT

Google Kurtz

SPECIES

Feline

BREED

Domestic Shorthair

SEX

Neutered male

AGE

14 years

WEIGHT

11.2 lbs

INTERPRETED BY

Eric Lindquist, DMV
DABVP, Cert. IVUSS

IMAGING PERFORMED BY

Rebecca Hamilton

HOSPITAL NAME

Animal Paradise
Hospital

REFERRING VET

Dr. ElShafie

INVOICE

69096

DATE

11/26/25

PRESENTING CLINICAL SIGNS

History of abnormal pro BNP. Checking for causes of weight loss
Abnormal PE/Chem/CBC/UA Results: FPL 12.5 (0.0-4.4)

ULTRASONOGRAPHIC EXAMINATION OF THE ABDOMEN

Urinary System

The **urinary bladder**, trigone, and pelvic urethra presented normal thicknesses and normal tone. The ureters were not visible which is normal. No uroliths or sediment were visualized and anechoic urine was present. No evidence of inflammatory or neoplastic changes was noted. Ureteral papillae were normal.

The **kidneys** revealed largely normal size and structure, corticomedullary definition and ratio (cortex 1/3 of medulla) were essentially maintained with some age-related loss of curvilinear patterns regarding the capsule and C/M junction. The cortices presented largely uniform texture with some increased echogenicity expected for this age patient. Medullary structure differed distinctly from that of the cortex and no evidence of pelvic dilation was present. The right kidney measured 4.07 cm and the left kidney measured 4.06 cm.

Adrenal Glands

Both **adrenal glands** were visualized and recognized as having normal shape, size, position and echogenicity for this breed. The phrenic vasculature, glandular echogenicity and detail were unremarkable. Capsule, cortex, and medullary definition were normal for this age patient. The left adrenal gland measured 0.37 cm. The right adrenal gland measured 0.37 cm.

Spleen

The **spleen** presented a smooth homogeneous parenchyma hyperechoic to liver and renal cortical parenchyma. The capsule was smooth without noticeable expansion or deviation from within the spleen or adjacent pathology. The splenic vasculature demonstrated normal volume without signs of congestion or thrombosis. No sonographic evidence of acute or chronic inflammatory, neoplastic, or infarctual changes was noted.

Liver

The **liver** images from right and left intercostal as well as subcostal views revealed subjectively normal liver size, contour, and structure. Some age-related parenchymal remodeling was noted but likely not clinically significant at this time. A cystic mass was noted in the caudal aspect of the mid liver measuring 3.8 cm. This is most consistent with biliary cystadenoma; however, separate nodular changes were noted in the left cranial liver. The left cranial nodule measured 2.4 cm. Vascular and biliary tracts were of normal volume and no evidence of congestion was noted. The gallbladder presented some dependent debris with essentially normal contour. The cystic and common bile ducts were normal. No overt



PATIENT

Google Kurtz

evidence of active inflammatory, infiltrative or regenerative pathology was noted but should be paired with current or past LE elevations regarding any clinical significance to this presentation. The hepatic lymph nodes were unremarkable.

SPECIES

Feline

Gastrointestinal

BREED

Domestic Shorthair

The **gastrointestinal tract** revealed minor variable thickening and echogenic submucosal changes most consistent with low grade end result of chronic GI disease such as IBD and may be related to malassimilation of nutrients if any weight loss is present. No obvious neoplastic patterns were noted and luminal content as unremarkable.

SEX

Neutered male

Pancreas

AGE

14 years

The **pancreas** was enlarged, irregular and hypoechoic with swollen contour. Subxiphoid palpation is recommended. The pancreas measured up to 1.2 cm in width.

WEIGHT

11.2 lbs

ULTRASONOGRAPHIC EXAMINATION OF THE HEART

INTERPRETED BY

Eric Lindquist, DMV
DABVP, Cert. IVUSS

The echocardiogram in this patient demonstrated normal **left atrial** size based on 3 separate LA measurements. **Mitral** valve insufficiency was noted and measured 5.0 m/sec. The **left ventricle** presented normal thicknesses with linear contour and was not dilated nor restricted. The **myocardium** presented normal echogenicity without subjective evidence of significant fibrotic or ischemic disease. **Contractility** of the ventricular walls was adequate and in normal range for this patient evidenced by the fractional shortening measurement and subjective evaluation of the different regions and angles of the myocardium. The **left ventricular outflow** tract demonstrated normal laminar flow and subjective structural integrity. The **right atrium** and auricle revealed normal size, structure and content. No evidence of masses was noted or chamber overload. **Tricuspid** valvular assessment demonstrated adequate linear morphology and kinetics. The **right ventricle** was of normal size (1/3 diameter of LV), chordae structure, myocardial echogenicity and thickness. **Pulmonic** tract assessment revealed normal valve structure, laminar flow, and diameter (approx. 1:1 pa/ao ratio). No visible **pericardial** or free pleura fluid was noted or extra cardiac pathology in the visible planes. The cranial **mediastinum and pericardial regions** were free of masses in the visible window.

IMAGING PERFORMED BY

Rebecca Hamilton

HOSPITAL NAME

Animal Paradise
Hospital

REFERRING VET

Dr. ElShafie

INVOICE

69096

DATE

11/26/25



PATIENT
 Google Kurtz

SPECIES
 Feline

BREED
 Domestic Shorthair

SEX
 Neutered male

AGE
 14 years

FELINE CARDIAC PARAMETERS	BODY WEIGHT (kg)	HR (BPM)	IVSd (cm)	LVIDd (cm)	LVWd (cm)	FS (%)	EF (%)
NORMAL PARAMETER	-----	150-240	0.3-0.6	1.0-2.1	0.25-0.6	35-67	80-100
PATIENT	11.2 lbs	93	0.47	1.9	0.47	51	85
FELINE CARDIAC PARAMETERS	LA/AO (M-mode)	LA/AO HEART BASE (Sisson)	LAD LA MAX 4 Chamber		LVOT VEL. (m/s)	RVOT VEL. (m/s)	IVRT (m/)
NORMAL PARAMETER	<1.5	1.6	0.7-1.7		<1.6	<1.3	40-60
PATIENT	1.48		1.3		1.0	0.84	NM
Adapted from June Boon, Veterinary Echocardiography, 1998 Sisson D et al. JVIM 1991; 5: 232, Jacobs et al. Am J Vet Res 1985; 46:1705							

WEIGHT
 11.2 lbs

ULTRASONOGRAPHIC FINDINGS

Cystic hepatic mass in the caudal abdomen and left cranial liver nodule. Biliary carcinoma is possible. The hepatic changes may be incidental.
 Compensated mitral insufficiency. Otherwise, normal echocardiogram.

INTERPRETED BY
 Eric Lindquist, DMV
 DABVP, Cert. IVUSS

INTERPRETATION OF THE FINDINGS & FURTHER RECOMMENDATIONS

The cystic mass impinged upon the portal vein. Ultrasound-guided FNA of the parenchymal portion of the mass can be considered or exploratory surgery to assess the ability to resect. I recommend focusing further diagnostics on the liver as to the level of malignancy of the hepatic pathology. Maldigestion panel and chest radiographs are warranted if not already performed.

IMAGING PERFORMED BY
 Rebecca Hamilton

There is no contraindication to anesthetic procedure.

HOSPITAL NAME
 Animal Paradise
 Hospital

Maldigestion panel, three view chest radiographs and full CNS examination is recommended to examine for occult disease that could be responsible for the weight loss. Evaluation for competitive eating environments should also be considered.

REFERRING VET
 Dr. ElShafie

INVOICE
 69096

DATE
 11/26/25



PATIENT

Google Kurtz

SPECIES

Feline

BREED

Domestic Shorthair

SEX

Neutered male

AGE

14 years

WEIGHT

11.2 lbs

INTERPRETED BY

Eric Lindquist, DMV
 DABVP, Cert. IVUSS

IMAGING PERFORMED BY

Rebecca Hamilton

HOSPITAL NAME

Animal Paradise
 Hospital

REFERRING VET

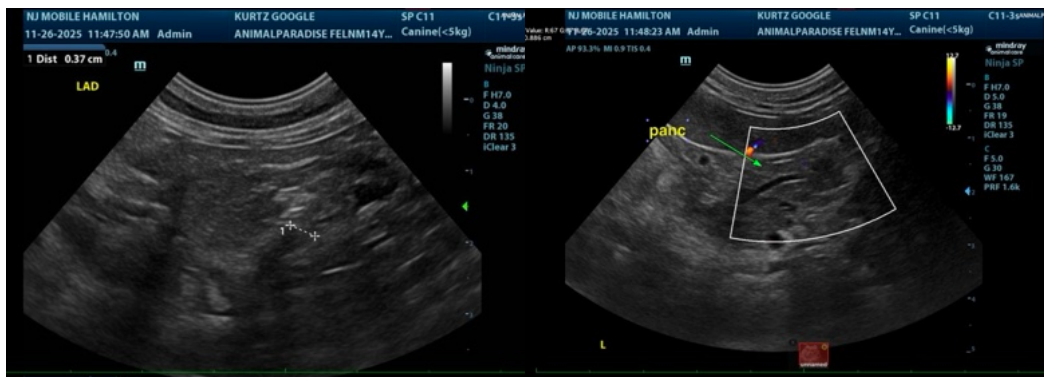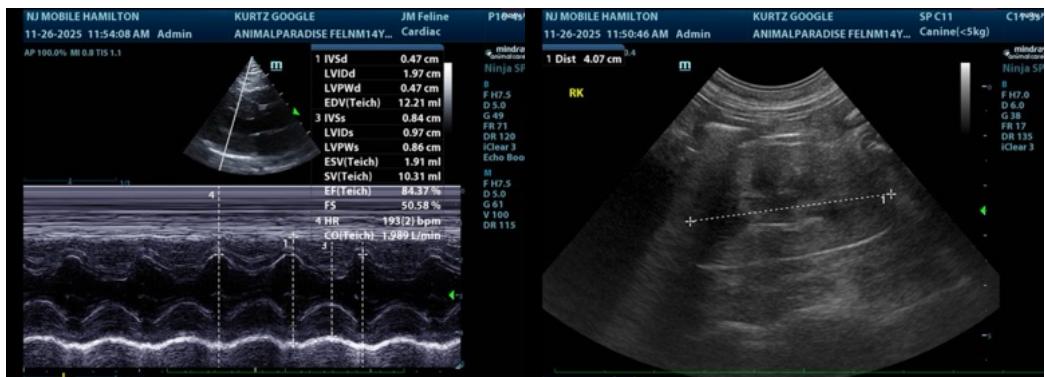
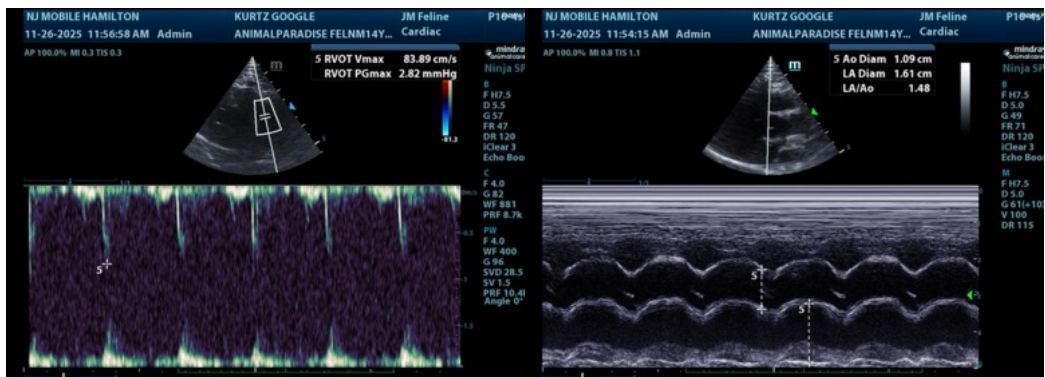
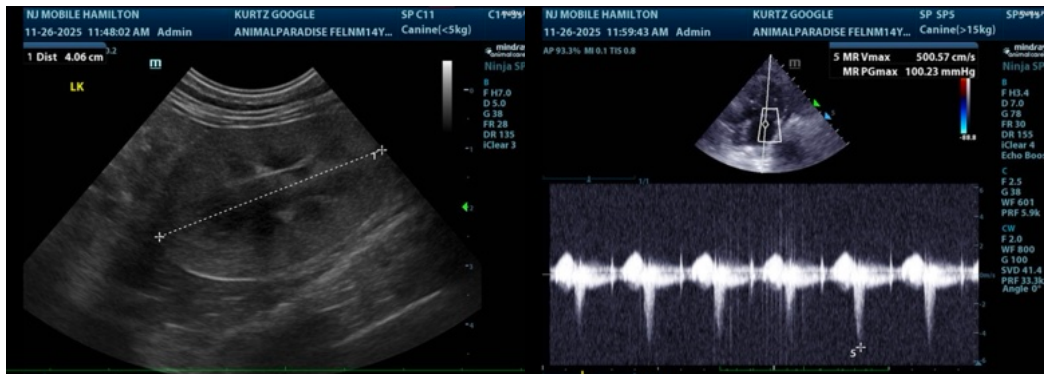
Dr. ElShafie

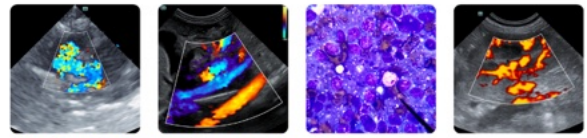
INVOICE

69096

DATE

11/26/25





PATIENT

Google Kurtz

SPECIES

Feline

BREED

Domestic Shorthair

SEX

Neutered male

AGE

14 years

WEIGHT

11.2 lbs

INTERPRETED BY

Eric Lindquist, DMV
 DABVP, Cert. IVUSS

IMAGING PERFORMED BY

Rebecca Hamilton

HOSPITAL NAME

Animal Paradise
 Hospital

REFERRING VET

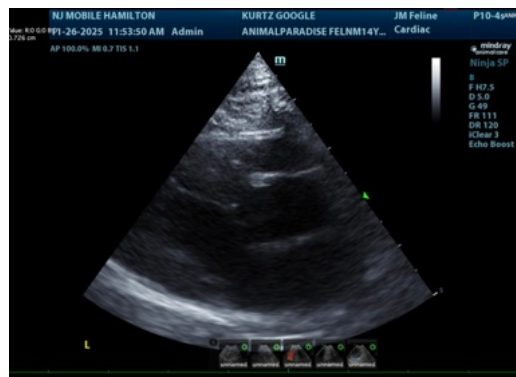
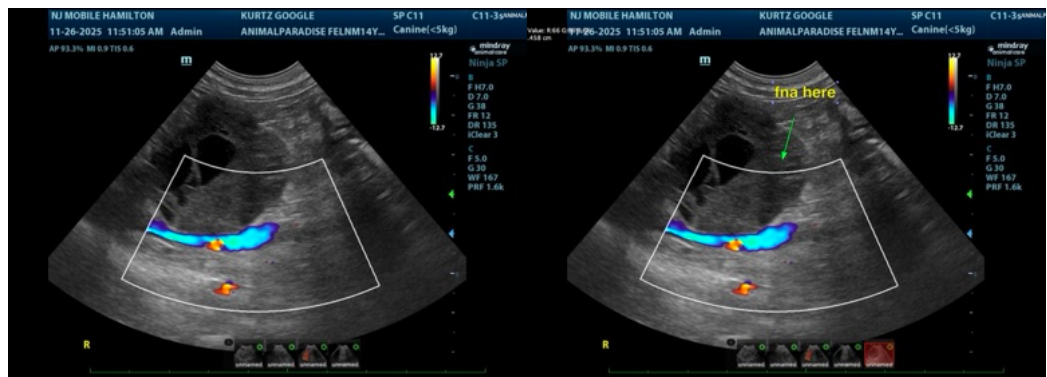
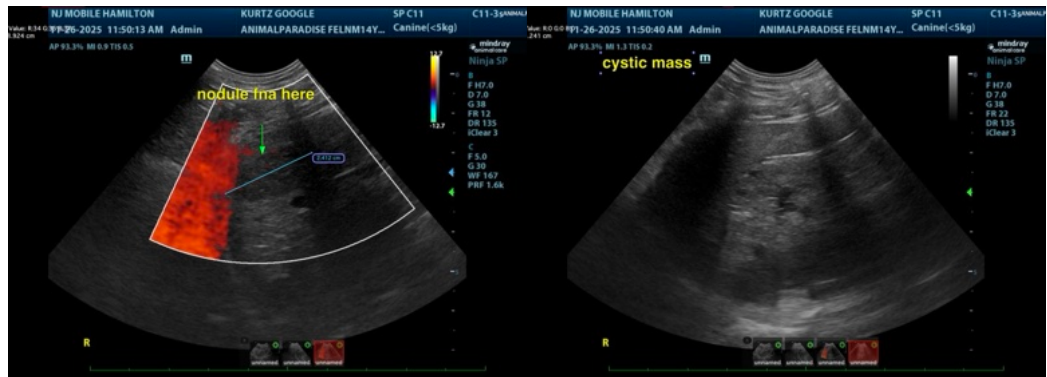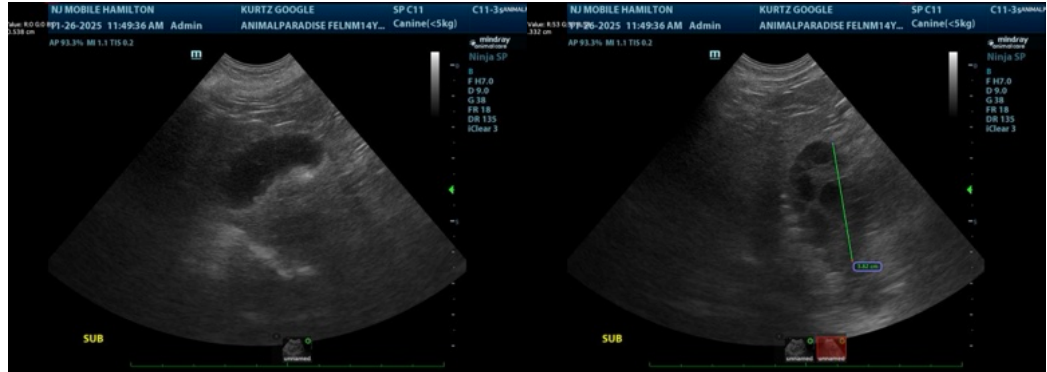
Dr. ElShafie

INVOICE

69096

DATE

11/26/25





PATIENT

Google Kurtz

The information and recommendations provided are based on the images presented by the referring veterinarian/sonographer. No evaluation can be communicated regarding pathology that was not visible in the image/video clips provided.

SPECIES

Feline

Thank you for this referral. If the clinical or image interpretation does not parallel your findings or if I can be of any further assistance please contact me.

BREED

Domestic Shorthair

Eric Lindquist, DMV, DABVP, Cert. IVUSS, CEO of SonoPath.com

info@SonoPath.com

SEX

Neutered male

AGE

14 years

WEIGHT

11.2 lbs

INTERPRETED BY

Eric Lindquist, DMV
DABVP, Cert. IVUSS

**IMAGING
PERFORMED BY**

Rebecca Hamilton

HOSPITAL NAME

Animal Paradise
Hospital

REFERRING VET

Dr. ElShafie

INVOICE

69096

DATE

11/26/25