



PATIENT

Aggie Payne

SPECIES

Canine

BREED

English Bulldog

SEX

Spayed female

AGE

11 years

WEIGHT

49.4 lbs

INTERPRETED BY

Eric Lindquist, DMV,
DABVP, Cert. IVUSS,
CEO of SonoPath.com

IMAGING PERFORMED BY

Meghan Morse, LVT,
CVT

HOSPITAL NAME

Narrowsburg
Veterinary

REFERRING VET

Dr. Hess

INVOICE

69110

DATE

11/26/25

PRESENTING CLINICAL SIGNS

History: Recurrent UTI, responds to antibiotic tx, no response to incurin, cultured- no resistant bacteria No current meds

Abnormal PE/Chem/CBC/UA Results: Increased SAP, UTI

ULTRASONOGRAPHIC EXAMINATION OF THE ABDOMEN

Urinary System

The **urinary bladder** was unremarkable for the level of repletion presented. The bladder wall was thickened. The urethra revealed poor tone. The pelvic urethra was uniformly dilated measuring up to 0.8 cm, suspect underlying incontinence. The urine, however, did present some mildly echogenic debris consistent with mucous, exfoliated cells from renal or bladder origin, and/or blood clots as these echogenic changes can all present similarly. This is often related to urinary tract infection but may represent simple evidence of exfoliated debris or sterile inflammation. Cystocentesis, urinalysis, +/- culture would be recommended to rule out and define any UTI.

The **kidneys** revealed largely normal size and structure, corticomedullary definition and ratio (cortex 1/3 of medulla) were essentially maintained with some age-related loss of curvilinear patterns regarding the capsule and C/M junction. The cortices presented largely uniform texture with some increased echogenicity expected for this age patient. Medullary structure differed distinctly from that of the cortex. The left kidney measured 5.9 cm with pelvic calculus measuring 1.8 cm. The right kidney measured 5.55 cm.

Adrenal Glands

Both **adrenal glands** were visualized and recognized as having largely normal shape, size, position and acceptable echogenicity for this age group and breed. Some heterogeneity was noted within the adrenal parenchyma without concerning capsular distortion. These changes are likely age related but should be monitored by sonogram should the patient be suspected of having adrenal disease. The left adrenal gland measured 2.63 x 0.48 cm at the caudal pole and 0.48 cm at the cranial pole. The right adrenal gland measured 2.63 x 1.13 cm at the cranial pole and 0.67 cm at the caudal pole.

Spleen

The **spleen** presented a smooth homogeneous parenchyma hyperechoic to liver and renal cortical parenchyma. The capsule was smooth without noticeable expansion or deviation from within the spleen or adjacent pathology. The splenic vasculature demonstrated normal volume without signs of congestion or thrombosis. No sonographic evidence of acute or chronic inflammatory, neoplastic, or infarctual changes was noted.



PATIENT

Aggie Payne

SPECIES

Canine

BREED

English Bulldog

SEX

Spayed female

AGE

11 years

WEIGHT

49.4 lbs

INTERPRETED BY

Eric Lindquist, DMV,
DABVP, Cert. IVUSS,
CEO of SonoPath.com

IMAGING PERFORMED BY

Meghan Morse, LVT,
CVT

HOSPITAL NAME

Narrowsburg
Veterinary

REFERRING VET

Dr. Hess

INVOICE

69110

DATE

11/26/25

Liver

The **liver** images submitted revealed subjectively normal liver size, contour, and structure. Parenchymal echogenicity was naturally coarse and hypoechoic to the spleen. Vascular and biliary tracts were of normal volume with no evidence of congestion. The gallbladder presented acceptably thin walls with primarily anechoic content. The cystic and common bile ducts were normal. No pathological hepatic lymphadenopathy was evident. No overt structural evidence of inflammatory, infiltrative or regenerative pathology was evident.

Gastrointestinal

Examination of the **gastrointestinal tract** revealed a stomach and intestine free of stasis, of normal wall thickness, acceptable curvilinear mural detail, and peristaltic activity. Small and large intestine demonstrated normal luminal chyme and stool consistency respectively. No obstructive or overt infiltrative disease was noted. No associated abnormal lymphatic activity was noted.

Pancreas

The base and limbs of the **pancreas** were observed to be largely isoechoic to surrounding omental fat. Pancreatic duct and capsular contour were acceptably normal and parenchyma respected normal curvilinear patterns. No overt evidence of active inflammatory or neoplastic disease was noted.

ULTRASONOGRAPHIC FINDINGS

Poor urethral tone.

Bladder debris.

Nephrolithiasis and moderate chronic degenerative changes.

INTERPRETATION OF THE FINDINGS & FURTHER RECOMMENDATIONS

Multiple factors may be playing a role in the clinical history of this patient. Embedded and/or resistant bacteria and renal changes with nephrolithiasis, chronic bladder wall changes may also be harboring infection as well as poor urethral tone may also be playing a role in the recurrent UTI. Assessment of the vaginal vestibule for predisposing issues. Chronic UTI management is indicated. A 4-6 week protocol is likely necessary with Phenylpropanolamine or other urethral enhancement measures. The kidneys appear 40-50% compromised. Blood pressure measurements are also indicated if not already performed.

Canine Chronic UTI Protocol

To be utilized for UTI with chronic urinary tract changes found sonographically that may serve as nidus of infection and history of chronic or recurrent UTI is an issue.

I recommend Clavamox as a first level approach to chronic UTI at 12.5-25 mg/kg bid owing to optimal urinary concentrations. If bacterial resistance is an issue then **Enrofloxacin** (5-10 mg/kg SID PO) (In patients > 1 year of age) in late pm after urination to maximize urinary concentrations overnight. This



PATIENT

Aggie Payne

SPECIES

Canine

BREED

English Bulldog

SEX

Spayed female

AGE

11 years

WEIGHT

49.4 lbs

INTERPRETED BY

Eric Lindquist, DMV,
 DABVP, Cert. IVUSS,
 CEO of SonoPath.com

IMAGING PERFORMED BY

Meghan Morse, LVT,
 CVT

HOSPITAL NAME

Narrowsburg
 Veterinary

REFERRING VET

Dr. Hess

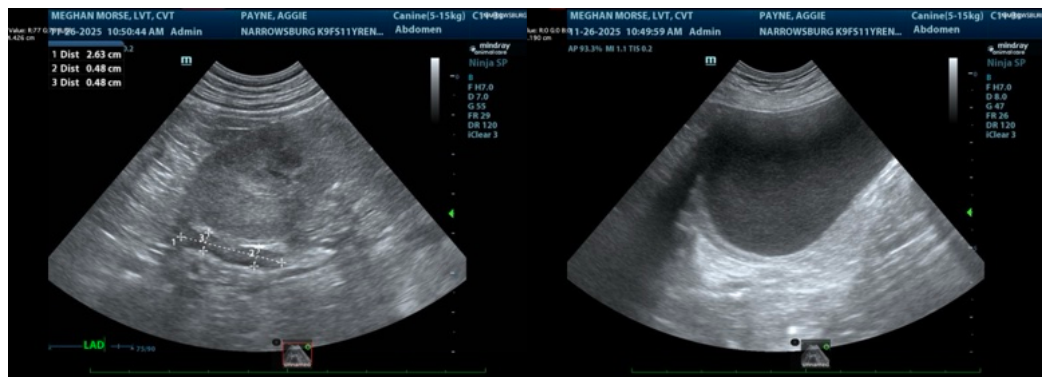
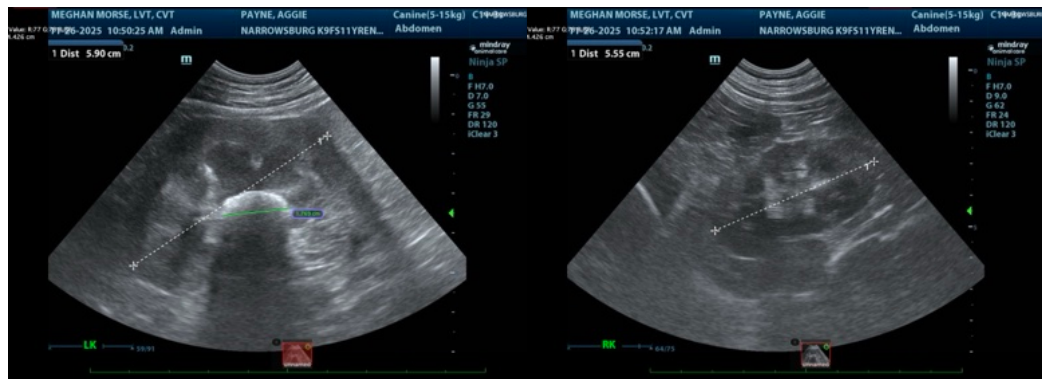
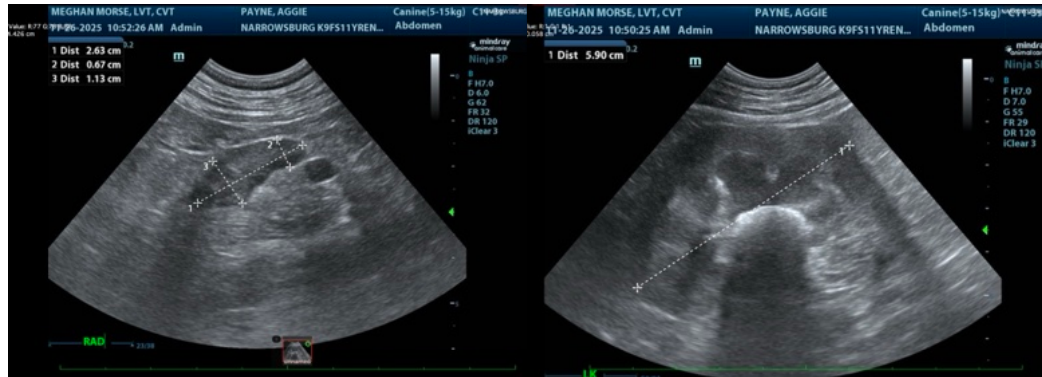INVOICE

69110

DATE

11/26/25

assumes that culture supports this use. Repeat **culture** at 3-4 weeks and continue treatment at least 7-10 days post negative urinary sediment and negative culture. *Note: Negative culture does not necessarily mean lack of UTI.* Other favorite antibiotics for chronic UTI include third generation Cefa (Ceftiafur or similar s.i.d. injectable) or Clavamox. If suspicion of occult urinary incontinence is present then **phenylpropanolamine (PPA)** (1-2 mg/kg BID) can be employed long term to enhance urethral tone.





PATIENT

Aggie Payne

SPECIES

Canine

BREED

English Bulldog

SEX

Spayed female

AGE

11 years

WEIGHT

49.4 lbs

INTERPRETED BY

Eric Lindquist, DMV,
 DABVP, Cert. IVUSS,
 CEO of SonoPath.com

IMAGING PERFORMED BY

Meghan Morse, LVT,
 CVT

HOSPITAL NAME

Narrowsburg
 Veterinary

REFERRING VET

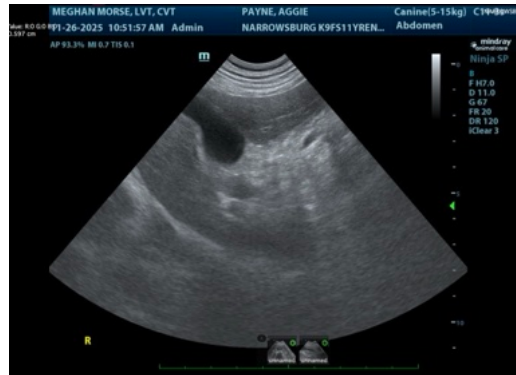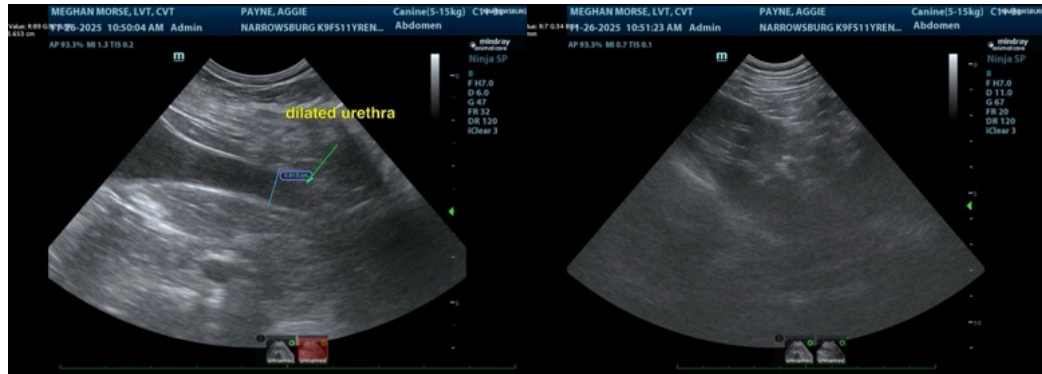Dr. Hess

INVOICE

69110

DATE

11/26/25



The information and recommendations provided are based on the images presented by the referring veterinarian/sonographer. No evaluation can be communicated regarding pathology that was not visible in the image/video clips provided.

Thank you for this referral. If the clinical or image interpretation does not parallel your findings or if I can be of any further assistance please contact me.

Eric Lindquist, DMV, DABVP, Cert. IVUSS, CEO of SonoPath.com

Info@SonoPath.com