



**PATIENT**

Watson Karl Race

**SPECIES**

Canine

**BREED**

English Bulldog

**SEX**

Intact male

**AGE**

3 years

**WEIGHT**

76.8 lbs

**INTERPRETED BY**

Eric Lindquist, DMV,  
 DABVP, Cert. IVUSS,  
 CEO of SonoPath.com

**IMAGING PERFORMED BY**

Meghan Morse, LVT,  
 CVT

**HOSPITAL NAME**

Dr. T VC

**REFERRING VET**

Dr. Turk-Reiger

**INVOICE**

68958

**DATE**

11/24/25

**PRESENTING CLINICAL SIGNS**

History: Excessive panting, exercise intolerance, lameness right hind, some inappetence and bloating with weight gain. Current meds: Levofloxacin, Ophthalmic antihistamine  
 Abnormal PE/Chem/CBC/UA Results: 7/2/25: CBC, Chem, T4/ free T4, U/A, fecal and accuplex ALL WNL

**ULTRASONOGRAPHIC EXAMINATION OF THE HEART**

The echocardiogram in this patient demonstrated normal **left atrial** size based on 3 separate methods of LA evaluation. Trivial **mitral** valve insufficiency was noted in this patient, this is not clinically significant. The **left ventricle** presented thicknesses with linear contour and was not dilated nor restricted. The **myocardium** presented normal echogenicity without subjective evidence of significant fibrotic or ischemic disease. **Contractility** of the ventricular walls was adequate and in normal range for this patient evidenced by the fractional shortening measurement and subjective evaluation of the different regions of the myocardium. The **left ventricular outflow** tract demonstrated normal laminar flow and subjective structural integrity. The **right atrium** and auricle revealed normal size, structure and content. No evidence of masses was noted. **Tricuspid** valvular assessment demonstrated adequate linear morphology and kinesis. The **right ventricle** was of normal size (1/3 diameter of LV), chordae structure, myocardial echogenicity and thickness. **Pulmonary outflow** tract assessment revealed normal valve structure, laminar flow, and diameter (approx. 1:1 pa/ao ratio). No visible **pericardial** or free pleura fluid was noted. The cranial **mediastinum and pericardial and extra-cardiac regions** were free of masses in the visible window.

CANINE CARDIAC PARAMETERS	MR VMAX (m/s)	TR VMAX (m/s)	LA/AO	LA/AO (Heart Base)	FS (%)	EF (%)	EPSS (cm)
NORMAL PARAMETER	4.5-5.5	<2.7	1.3	<1.6	28-40	40-100	<0.6
PATIENT			1.14	1.2	46	79	NM
CANINE CARDIAC PARAMETERS	HR (BPM)	AV VMAX (m/s)	PV MAX (m/s)	BODY WEIGHT	LA 2D short axis Base view (cm)	LVIDd Avg; 2D and m-mode short axis (cm)	LVIDs Avg; 2D and m-mode short axis (cm)
NORMAL PARAMETER	50-100	0.7-1.7	0.7-1.6	BELOW	BELOW	BELOW	BELOW
PATIENT		1.77	1.11	76.8 lbs		3.33	



## PATIENT

Watson Karl Race

## SPECIES

Canine

## BREED

English Bulldog

## SEX

Intact male

## AGE

3 years

## WEIGHT

76.8 lbs

## INTERPRETED BY

Eric Lindquist, DMV,  
DABVP, Cert. IVUSS,  
CEO of SonoPath.com

## IMAGING PERFORMED BY

Meghan Morse, LVT,  
CVT

## HOSPITAL NAME

Dr. T VC

## REFERRING VET

Dr. Turk-Reiger

## INVOICE

68958

## DATE

11/24/25

## ULTRASONOGRAPHIC EXAMINATION OF THE ABDOMEN

### *Urinary System*

The **urinary bladder**, trigone, and pelvic urethra presented normal thicknesses and normal tone. The ureters were not visible which is normal. No uroliths or sediment were visualized and anechoic urine was present. No evidence of inflammatory or neoplastic changes was noted. Ureteral papillae were normal.

The **kidneys** were largely normal; however, some irregularity noted to the left renal contour. This is likely a normal variant; however, some level of primary renal dysplasia is possible, yet the changes were minor. The right kidney measured 6.13 cm. The left kidney measured 6.63 cm.

The **prostate** was uniform and measured 2.9 cm with no evidence of pathology.

### *Adrenal Glands*

Both **adrenal glands** were visualized and recognized as having normal shape, size, position and echogenicity for this breed. The phrenic vasculature, glandular echogenicity and detail were unremarkable. Capsule, cortex, and medullary definition were normal for this age patient. The right adrenal gland measured 0.6 cm. The left adrenal gland measured 2.06 x 0.48 cm at the cranial pole and 0.63 cm at the caudal pole.

### *Spleen*

The **spleen** presented a smooth homogeneous parenchyma hyperechoic to liver and renal cortical parenchyma. The capsule was smooth without noticeable expansion or deviation from within the spleen or adjacent pathology. The splenic vasculature demonstrated normal volume without signs of congestion or thrombosis. No sonographic evidence of acute or chronic inflammatory, neoplastic, or infarctual changes was noted.

### *Liver*

The **liver** images submitted revealed subjectively normal liver size, contour, and structure. Parenchymal echogenicity was naturally coarse and hypoechoic to the spleen. Vascular and biliary tracts were of normal volume with no evidence of congestion. The gallbladder presented acceptably thin walls with primarily anechoic content. The cystic and common bile ducts were normal. No pathological hepatic lymphadenopathy was evident. No overt structural evidence of inflammatory, infiltrative or regenerative pathology was evident.

### *Gastrointestinal*

Examination of the **gastrointestinal tract** revealed a stomach and intestine free of stasis, of normal wall thickness, acceptable curvilinear mural detail, and peristaltic activity. Small and large intestine demonstrated normal luminal chyme and stool consistency respectively. No obstructive or overt infiltrative disease was noted. No associated abnormal lymphatic activity was noted.



**PATIENT**

Watson Karl Race

**SPECIES**

Canine

**BREED**

English Bulldog

**SEX**

Intact male

**AGE**

3 years

**WEIGHT**

76.8 lbs

**INTERPRETED BY**

Eric Lindquist, DMV,  
 DABVP, Cert. IVUSS,  
 CEO of SonoPath.com

**IMAGING PERFORMED BY**

Meghan Morse, LVT,  
 CVT

**HOSPITAL NAME**

Dr. T VC

**REFERRING VET**

Dr. Turk-Reiger

**INVOICE**

68958

**DATE**

11/24/25

**Pancreas**

The base and limbs of the **pancreas** were observed to be largely isoechoic to surrounding omental fat. Pancreatic duct and capsular contour were acceptably normal and parenchyma respected normal curvilinear patterns. No overt evidence of active inflammatory or neoplastic disease was noted.

**ULTRASONOGRAPHIC FINDINGS**

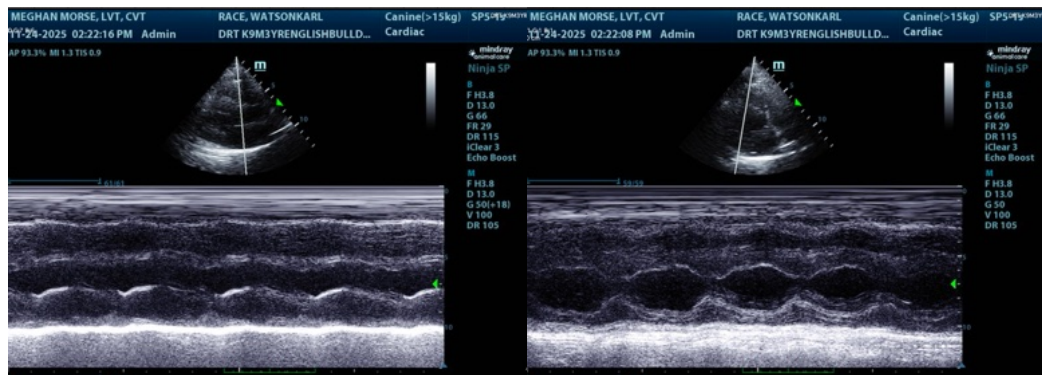
Normal echocardiogram with trivial mitral insufficiency, stage B1 valvular disease.

Idiopathic irregularity to the left kidney, possibly minor form of renal dysplasia or normal variant. Not clinically significant as long as the renal values are unremarkable.

**INTERPRETATION OF THE FINDINGS & FURTHER RECOMMENDATIONS**

There was no evidence of clinical cardiac disease in this patient; however, I cannot rule out arrhythmogenic disease. Holter monitor would be ideal to rule out arrhythmogenic disease associated with the clinical signs.

The cause of the clinical signs is not evident in this patient. I recommend assessing for orthopedic pain, thoracic disease, CNS disease or occult arrhythmogenic disease which would necessitate a Holter monitor, which may be obtained from our office. Obstructive respiratory disease may also be playing a role given the breed.





**PATIENT**

Watson Karl Race

**SPECIES**

Canine

**BREED**

English Bulldog

**SEX**

Intact male

**AGE**

3 years

**WEIGHT**

76.8 lbs

**INTERPRETED BY**

Eric Lindquist, DMV,  
 DABVP, Cert. IVUSS,  
 CEO of SonoPath.com

**IMAGING PERFORMED BY**

Meghan Morse, LVT,  
 CVT

**HOSPITAL NAME**

Dr. T.V.C

**REFERRING VET**

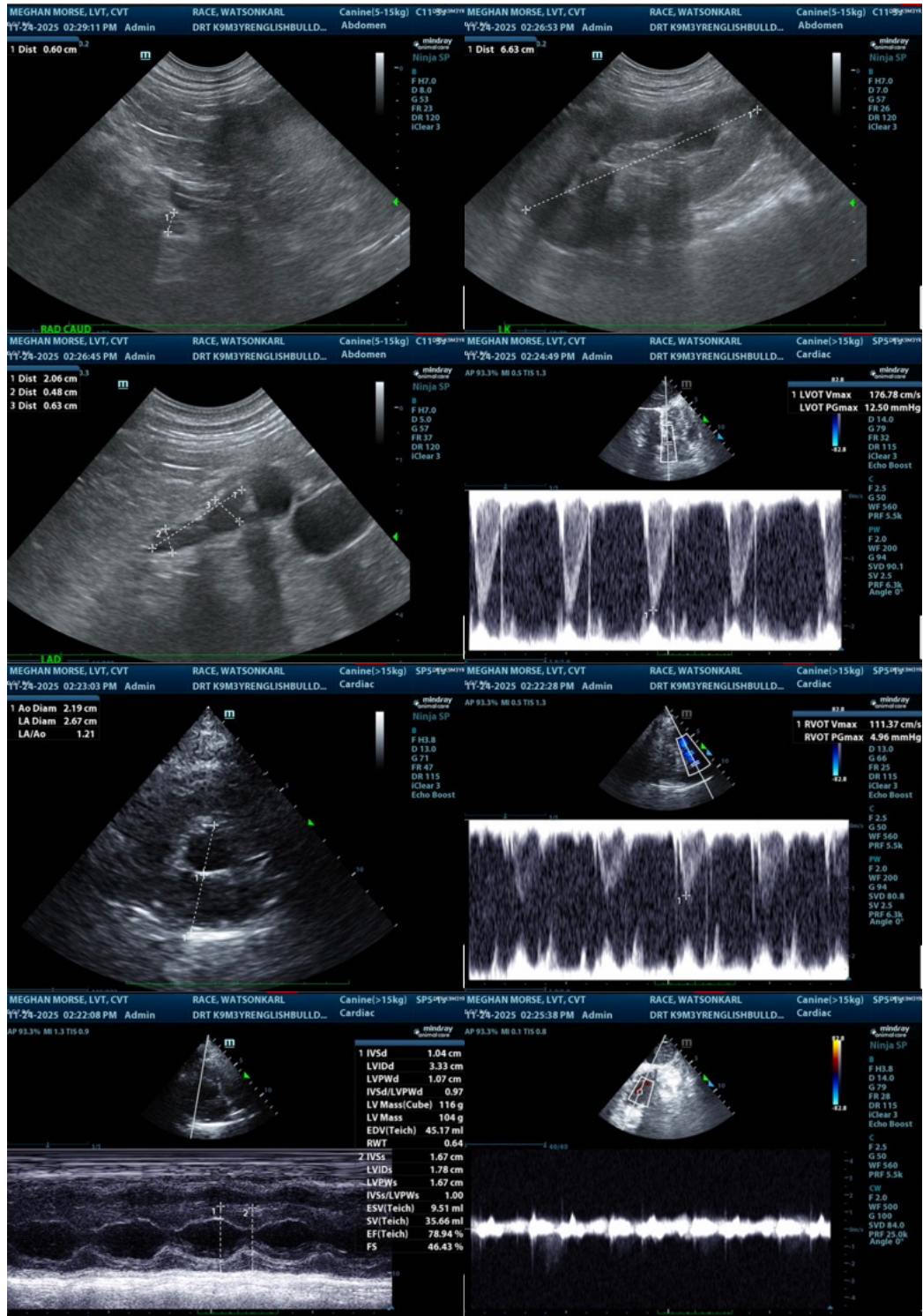
Dr. Turk-Reiger

**INVOICE**

68958

**DATE**

11/24/25





**PATIENT**

Watson Karl Race

**SPECIES**

Canine

**BREED**

English Bulldog

**SEX**

Intact male

**AGE**

3 years

**WEIGHT**

76.8 lbs

**INTERPRETED BY**

Eric Lindquist, DMV,  
 DABVP, Cert. IVUSS,  
 CEO of SonoPath.com

**IMAGING PERFORMED BY**

Meghan Morse, LVT,  
 CVT

**HOSPITAL NAME**

Dr. T.V.C

**REFERRING VET**

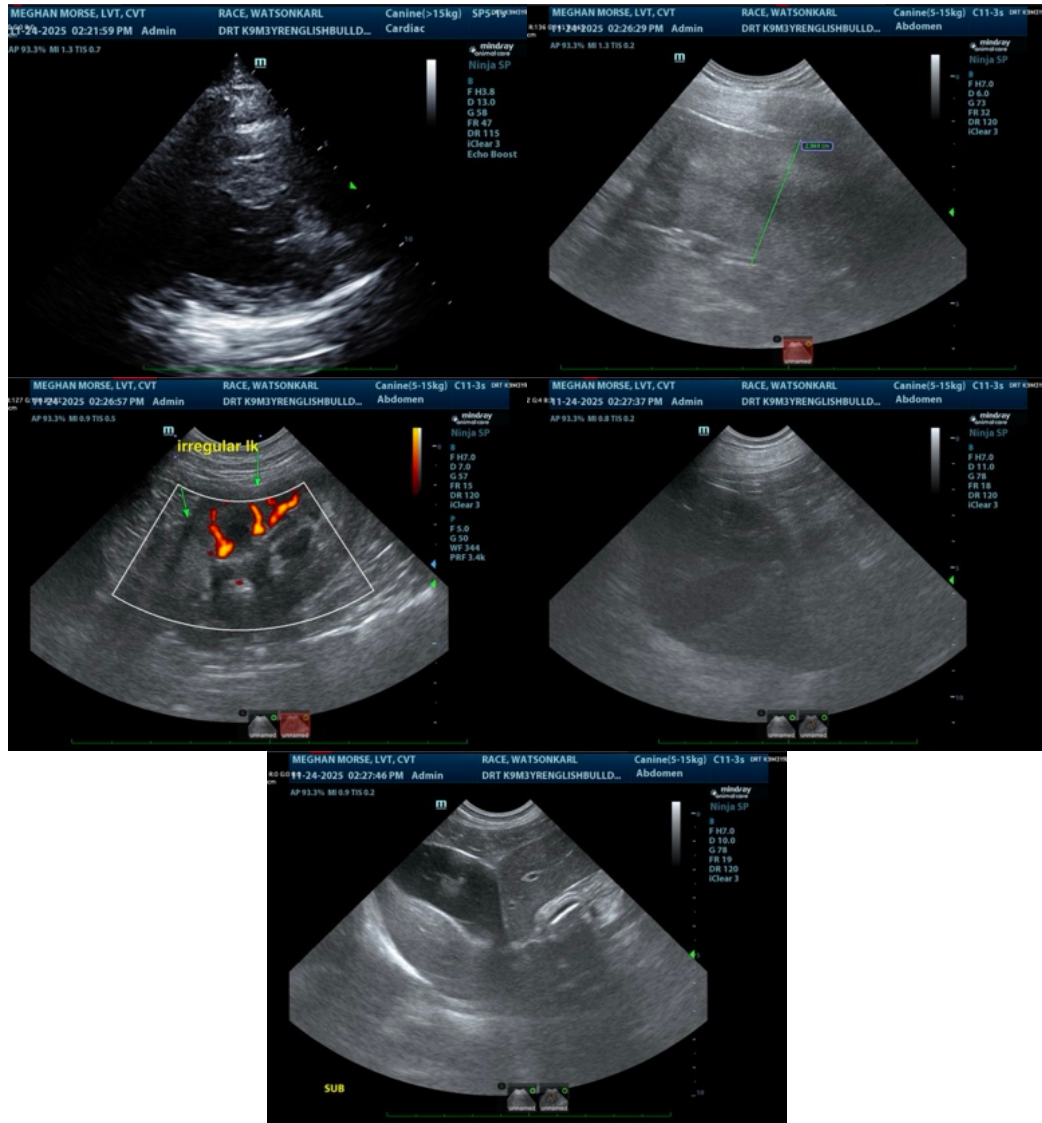
Dr. Turk-Reiger

**INVOICE**

68958

**DATE**

11/24/25



The information and recommendations provided are based on the images presented by the referring veterinarian/sonographer. No evaluation can be communicated regarding pathology that was not visible in the image/video clips provided.

Thank you for this referral. If the clinical or image interpretation does not parallel your findings or if I can be of any further assistance please contact me.

Eric Lindquist, DMV, DABVP, Cert. IVUSS, CEO of SonoPath.com

Info@SonoPath.com