



PATIENT

Vanillachai Speer

SPECIES

Feline

BREED

Siamese

SEX

Female

AGE

7 months

WEIGHT

7.8 lbs

PRESENTING CLINICAL SIGNS

History: R/o abd. mass. Distended abd, possible abd. mass palpated, uri signs- nasal discharge, sneezing, conjunctivitis. Treating coccidia. Clavamox, erythromycin ophthalmic.
Abnormal PE/Chem/CBC/UA Results: Running today.

ULTRASONOGRAPHIC EXAMINATION OF THE ABDOMEN

Urinary System

The **urinary bladder**, trigone, and pelvic urethra presented normal thicknesses and normal tone. The ureters were not visible which is normal. No uroliths or sediment were visualized and anechoic urine was present. No evidence of inflammatory or neoplastic changes was noted. Ureteral papillae were normal.

The **kidneys** revealed normal size and structure, corticomedullary definition and ratio for this age. The cortices presented largely uniform texture with normal echogenic relationship to liver and spleen. Medullary structure differed distinctly from the cortex and no evidence of pelvic dilation was present. The capsules were acceptably uniform without significant irregularities.

Positive pregnancy was noted in this patient with multiple fetuses, at least 2 live fetuses. One measured 4.25 cm live fetus. The amniotic sac presented anechoic fluid and normal wall thicknesses. The pregnancy is approximately 50-55 days.

INTERPRETED BY

Eric Lindquist, DMV,
DABVP (CFM), Cert.
IVUSS, CEO of
SonoPath.com

Adrenal Glands

Both **adrenal glands** were visualized and recognized as having normal shape, size, position and echogenicity for this breed. The phrenic vasculature, glandular echogenicity and detail were unremarkable. Capsule, cortex, and medullary definition were normal for this age patient.

IMAGING PERFORMED BY

Kerri Becker

HOSPITAL NAME

Packanack AH

REFERRING VET

Dr. Gonzaga

Spleen

The **spleen** presented a smooth homogeneous parenchyma hyperechoic to liver and renal cortical parenchyma. The capsule was smooth without noticeable expansion or deviation from within the spleen or adjacent pathology. The splenic vasculature demonstrated normal volume without signs of congestion or thrombosis. No sonographic evidence of acute or chronic inflammatory, neoplastic, or infarctual changes was noted.

Liver

The **liver** images submitted revealed subjectively normal liver size, contour, and structure. Parenchymal echogenicity was naturally coarse and hypoechoic to the spleen. Vascular and biliary tracts were of normal volume with no evidence of congestion. The gallbladder presented acceptably thin walls with primarily anechoic content. The cystic and common bile ducts were normal. No pathological hepatic lymphadenopathy was evident. No overt structural evidence of inflammatory, infiltrative or regenerative pathology was evident.

INVOICE

68940

DATE

11/24/25



PATIENT

Vanillachai Speer

SPECIES

Feline

BREED

Siamese

SEX

Female

AGE

7 months

WEIGHT

7.8 lbs

INTERPRETED BY

Eric Lindquist, DMV,
DABVP (CFM), Cert.
IVUSS, CEO of
SonoPath.com

IMAGING PERFORMED BY

Kerri Becker

HOSPITAL NAME

Packanack AH

REFERRING VET

Dr. Gonzaga

INVOICE

68940

DATE

11/24/25

Gastrointestinal

Examination of the **gastrointestinal tract** revealed a stomach and intestine free of stasis, of normal wall thickness, acceptable curvilinear mural detail, and peristaltic activity. Small and large intestine demonstrated normal luminal chyme and stool consistency respectively. No obstructive or overt infiltrative disease was noted. No associated abnormal lymphatic activity was noted.

Pancreas

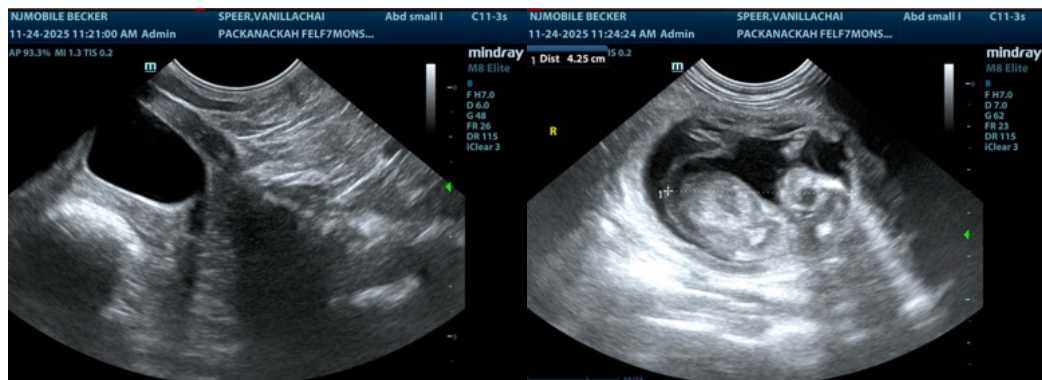
The base and limbs of the **pancreas** were observed to be largely isoechoic to surrounding omental fat. Pancreatic duct and capsular contour were acceptably normal and parenchyma respected normal curvilinear patterns. No overt evidence of active inflammatory or neoplastic disease was noted.

ULTRASONOGRAPHIC FINDINGS

Live pregnancy, approximately 50-55 days of gestation.

INTERPRETATION OF THE FINDINGS & FURTHER RECOMMENDATIONS

Approximately 2 live fetuses. However, fetal count is best performed with radiographs. There was no evidence of pathology.





PATIENT

Vanillachai Speer

SPECIES

Feline

BREED

Siamese

SEX

Female

AGE

7 months

WEIGHT

7.8 lbs

INTERPRETED BY

Eric Lindquist, DMV,
 DABVP (CFM), Cert.
 IVUSS, CEO of
 SonoPath.com

IMAGING PERFORMED BY

Kerri Becker

HOSPITAL NAME

Packanack AH

REFERRING VET

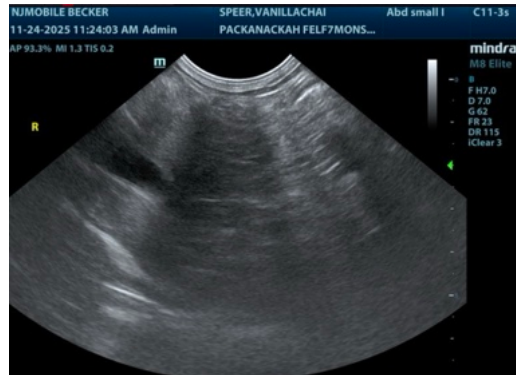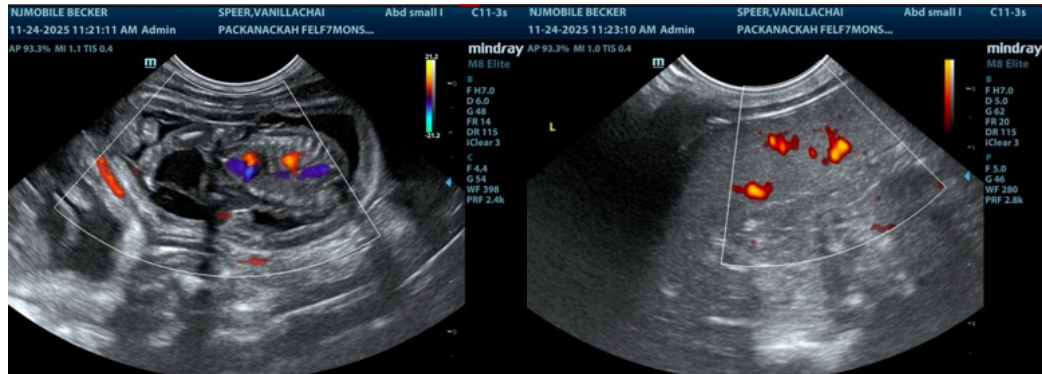
Dr. Gonzaga

INVOICE

68940

DATE

11/24/25



The information and recommendations provided are based on the images presented by the referring veterinarian/sonographer. No evaluation can be communicated regarding pathology that was not visible in the image/video clips provided.

Thank you for this referral. If the clinical or image interpretation does not parallel your findings or if I can be of any further assistance please contact me.

Eric Lindquist, DMV, DABVP (CFM), Cert. IVUSS, CEO of SonoPath.com

Info@SonoPath.com