



PATIENT

Austin Ozerova

SPECIES

Canine

BREED

Kelly Blue Terrier

SEX

Intact male

AGE

12 years

WEIGHT

31.8 lbs

INTERPRETED BY

Eric Lindquist, DMV,
DABVP, Cert. IVUSS,
CEO of SonoPath.com

IMAGING PERFORMED BY

Meghan Morse, LVT,
CVT

HOSPITAL NAME

Bergen County VC

REFERRING VET

Dr. Moore

INVOICE

68802

DATE

11/18/25

PRESENTING CLINICAL SIGNS

History: V+, D+ w/ blood droplets, lethargy, recurrent signs from 3 wks ago Current meds: none- just finished 17d course of enrofloxacin and zofran

CBC: HCT 65.5, RBC 9.26, HGB 20.8, MCHC 31.8, Baso 0.16 Chem: TP 8.4, Glob 5.3, ALb 3.1, ALT 138

ULTRASONOGRAPHIC EXAMINATION OF THE ABDOMEN

Urinary System

The **urinary bladder**, trigone, and pelvic urethra presented normal thicknesses and normal tone. The ureters were not visible which is normal. No uroliths or sediment were visualized and anechoic urine was present. No evidence of inflammatory or neoplastic changes was noted. Ureteral papillae were normal.

The **kidneys** revealed largely normal size and structure, corticomedullary definition and ratio (cortex 1/3 of medulla) were essentially maintained with some age-related loss of curvilinear patterns regarding the capsule and C/M junction. The cortices presented largely uniform texture with some increased echogenicity expected for this age patient. Medullary structure differed distinctly from that of the cortex and no evidence of pelvic dilation was present. The right kidney measured 6.4 cm. The left kidney measured 6.1 cm.

The **prostate** was uniformly enlarged with lobar swelling appeared to impinge upon the urethra and mildly deviate the descending colon. Microcystic changes were noted in the prostate measuring up to 1.0 cm. The prostatic tissue was hyperechoic containing focal areas of decreased echogenicity. These changes are suggestive of either chronic inflammatory episodes, benign cystic pathology or both. Underlying neoplasia cannot be completely ruled-out but is lower on the differential list. This presentation is most consistent with benign prostatic hyperplasia with possible active prostatitis. Neutering or off-label Finasteride (Propecia) (0.1-0.5 mg/kg Sid) treatment is indicated +/- FNA or prostatic wash cytology and culture.

The right testicle was subnormal in size, yet uniform measuring 1.6 cm. The left testicle was normal in size and contour measuring 3.3 cm. The epididymis were unremarkable.

The iliac trifurcation was unremarkable.

Adrenal Glands

Both **adrenal glands** were visualized and recognized as having largely normal shape, size, position and acceptable echogenicity for this age group and breed. Some heterogeneity was noted within the adrenal parenchyma without concerning capsular distortion. These changes are likely age related but should be monitored by sonogram should the patient be suspected of having adrenal disease. The left adrenal gland measured 2.2 x 0.65 cm at the cranial pole and 0.67 cm at the caudal pole. The right adrenal gland measured 2.37 x 1.05 cm at the cranial pole and 0.5 cm at the caudal pole.



PATIENT

Austin Ozerova

SPECIES

Canine

BREED

Kelly Blue Terrier

SEX

Intact male

AGE

12 years

WEIGHT

31.8 lbs

INTERPRETED BY

Eric Lindquist, DMV,
DABVP, Cert. IVUSS,
CEO of SonoPath.com

IMAGING PERFORMED BY

Meghan Morse, LVT,
CVT

HOSPITAL NAME

Bergen County VC

REFERRING VET

Dr. Moore

INVOICE

68802

DATE

11/18/25

Spleen

The **spleen** presented a smooth homogeneous parenchyma hyperechoic to liver and renal cortical parenchyma. The capsule was smooth without noticeable expansion or deviation from within the spleen or adjacent pathology. The splenic vasculature demonstrated normal volume without signs of congestion or thrombosis. No sonographic evidence of acute or chronic inflammatory, neoplastic, or infarctual changes was noted.

Liver

The **liver** images from right and left intercostal as well as subcostal views revealed subjectively normal liver size, contour, and structure. Some age-related parenchymal remodeling was noted but likely not clinically significant at this time. Vascular and biliary tracts were of normal volume and no evidence of congestion was noted. The gallbladder presented some dependent debris with essentially normal contour. The cystic and common bile ducts were normal. No overt evidence of active inflammatory, infiltrative or regenerative pathology was noted but should be paired with current or past LE elevations regarding any clinical significance to this presentation. The hepatic lymph nodes were unremarkable.

Gastrointestinal

Examination of the **gastrointestinal tract** revealed a stomach and intestine free of stasis, of normal wall thickness, acceptable curvilinear mural detail, and peristaltic activity. Small and large intestine demonstrated normal luminal chyme and stool consistency respectively. The colon was empty with minor hypertrophy and a mild amount of fluid. No obstructive or overt infiltrative disease was noted. No associated abnormal lymphatic activity was noted.

Pancreas

The base and limbs of the **pancreas** were observed to be largely isoechoic to surrounding omental fat. Pancreatic duct and capsular contour were acceptably normal and parenchyma respected normal curvilinear patterns. No overt evidence of active inflammatory or neoplastic disease was noted.

ULTRASONOGRAPHIC FINDINGS

Incidental BPH prostate with cysts.

Hypoplastic right testicle. There was no evidence of tumors.

Possible concurrent GI upset or colitis.

INTERPRETATION OF THE FINDINGS & FURTHER RECOMMENDATIONS

Dietary indiscretion, food intolerance, structurally significant inflammatory bowel or occult parasitism and occult Addison's are all potentials.



PATIENT

Austin Ozerova

SPECIES

Canine

BREED

Kelly Blue Terrier

SEX

Intact male

AGE

12 years

WEIGHT

31.8 lbs

INTERPRETED BY

Eric Lindquist, DMV,
 DABVP, Cert. IVUSS,
 CEO of SonoPath.com

IMAGING PERFORMED BY

Meghan Morse, LVT,
 CVT

HOSPITAL NAME

Bergen County VC

REFERRING VET

Dr. Moore

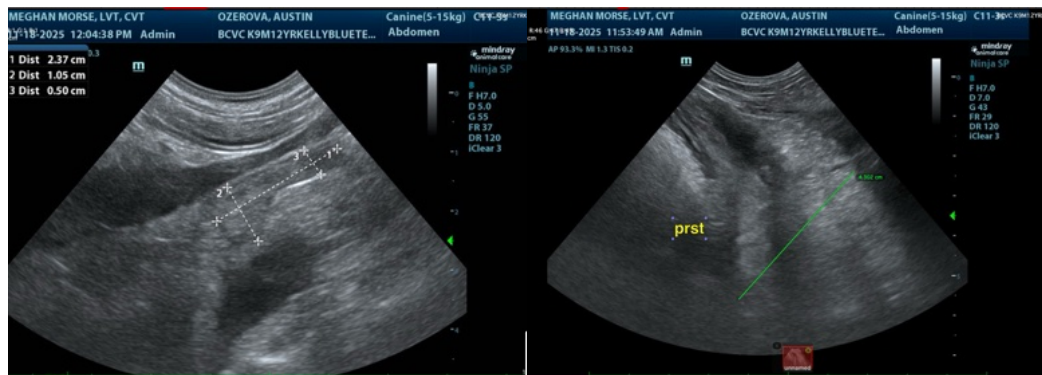
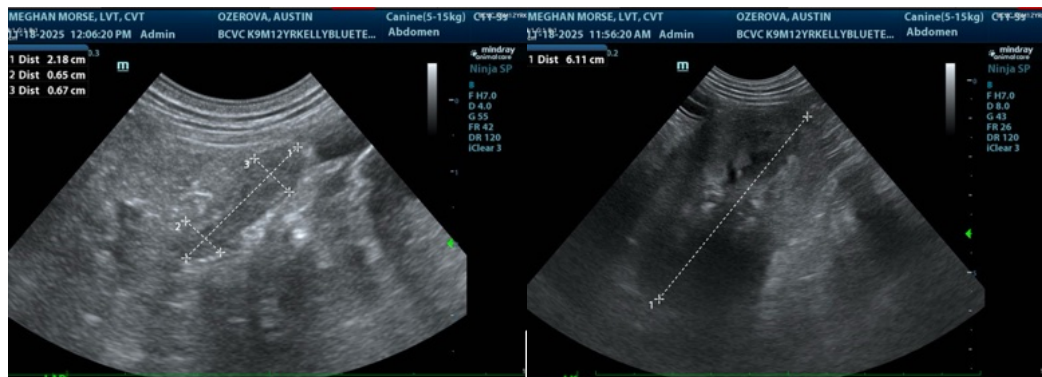
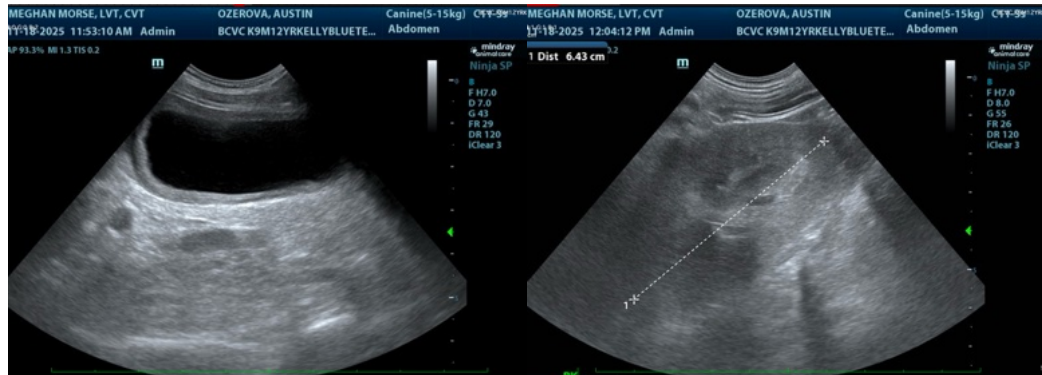
INVOICE

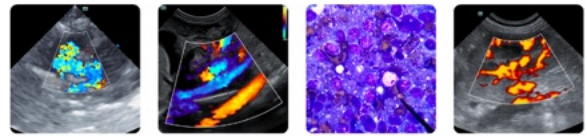
68802

DATE

11/18/25

If any signs of prostatic disease are present, then the following protocol is recommended: Finasteride at 1 mg/kg/day can be utilized as an off-label approach to reducing prostatic size in BPH cases. Coverage for prostatitis would also likely be appropriate with Fluoroquinolone/Baytril or similar. A recheck sonogram is recommended in 3-4 weeks with reassessment of the urinalysis and evaluation of any inflammatory sediment.





PATIENT

Austin Ozerova

SPECIES

Canine

BREED

Kelly Blue Terrier

SEX

Intact male

AGE

12 years

WEIGHT

31.8 lbs

INTERPRETED BY

Eric Lindquist, DMV,
 DABVP, Cert. IVUS,
 CEO of SonoPath.com

IMAGING PERFORMED BY

Meghan Morse, LVT,
 CVT

HOSPITAL NAME

Bergen County VC

REFERRING VET

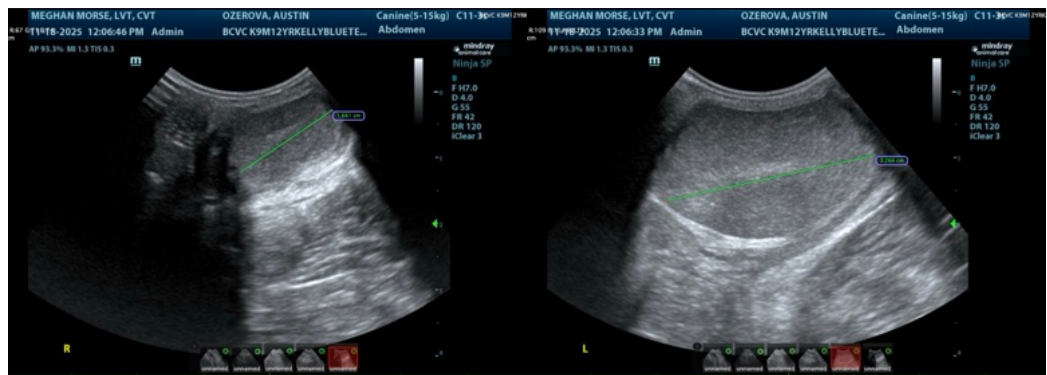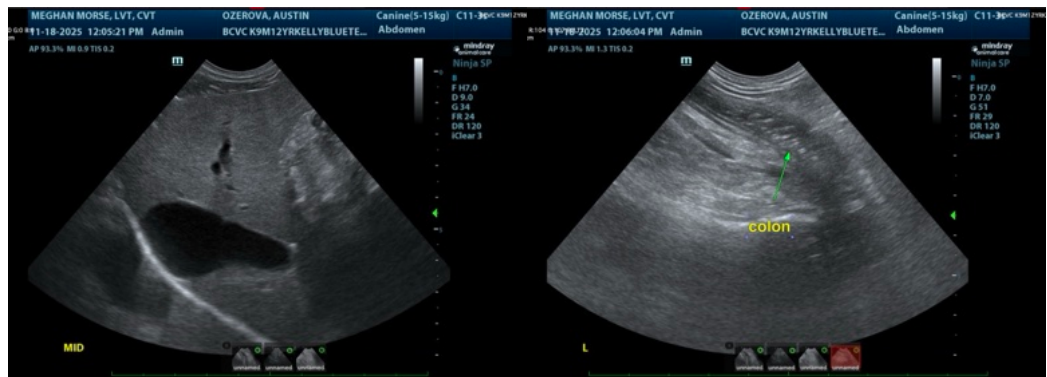
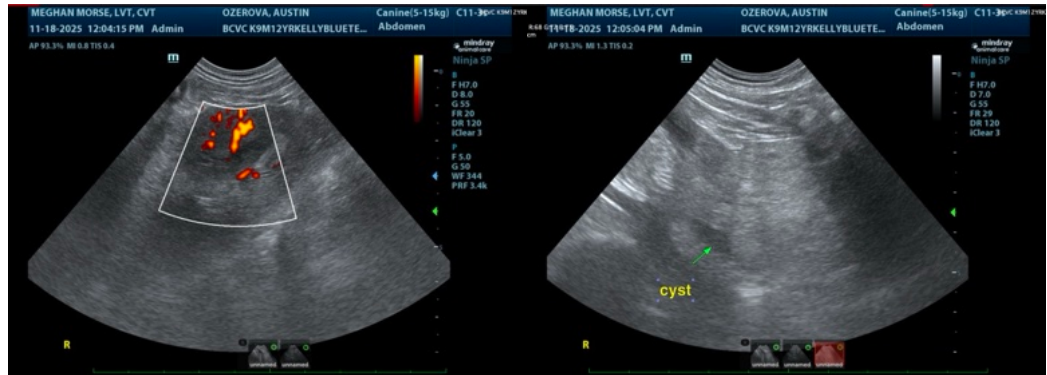
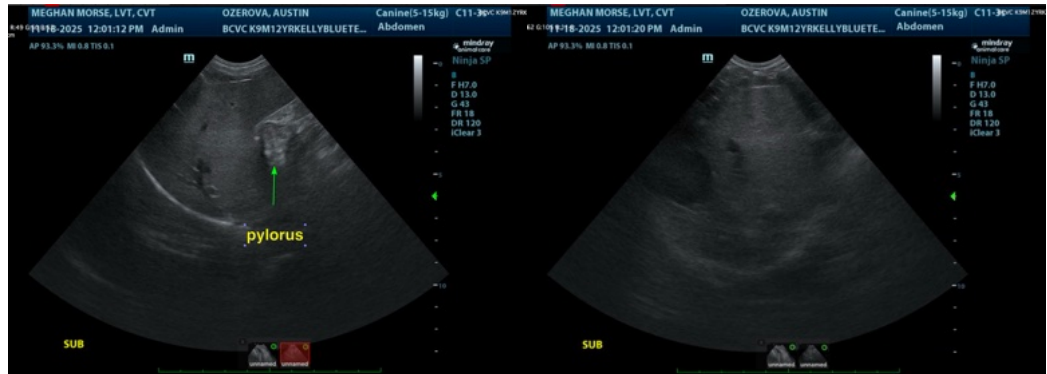
Dr. Moore

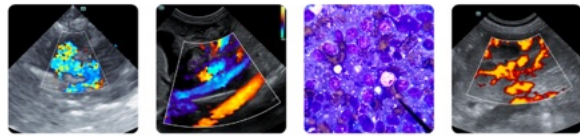
INVOICE

68802

DATE

11/18/25





PATIENT

Austin Ozerova

SPECIES

Canine

BREED

Kelly Blue Terrier

SEX

Intact male

AGE

12 years

WEIGHT

31.8 lbs

INTERPRETED BY

Eric Lindquist, DMV,
DABVP, Cert. IVUSS,
CEO of SonoPath.com

**IMAGING
PERFORMED BY**

Meghan Morse, LVT,
CVT

HOSPITAL NAME

Bergen County VC

REFERRING VET

Dr. Moore

INVOICE

68802

DATE

11/18/25

The information and recommendations provided are based on the images presented by the referring veterinarian/sonographer. No evaluation can be communicated regarding pathology that was not visible in the image/video clips provided.

Thank you for this referral. If the clinical or image interpretation does not parallel your findings or if I can be of any further assistance please contact me.

Eric Lindquist, DMV, DABVP, Cert. IVUSS, CEO of SonoPath.com

Info@SonoPath.com