



PATIENT

Toto Camp P

SPECIES

Canine

BREED

Shih Tzu

SEX

Spayed female

AGE

8 years

WEIGHT

15 lbs

INTERPRETED BY

Eric Lindquist, DMV
DABVP, Cert. IVUSS

HOSPITAL NAME

SDEP Lab

INVOICE

68703

DATE

11/15/25

PRESENTING CLINICAL SIGNS

T 99.9, HR 160, RR 40, BCS 5/9, PS 0/4, FS green

ULTRASONOGRAPHIC EXAMINATION OF THE ABDOMEN

Urinary System

The **urinary bladder**, trigone, and pelvic urethra presented normal thicknesses and normal tone. The ureters were not visible which is normal. No uroliths or sediment were visualized and anechoic urine was present. No evidence of inflammatory or neoplastic changes was noted. Ureteral papillae were normal.

The **kidneys** revealed normal size and structure, corticomedullary definition and ratio for this age. The cortices presented largely uniform texture with normal echogenic relationship to liver and spleen. Medullary structure differed distinctly from the cortex and no evidence of pelvic dilation was present. The capsules were acceptably uniform without significant irregularities.

Adrenal Glands

Bilateral hyperechoic **adrenal** masses were noted.

Spleen

The **spleen** presented a smooth homogeneous parenchyma hyperechoic to liver and renal cortical parenchyma. The capsule was smooth without noticeable expansion or deviation from within the spleen or adjacent pathology. The splenic vasculature demonstrated normal volume without signs of congestion or thrombosis. No sonographic evidence of acute or chronic inflammatory, neoplastic, or infarctual changes was noted.

Liver

The **liver** images submitted revealed subjectively normal liver size, contour, and structure. Parenchymal echogenicity was naturally coarse and hypoechoic to the spleen. Vascular and biliary tracts were of normal volume with no evidence of congestion. The gallbladder presented acceptably thin walls with primarily anechoic content. The cystic and common bile ducts were normal. No pathological hepatic lymphadenopathy was evident. No overt structural evidence of inflammatory, infiltrative or regenerative pathology was evident.

Gastrointestinal

Examination of the **gastrointestinal tract** revealed a stomach and intestine free of stasis, of normal wall thickness, acceptable curvilinear mural detail, and peristaltic activity. Small and large intestine demonstrated normal luminal chyme and stool consistency respectively. No obstructive or overt infiltrative disease was noted. No associated abnormal lymphatic activity was noted.



PATIENT

Pancreas

Toto Camp P

The base and limbs of the **pancreas** were observed to be largely isoechoic to surrounding omental fat. Pancreatic duct and capsular contour were acceptably normal and parenchyma respected normal curvilinear patterns. No overt evidence of active inflammatory or neoplastic disease was noted.

SPECIES

Canine

ULTRASONOGRAPHIC EXAMINATION OF THE HEART

BREED

Shih Tzu

The echocardiogram in this patient demonstrated normal **left atrial** size based on 3 different LA measurement methods. Chamber volumes and echogenicity were normal. The cranial and caudal **mitral** valve leaflets presented vegetative thickening consistent with endocardiosis. Doppler indicated measurable insufficiency. The **left ventricle** presented thicknesses with linear contour and was not dilated nor restricted. The **myocardium** presented normal echogenicity without subjective evidence of significant fibrotic or ischemic disease. **Contractility** of the ventricular walls was adequate and in normal range for this patient evidenced by the fractional shortening measurement and subjective evaluation of the different regions of the myocardium. The **left ventricular outflow** tract demonstrated normal laminar flow and subjective structural integrity. The **right atrium** and auricle revealed normal size, structure and content. No evidence of masses was noted or chamber overload. **Tricuspid** valvular assessment demonstrated adequate linear morphology. The **right ventricle** was of normal size (1/3 diameter of LV), chordae structure, myocardial echogenicity and thickness. **Pulmonic** tract assessment revealed normal valve structure, laminar flow, and diameter (approx. 1:1 pa/ao ratio). No visible **pericardial** or free pleura fluid was noted. No echographically detectable evidence of infiltrative disease was visible. The cranial **mediastinum and pericardial regions** were free of masses in the visible window.

SEX

Spayed female

AGE

8 years

WEIGHT

15 lbs

INTERPRETED BY

Eric Lindquist, DMV
DABVP, Cert. IVUSS

ULTRASONOGRAPHIC FINDINGS

- Bilateral hyperechoic adrenal masses.
- Mildly thickened mitral valve with moderate regurgitation. This is likely artificially increased by Dexdomitor sedation. Consistent with B1 MMVD

HOSPITAL NAME

SDEP Lab

INTERPRETATION OF THE FINDINGS & FURTHER RECOMMENDATIONS

INVOICE

68703

I recommend testing for Cushing's disease. Otherwise, consider serial ultrasounds to monitor. This may be benign or malignant. I recommend blood pressure measurement.

I recommend a recheck echocardiogram if the murmur is grade 3/6 in the future.

DATE

11/15/25



PATIENT

Toto Camp P

SPECIES

Canine

BREED

Shih Tzu

SEX

Spayed female

AGE

8 years

WEIGHT

15 lbs

INTERPRETED BY

Eric Lindquist, DMV
DABVP, Cert. IVUSS

HOSPITAL NAME

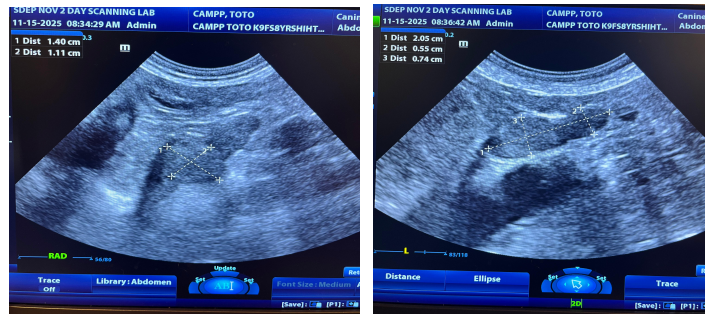
SDEP Lab

INVOICE

68703

DATE

11/15/25



The information and recommendations provided are based on the images presented by the referring veterinarian/sonographer. No evaluation can be communicated regarding pathology that was not visible in the image/video clips provided.

Thank you for this referral. If the clinical or image interpretation does not parallel your findings or if I can be of any further assistance please contact me.

Eric Lindquist, DMV, DABVP, Cert. IVUSS, CEO of SonoPath.com

info@SonoPath.com