



**PATIENT**

Holly Sovyrda

**SPECIES**

Canine

**BREED**

Great Pyrenees

**SEX**

Spayed female

**AGE**

11 years

**WEIGHT**

98 lbs

**INTERPRETED BY**

Eric Lindquist, DMV,  
DABVP, Cert. IVUSS,  
CEO of SonoPath.com

**IMAGING PERFORMED BY**

Eric Lindquist, DMV,  
DABVP, Cert. IVUSS,  
CEO of SonoPath.com

**HOSPITAL NAME**

Butler VH

**REFERRING VET**

Dr. Garro

**INVOICE**

69838

**DATE**

1/6/26

**PRESENTING CLINICAL SIGNS**

Increased ALT, inappropriate urination.

**ULTRASONOGRAPHIC EXAMINATION OF THE ABDOMEN**

**Urinary System**

The **urinary bladder**, trigone, and pelvic urethra presented normal thicknesses and normal tone. The pelvic urethra was imaged 4.0 cm beyond the cystourethral junction and appeared normal. The ureters were not visible which is normal. No uroliths or sediment were visualized and anechoic urine was present. No evidence of inflammatory or neoplastic changes was noted. Ureteral papillae were normal.

The iliac trifurcation was unremarkable.

The **kidneys** revealed normal size and structure, corticomedullary definition and ratio for this age. The cortices presented largely uniform texture with normal echogenic relationship to liver and spleen. Medullary structure differed distinctly from the cortex and no evidence of pelvic dilation was present. The capsules were acceptably uniform without significant irregularities. The left kidney measured 7.8 cm. The right kidney measured 7.15 cm.

**Adrenal Glands**

Both **adrenal glands** were visualized and recognized as having normal shape, size, position and echogenicity for this breed. The phrenic vasculature, glandular echogenicity and detail were unremarkable. Capsule, cortex, and medullary definition were normal for this age patient. The left adrenal gland measured 3.12 x 0.9 cm. The right adrenal gland measured 3.74 x 1.4 cm.

**Spleen**

The **spleen** presented a smooth homogeneous parenchyma hyperechoic to liver and renal cortical parenchyma. The capsule was smooth without noticeable expansion or deviation from within the spleen or adjacent pathology. The splenic vasculature demonstrated normal volume without signs of congestion or thrombosis. No sonographic evidence of acute or chronic inflammatory, neoplastic, or infarctual changes was noted.

**Liver**

The **liver** images submitted revealed subjectively normal liver size, contour, and structure. Parenchymal echogenicity was naturally coarse and hypoechoic to the spleen. Vascular and biliary tracts were of normal volume with no evidence of congestion. The gallbladder presented acceptably thin walls with primarily anechoic content. The cystic and common bile ducts were normal. No pathological hepatic lymphadenopathy was evident. No overt structural evidence of inflammatory, infiltrative or regenerative pathology was evident.



**PATIENT**

Holly Sovyrda

**SPECIES**

Canine

**BREED**

Great Pyrenees

**SEX**

Spayed female

**AGE**

11 years

**WEIGHT**

98 lbs

**INTERPRETED BY**

Eric Lindquist, DMV,  
 DABVP, Cert. IVUSS,  
 CEO of SonoPath.com

**IMAGING PERFORMED BY**

Eric Lindquist, DMV,  
 DABVP, Cert. IVUSS,  
 CEO of SonoPath.com

**HOSPITAL NAME**

Butler VH

**REFERRING VET**

Dr. Garro

**INVOICE**

69838

**DATE**

1/6/26

**Gastrointestinal**

There was some residual chyme and gas was noted in the **stomach**, yet not pathological. This is consistent with post prandial presentation. Transit of chyme into the small intestine was normal. Curvilinear patterns were maintained throughout the GI tract. No evidence of pathology. Small and large intestine demonstrated normal luminal chyme and stool consistency respectively. No obstructive or overt infiltrative disease was noted. No associated abnormal lymphatic activity was noted.

**Pancreas**

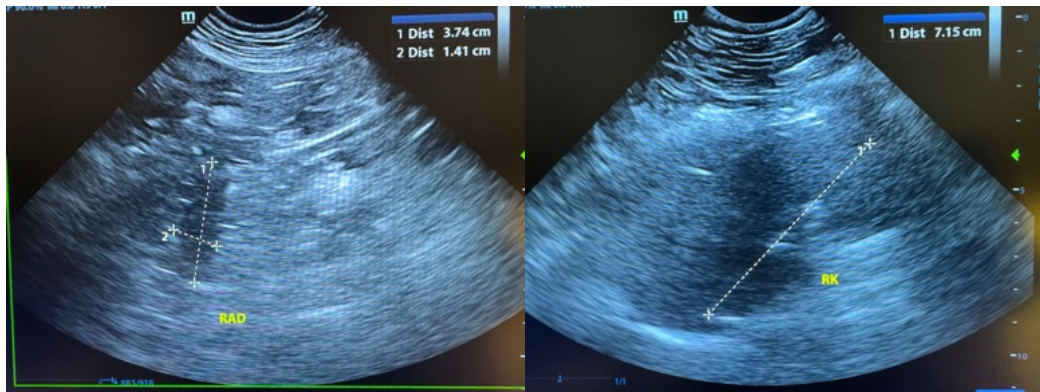
The base and limbs of the **pancreas** were observed to be largely isoechoic to surrounding omental fat. Pancreatic duct and capsular contour were acceptably normal and parenchyma respected normal curvilinear patterns. No overt evidence of active inflammatory or neoplastic disease was noted.

**ULTRASONOGRAPHIC FINDINGS**

- Structurally unremarkable abdomen.

**INTERPRETATION OF THE FINDINGS & FURTHER RECOMMENDATIONS**

There was no evidence of pathology related to the eye issues. Skull CT may be optimal as well as repeat ultrasound of the eye given the history of blood clot. Blood pressure measurements are warranted if not already performed to ensure that hypertension is not an underlying issue. Chest radiographs and cranial mediastinal imaging is recommended to assess for underlying predisposing pathology.





**PATIENT**

Holly Sovyrda

**SPECIES**

Canine

**BREED**

Great Pyrenees

**SEX**

Spayed female

**AGE**

11 years

**WEIGHT**

98 lbs

**INTERPRETED BY**

Eric Lindquist, DMV,  
 DABVP, Cert. IVUSS,  
 CEO of SonoPath.com

**IMAGING PERFORMED BY**

Eric Lindquist, DMV,  
 DABVP, Cert. IVUSS,  
 CEO of SonoPath.com

**HOSPITAL NAME**

Butler VH

**REFERRING VET**

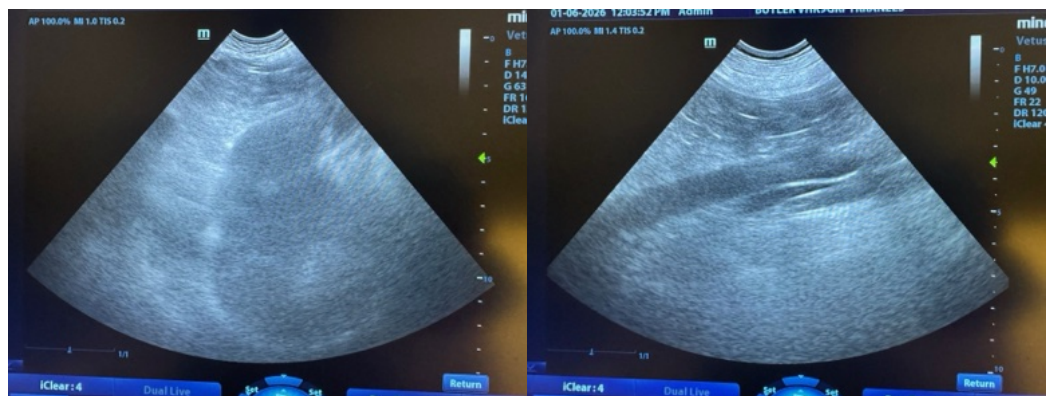
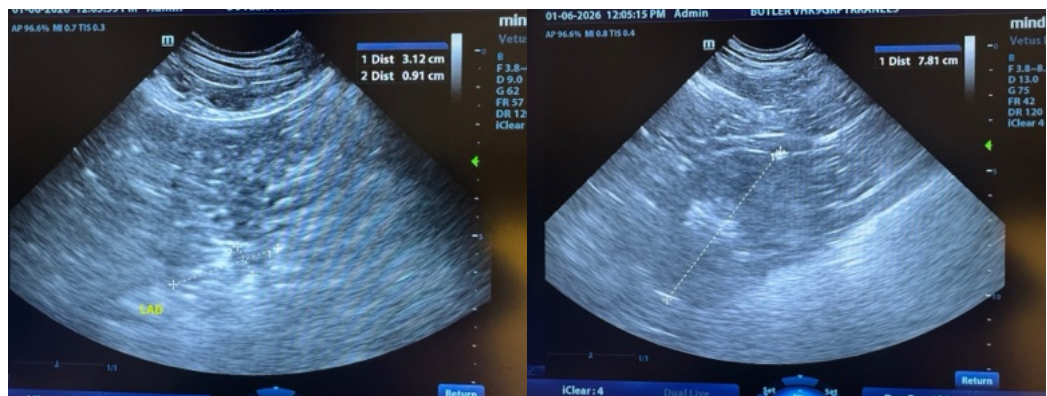
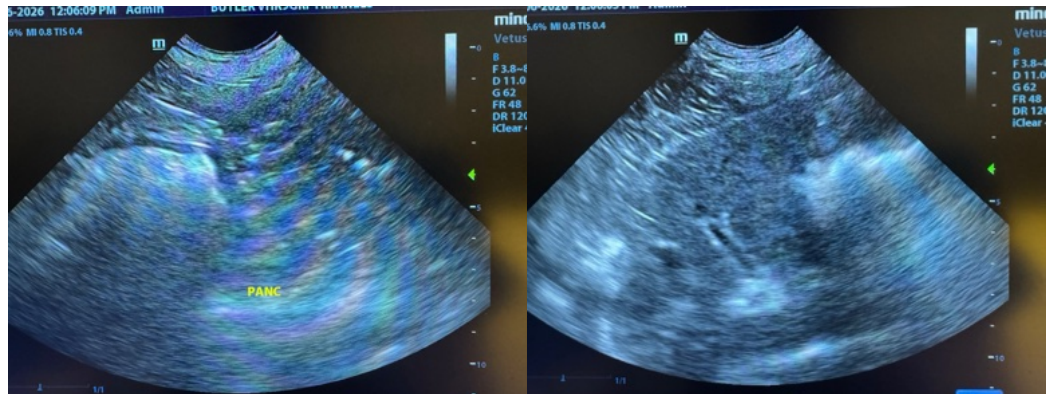
Dr. Garro

**INVOICE**

69838

**DATE**

1/6/26





**PATIENT**

Holly Sovyrda

**SPECIES**

Canine

**BREED**

Great Pyrenees

**SEX**

Spayed female

**AGE**

11 years

**WEIGHT**

98 lbs

**INTERPRETED BY**

Eric Lindquist, DMV,  
DABVP, Cert. IVUSS,  
CEO of SonoPath.com

**IMAGING PERFORMED BY**

Eric Lindquist, DMV,  
DABVP, Cert. IVUSS,  
CEO of SonoPath.com

**HOSPITAL NAME**

Butler VH

**REFERRING VET**

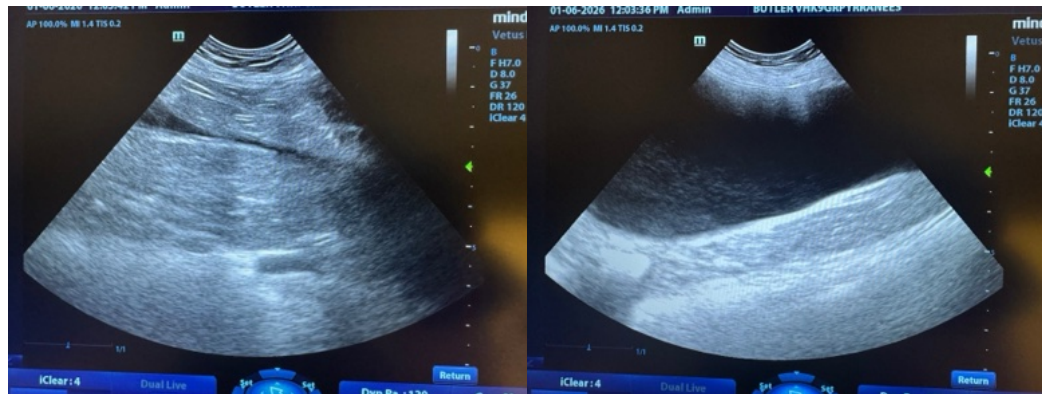
Dr. Garro

**INVOICE**

69838

**DATE**

1/6/26



The information and recommendations provided are based on the images presented by the referring veterinarian/sonographer. No evaluation can be communicated regarding pathology that was not visible in the image/video clips provided.

Thank you for this referral. If the clinical or image interpretation does not parallel your findings or if I can be of any further assistance please contact me.

Eric Lindquist, DMV, DABVP, Cert. IVUSS, CEO of SonoPath.com

Info@SonoPath.com