



**PATIENT**

Grayson Paini

**SPECIES**

Feline

**BREED**

Maine Coon

**SEX**

Neutered male

**AGE**

12 years

**WEIGHT**

17.4 lbs

**INTERPRETED BY**

Eric Lindquist, DMV,  
 DABVP (CFM), Cert.  
 IVUSS, CEO of  
 SonoPath.com

**IMAGING PERFORMED BY**

Vincent Ravancho

**HOSPITAL NAME**

Harmony AH

**REFERRING VET**

Dr. Gruber

**INVOICE**

69801

**DATE**

1/5/26

**PRESENTING CLINICAL SIGNS**

History of lethargy, noy eating, not drinking. Vomiting (Since 12/31 ADR) Clinical findings: Vomiting, doughy abdomen, unthrifty coat with prolonged skin tent. Current medications: Ceneria, famotidine, Doxycycline, SQ Fluids, Prednisone PO SID, Gabapentin  
 Abnormal PE/Chem/CBC/UA Results: HTC 19% (1/4/26) was 22% (1/2/26) Eos 0.02 Chem - ALT too high to read FIV/FELV - n/n mycoplasma - negative

**ULTRASONOGRAPHIC EXAMINATION OF THE ABDOMEN**

**Urinary System**

The **urinary bladder** and visible pelvic urethra were unremarkable for the level of repletion presented. The urine, however, did present some mildly echogenic debris consistent with mucous, exfoliated cells from renal or bladder origin, and/or blood clots as these echogenic changes can all present similarly. This is often related to urinary tract infection but may represent simple evidence of exfoliated debris or sterile inflammation. Cystocentesis, urinalysis, +/- culture would be recommended to rule out and define any UTI.

The **kidneys** revealed largely normal size and structure, corticomedullary definition and ratio (cortex 1/3 of medulla) were essentially maintained with some age-related loss of curvilinear patterns regarding the capsule and C/M junction. The cortices presented largely uniform texture with some increased echogenicity expected for this age patient. Medullary structure differed distinctly from that of the cortex and no evidence of pelvic dilation was present. The left kidney measured 4.9 cm. The right kidney measured 4.8 cm.

**Adrenal Glands**

Both **adrenal glands** were visualized and recognized as having normal shape, size, position and echogenicity for this breed. The phrenic vasculature, glandular echogenicity and detail were unremarkable. Capsule, cortex, and medullary definition were normal for this age patient. The left adrenal gland measured 0.45 cm. The right adrenal gland measured 0.44 cm.

**Spleen**

The **spleen** was significantly enlarged and measured 2.4 cm in width. There was no evidence of thrombosis. There were no overt masses, however, infiltrative disease is a strong potential.

**Liver**

The left cranial **liver** revealed an expansive, mixed echogenic complex mass. The mass measured 5.6 cm with a mild amount of surrounding free fluid. The mass may prove to be resectable. The gallbladder was small and unremarkable.



**PATIENT**

Grayson Paini

**SPECIES**

Feline

**BREED**

Maine Coon

**SEX**

Neutered male

**AGE**

12 years

**WEIGHT**

17.4 lbs

**INTERPRETED BY**

Eric Lindquist, DMV,  
DABVP (CFM), Cert.  
IVUSS, CEO of  
SonoPath.com

**IMAGING  
PERFORMED BY**

Vincent Ravancho

**HOSPITAL NAME**

Harmony AH

**REFERRING VET**

Dr. Gruber

**INVOICE**

69801

**DATE**

1/5/26

***Gastrointestinal***

The **stomach** revealed progressively shadowing luminal material that is consistent with hairball and ingesta combination. The small intestines and colon were unremarkable with normal curvilinear mural patterns and content.

***Pancreas***

The base and limbs of the **pancreas** were observed to be largely isoechoic to surrounding omental fat. Pancreatic duct and capsular contour were acceptably normal and parenchyma respected normal curvilinear patterns. No overt evidence of active inflammatory or neoplastic disease was noted.

***Free Abdomen***

A large amount of abdominal fat was noted in this patient.

Free fluid was noted and suggestive for hemorrhage, yet not significant enough to justify the severe anemia. Bone marrow disease may be an issue.

**ULTRASONOGRAPHIC FINDINGS**

Left cranial liver mass. Hemangiosarcoma, carcinoma and less likely carcinoma. Abscessation is less likely.

Mild splenomegaly. Reactive spleen, round cell neoplasia.

Hairball and ingesta in the stomach.

**INTERPRETATION OF THE FINDINGS & FURTHER RECOMMENDATIONS**

CT evaluation for surgical planning is warranted. Screening FNA of the liver mass and spleen would be indicated at the time of CT. Prognosis is guarded.

**ABOUT SONOPATH CT SERVICES:**

**SonoPath CT Services** are offered at the SonoPath Imaging and Veterinary Education Center, 141 Main St (rt 206), Andover, New Jersey, a 20-minute drive west on route 80/206 North from the route 80/287 interchange/Parsippany, New Jersey. More information can be found at <https://sonopath.com/services/vetimaging/>



**PATIENT**

Grayson Painsi

**SPECIES**

Feline

**BREED**

Maine Coon

**SEX**

Neutered male

**AGE**

12 years

**WEIGHT**

17.4 lbs

**INTERPRETED BY**

Eric Lindquist, DMV,  
 DABVP (CFM), Cert.  
 IVUSS, CEO of  
 SonoPath.com

**IMAGING PERFORMED BY**

Vincent Ravancho

**HOSPITAL NAME**

Harmony AH

**REFERRING VET**

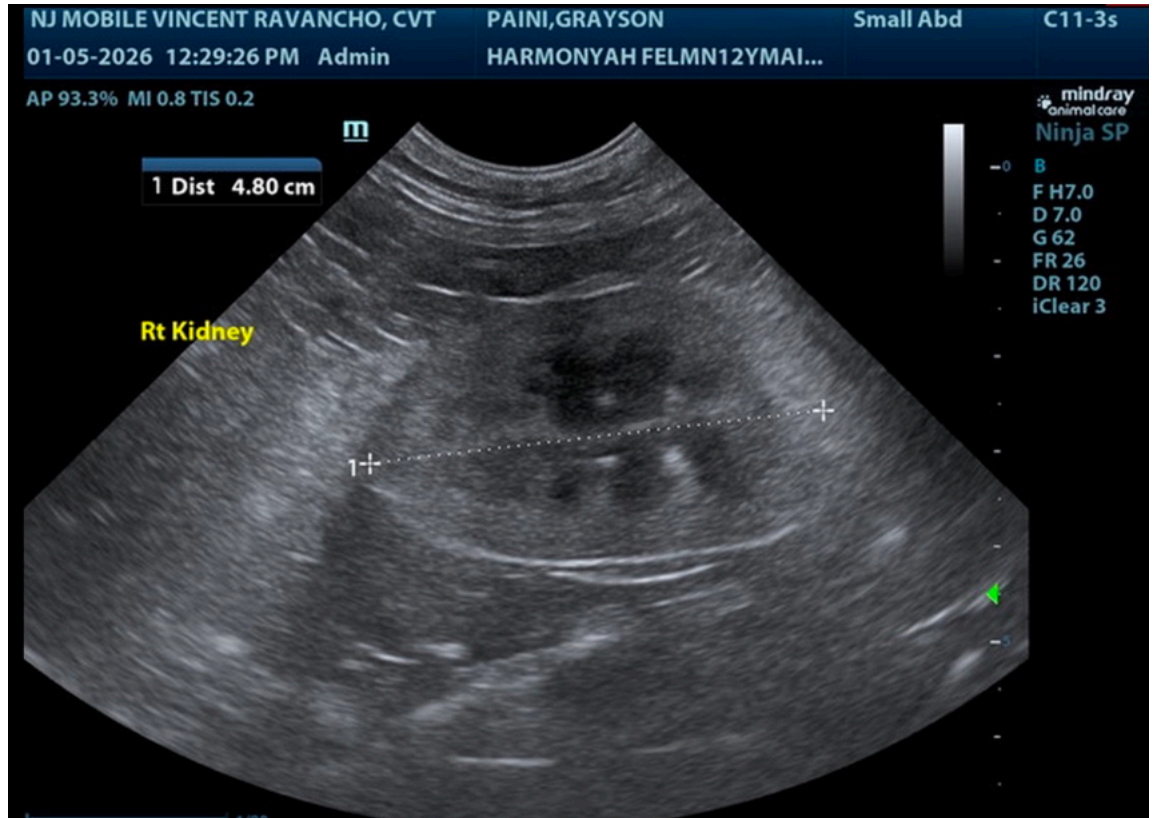Dr. Gruber

**INVOICE**

69801

**DATE**

1/5/26





**PATIENT**

Grayson Painsi

**SPECIES**

Feline

**BREED**

Maine Coon

**SEX**

Neutered male

**AGE**

12 years

**WEIGHT**

17.4 lbs

**INTERPRETED BY**

Eric Lindquist, DMV,  
 DABVP (CFM), Cert.  
 IVUSS, CEO of  
 SonoPath.com

**IMAGING PERFORMED BY**

Vincent Ravancho

**HOSPITAL NAME**

Harmony AH

**REFERRING VET**

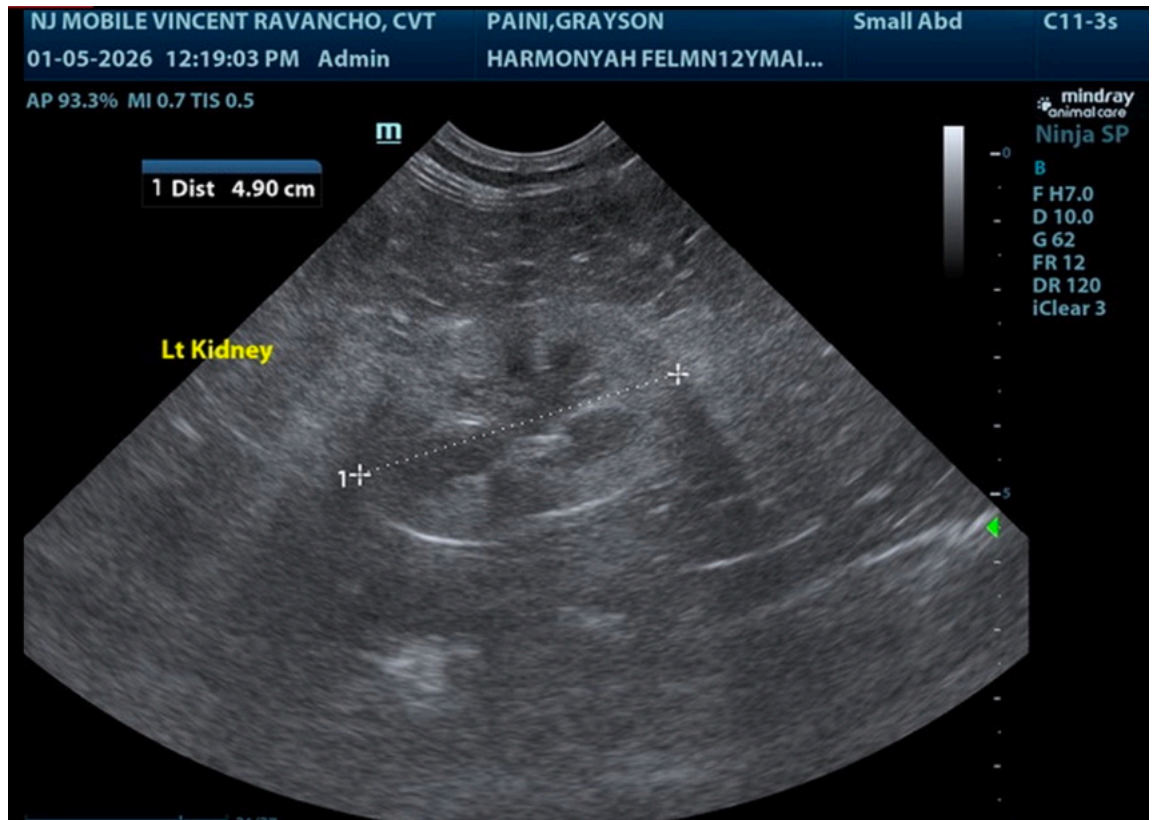Dr. Gruber

**INVOICE**

69801

**DATE**

1/5/26





**PATIENT**

Grayson Pains

**SPECIES**

Feline

**BREED**

Maine Coon

**SEX**

Neutered male

**AGE**

12 years

**WEIGHT**

17.4 lbs

**INTERPRETED BY**

Eric Lindquist, DMV,  
 DABVP (CFM), Cert.  
 IVUSS, CEO of  
 SonoPath.com

**IMAGING PERFORMED BY**

Vincent Ravancho

**HOSPITAL NAME**

Harmony AH

**REFERRING VET**

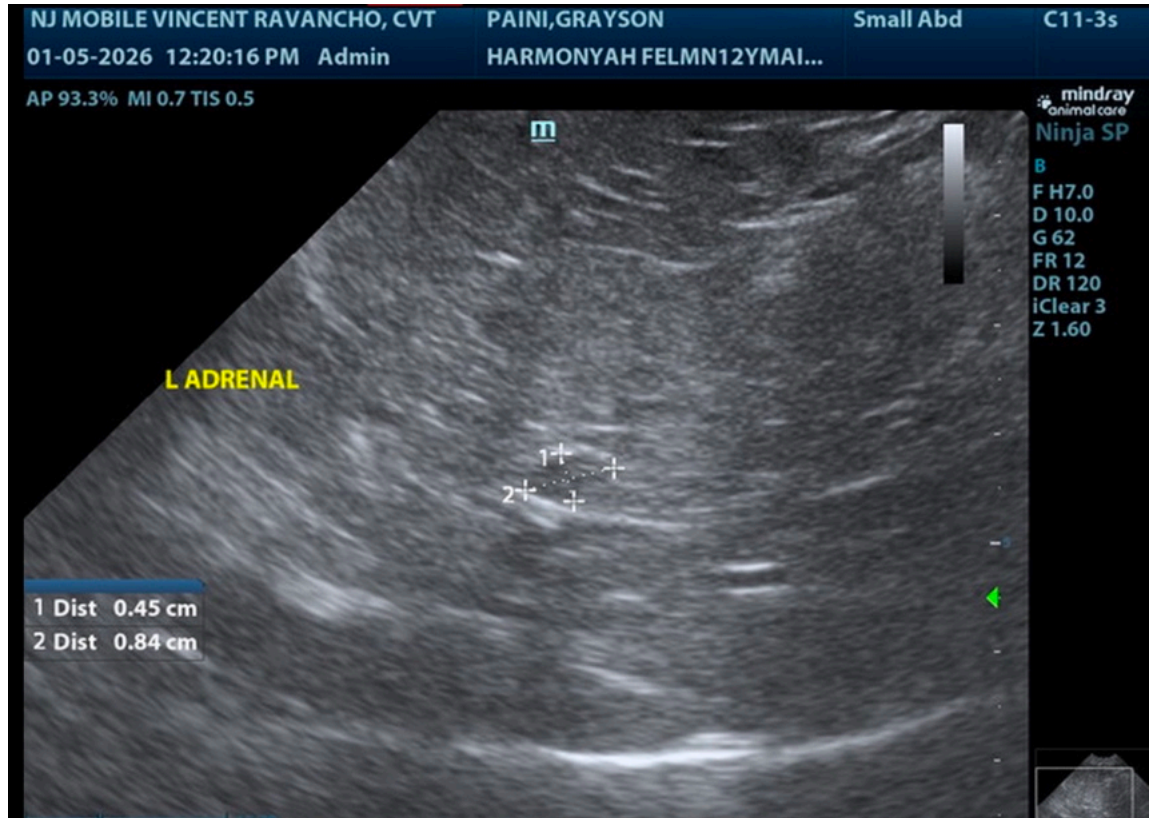
Dr. Gruber

**INVOICE**

69801

**DATE**

1/5/26





**PATIENT**

Grayson Pains

**SPECIES**

Feline

**BREED**

Maine Coon

**SEX**

Neutered male

**AGE**

12 years

**WEIGHT**

17.4 lbs

**INTERPRETED BY**

Eric Lindquist, DMV,  
 DABVP (CFM), Cert.  
 IVUSS, CEO of  
 SonoPath.com

**IMAGING PERFORMED BY**

Vincent Ravancho

**HOSPITAL NAME**

Harmony AH

**REFERRING VET**

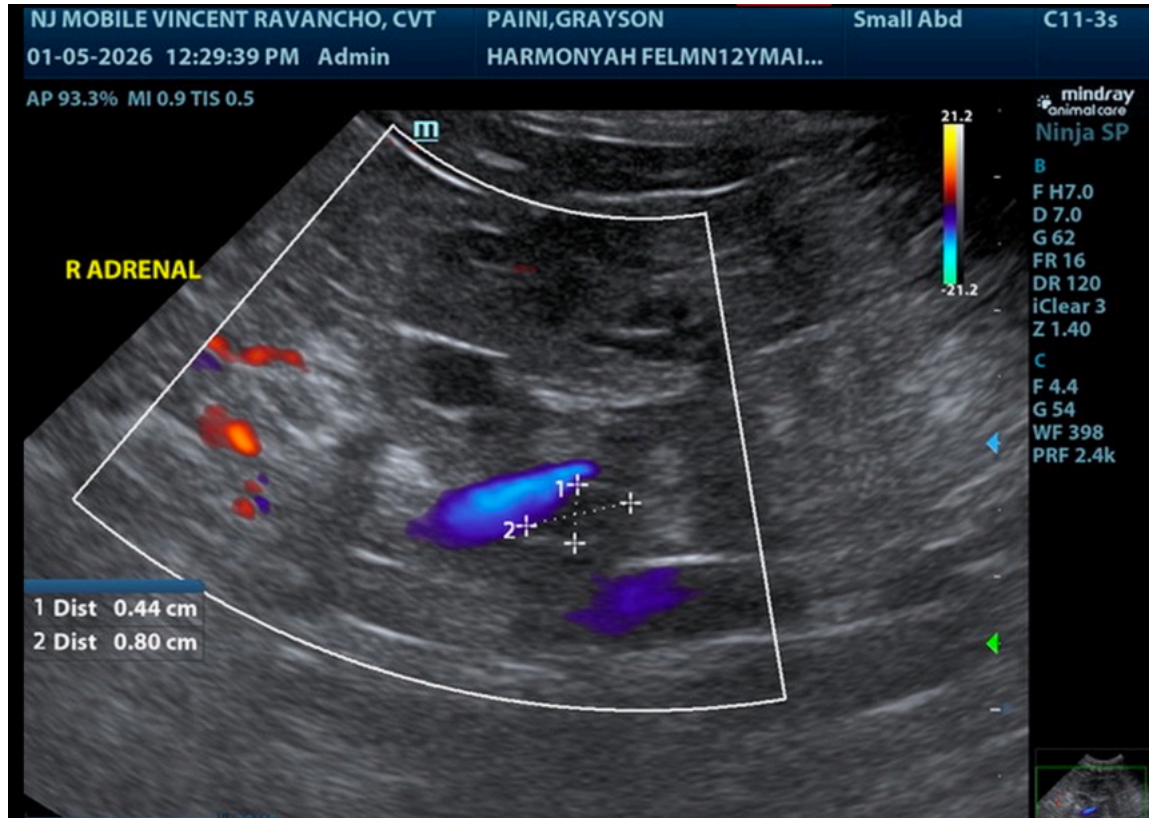
Dr. Gruber

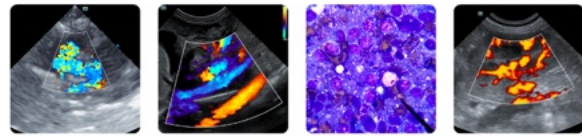
**INVOICE**

69801

**DATE**

1/5/26





**PATIENT**

Grayson Pains

**SPECIES**

Feline

**BREED**

Maine Coon

**SEX**

Neutered male

**AGE**

12 years

**WEIGHT**

17.4 lbs

**INTERPRETED BY**

Eric Lindquist, DMV,  
 DABVP (CFM), Cert.  
 IVUSS, CEO of  
 SonoPath.com

**IMAGING PERFORMED BY**

Vincent Ravancho

**HOSPITAL NAME**

Harmony AH

**REFERRING VET**

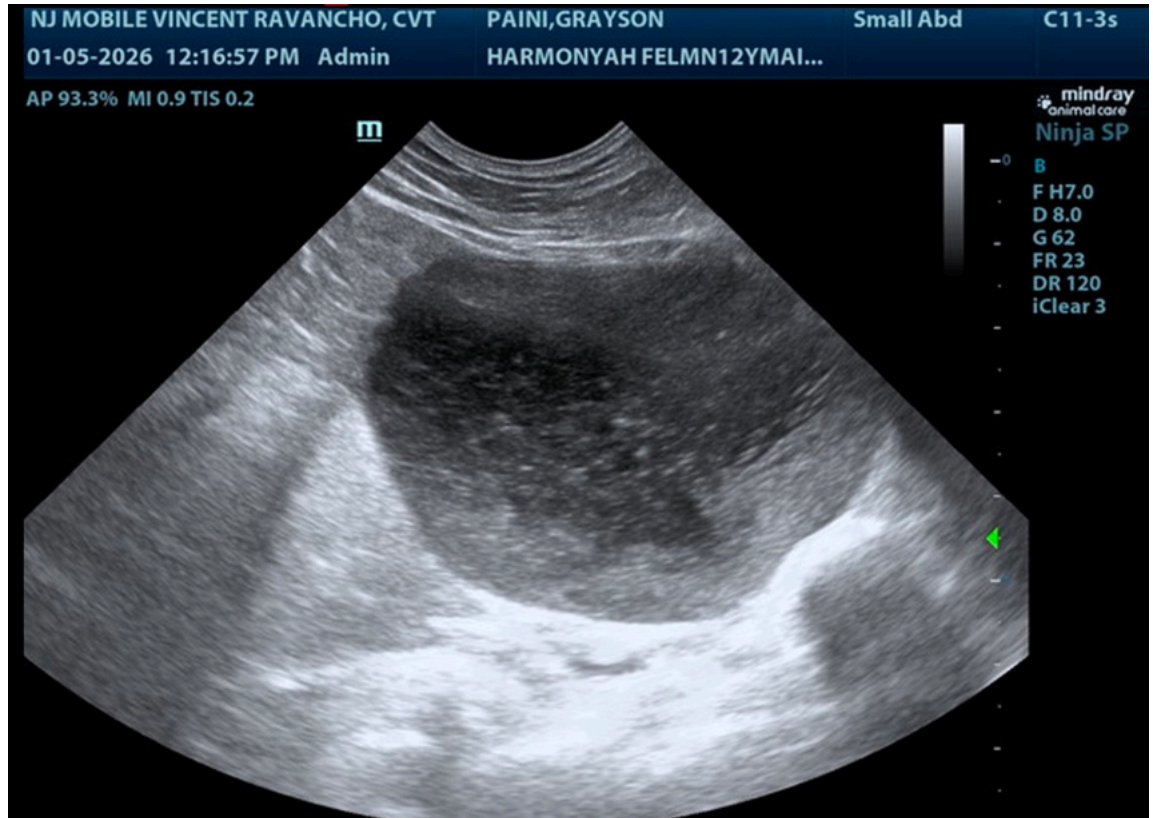
Dr. Gruber

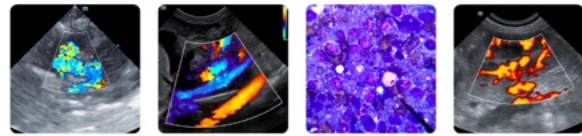
**INVOICE**

69801

**DATE**

1/5/26





**PATIENT**

Grayson Pains

**SPECIES**

Feline

**BREED**

Maine Coon

**SEX**

Neutered male

**AGE**

12 years

**WEIGHT**

17.4 lbs

**INTERPRETED BY**

Eric Lindquist, DMV,  
DABVP (CFM), Cert.  
IVUSS, CEO of  
SonoPath.com

**IMAGING  
PERFORMED BY**

Vincent Ravancho

**HOSPITAL NAME**

Harmony AH

**REFERRING VET**

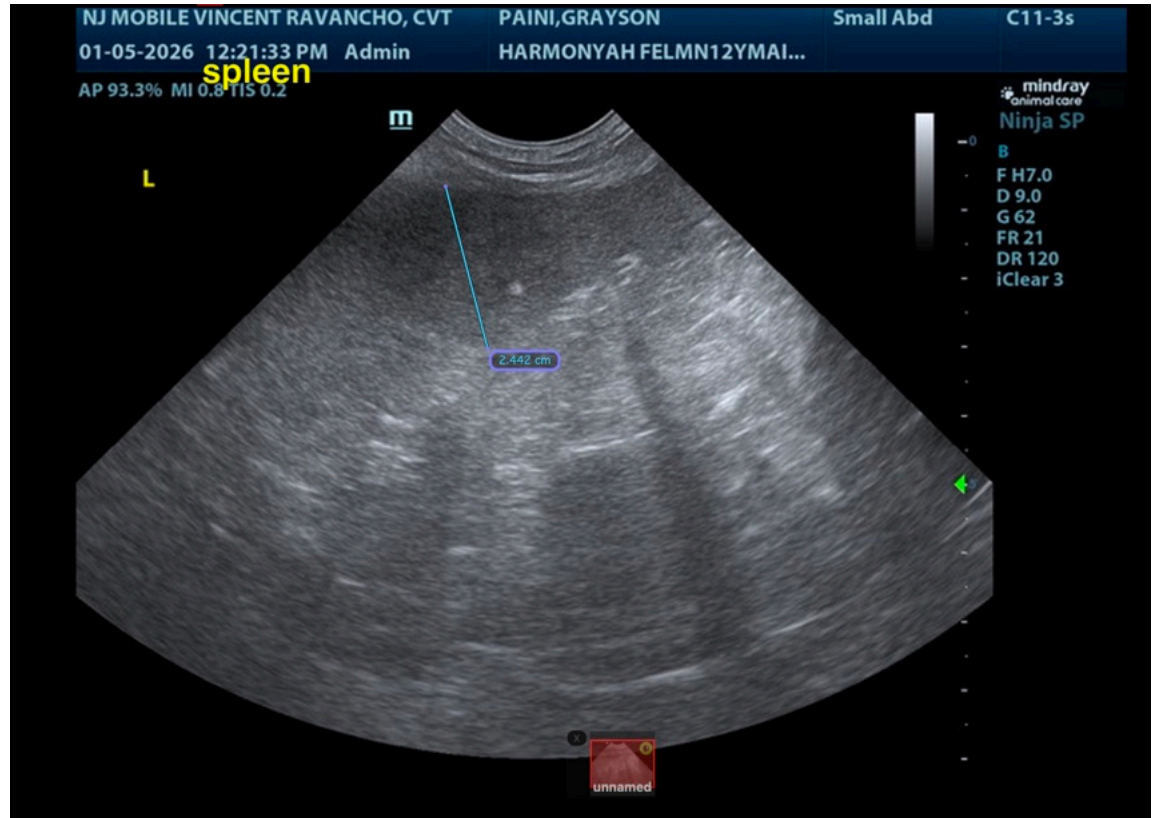
Dr. Gruber

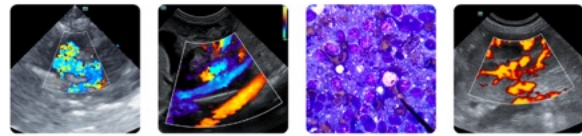
**INVOICE**

69801

**DATE**

1/5/26





**PATIENT**

Grayson Paini

**SPECIES**

Feline

**BREED**

Maine Coon

**SEX**

Neutered male

**AGE**

12 years

**WEIGHT**

17.4 lbs

**INTERPRETED BY**

Eric Lindquist, DMV,  
 DABVP (CFM), Cert.  
 IVUSS, CEO of  
 SonoPath.com

**IMAGING PERFORMED BY**

Vincent Ravancho

**HOSPITAL NAME**

Harmony AH

**REFERRING VET**

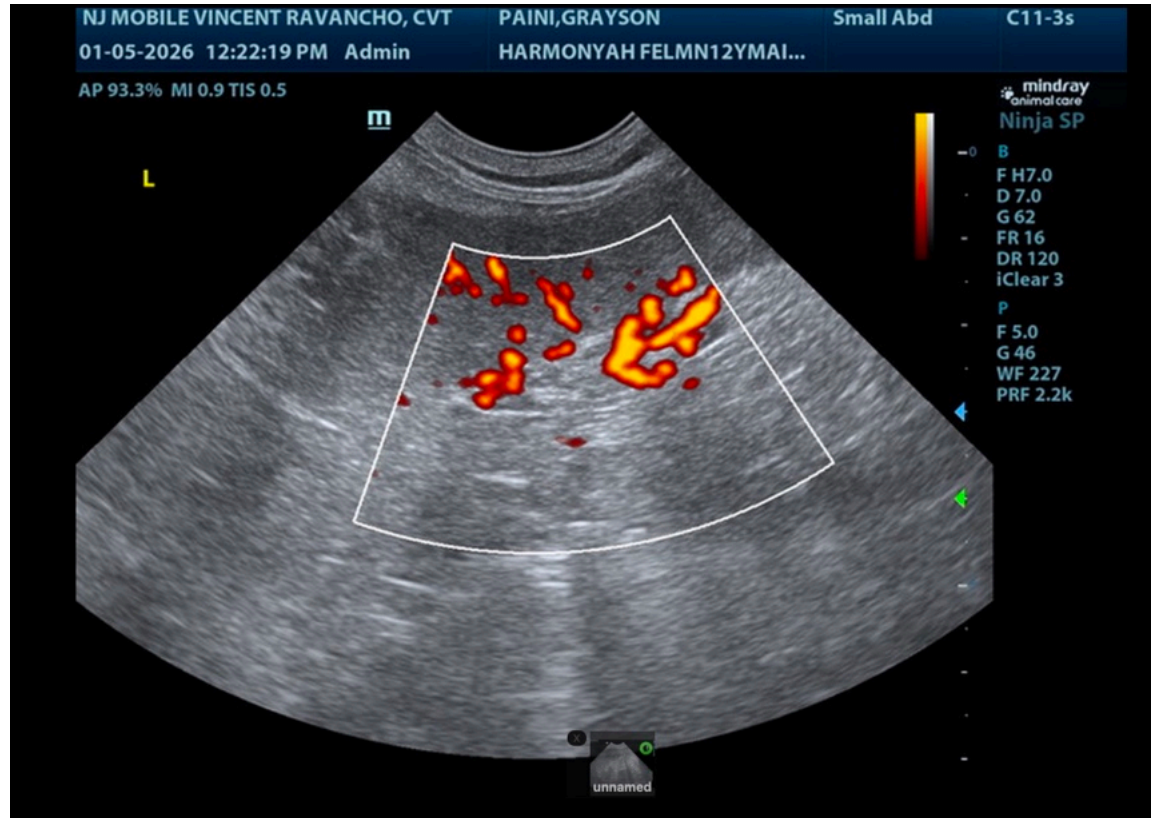
Dr. Gruber

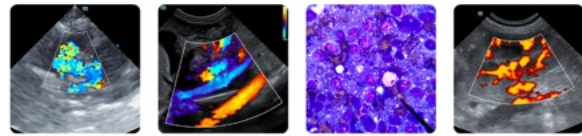
**INVOICE**

69801

**DATE**

1/5/26





**PATIENT**

Grayson Paini

**SPECIES**

Feline

**BREED**

Maine Coon

**SEX**

Neutered male

**AGE**

12 years

**WEIGHT**

17.4 lbs

**INTERPRETED BY**

Eric Lindquist, DMV,  
 DABVP (CFM), Cert.  
 IVUSS, CEO of  
 SonoPath.com

**IMAGING PERFORMED BY**

Vincent Ravancho

**HOSPITAL NAME**

Harmony AH

**REFERRING VET**

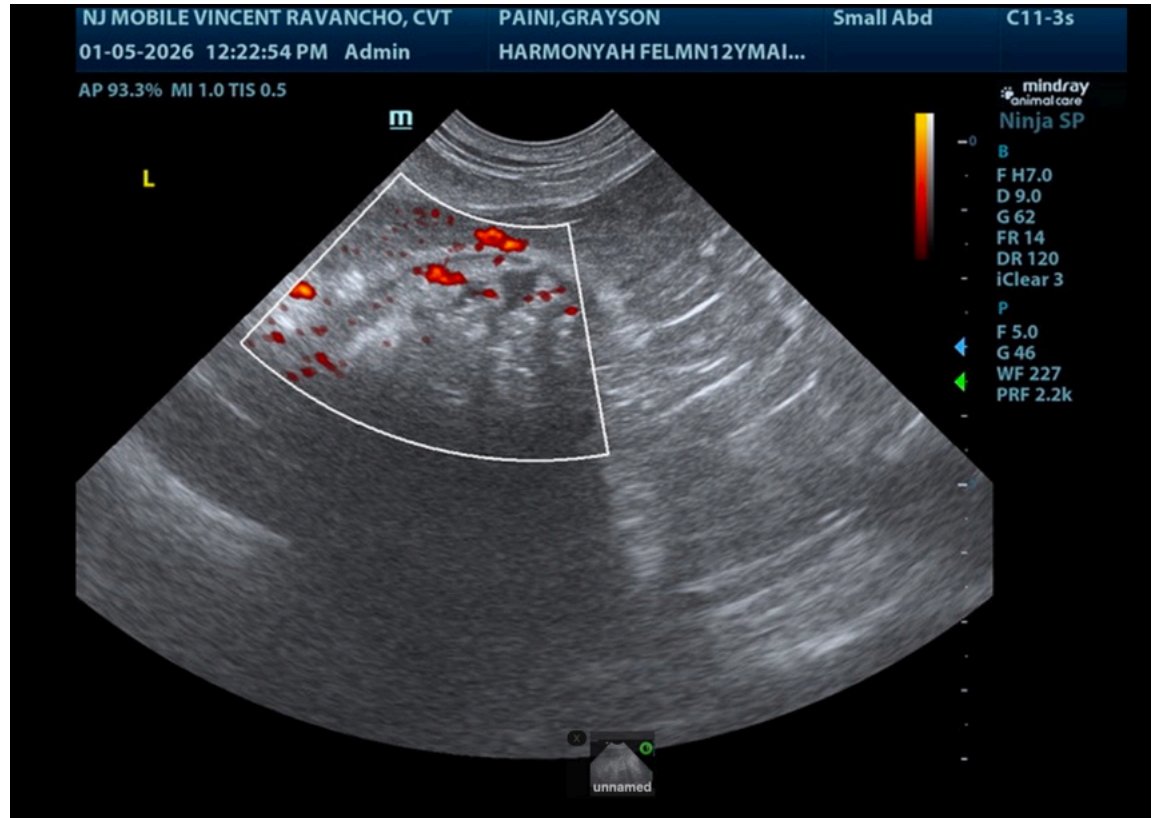
Dr. Gruber

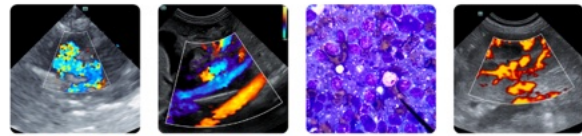
**INVOICE**

69801

**DATE**

1/5/26





**PATIENT**

Grayson Paini

**SPECIES**

Feline

**BREED**

Maine Coon

**SEX**

Neutered male

**AGE**

12 years

**WEIGHT**

17.4 lbs

**INTERPRETED BY**

Eric Lindquist, DMV,  
DABVP (CFM), Cert.  
IVUSS, CEO of  
SonoPath.com

**IMAGING PERFORMED BY**

Vincent Ravancho

**HOSPITAL NAME**

Harmony AH

**REFERRING VET**

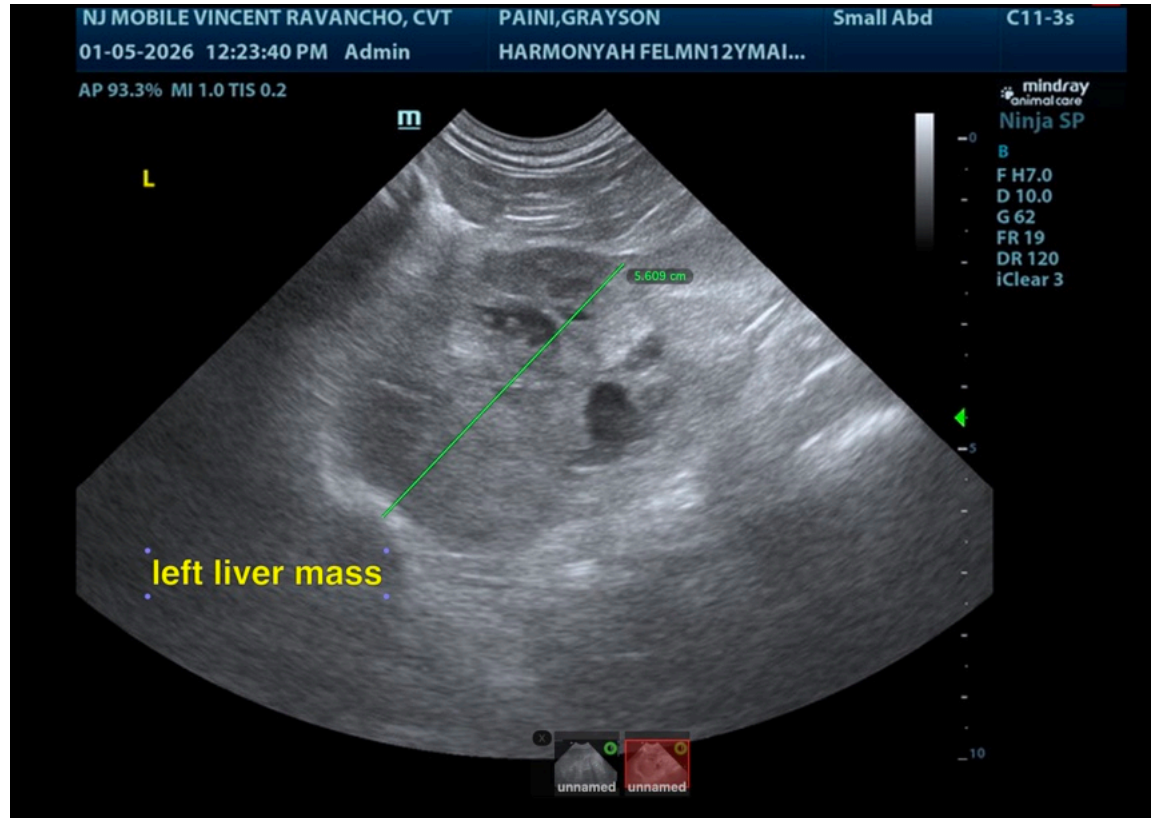
Dr. Gruber

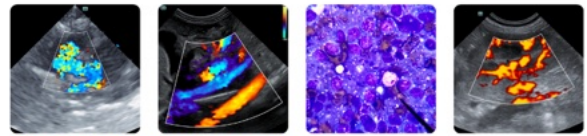
**INVOICE**

69801

**DATE**

1/5/26





**PATIENT**

Grayson Pains

**SPECIES**

Feline

**BREED**

Maine Coon

**SEX**

Neutered male

**AGE**

12 years

**WEIGHT**

17.4 lbs

**INTERPRETED BY**

Eric Lindquist, DMV,  
DABVP (CFM), Cert.  
IVUSS, CEO of  
SonoPath.com

**IMAGING PERFORMED BY**

Vincent Ravancho

**HOSPITAL NAME**

Harmony AH

**REFERRING VET**

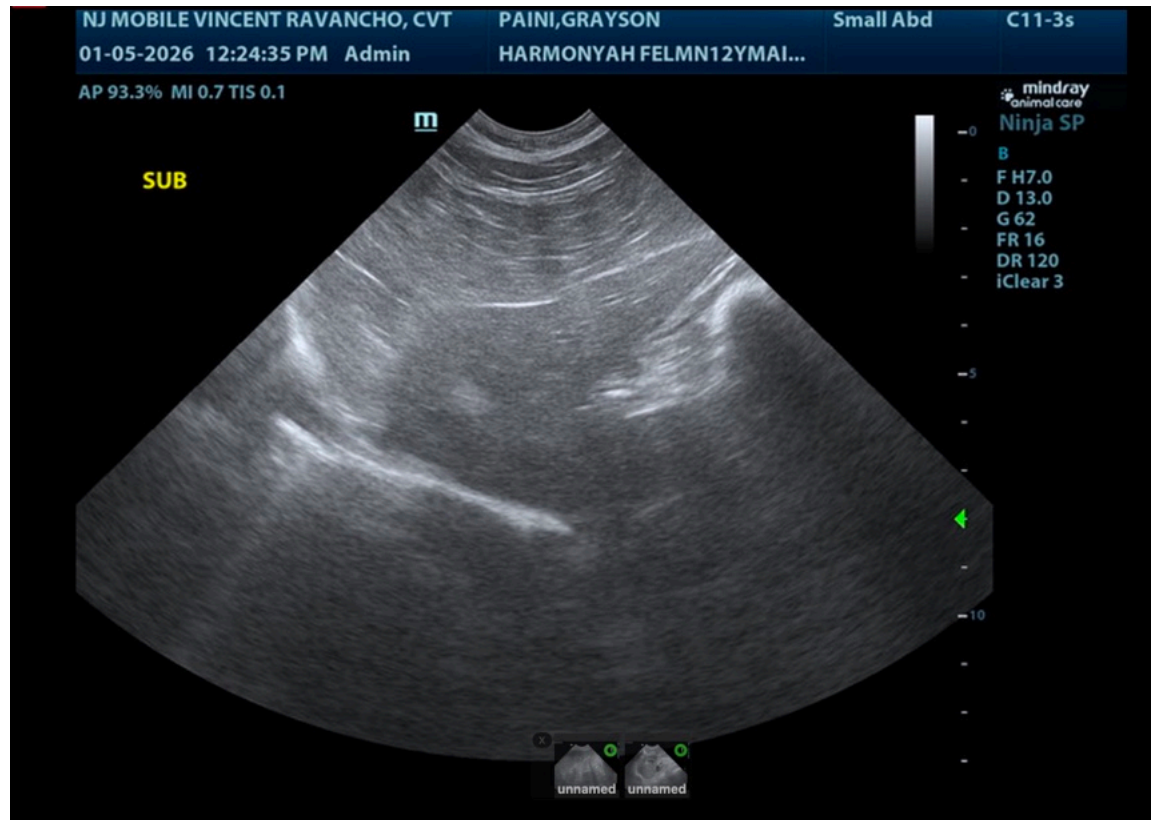
Dr. Gruber

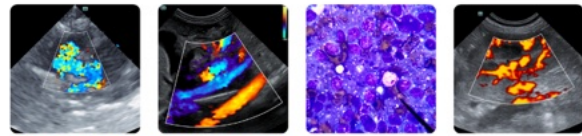
**INVOICE**

69801

**DATE**

1/5/26





**PATIENT**

Grayson Painsi

**SPECIES**

Feline

**BREED**

Maine Coon

**SEX**

Neutered male

**AGE**

12 years

**WEIGHT**

17.4 lbs

**INTERPRETED BY**

Eric Lindquist, DMV,  
 DABVP (CFM), Cert. IVUSS, CEO of SonoPath.com

**IMAGING PERFORMED BY**

Vincent Ravancho

**HOSPITAL NAME**

Harmony AH

**REFERRING VET**

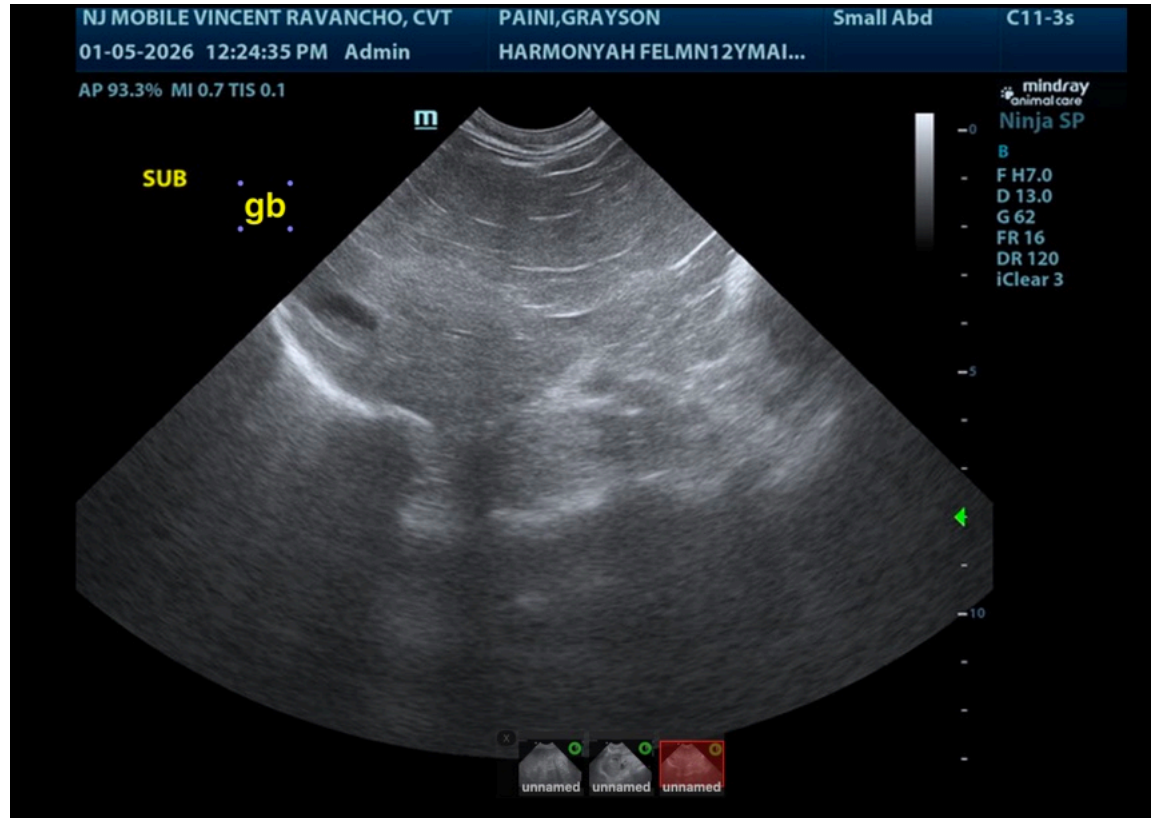
Dr. Gruber

**INVOICE**

69801

**DATE**

1/5/26



The information and recommendations provided are based on the images presented by the referring veterinarian/sonographer. No evaluation can be communicated regarding pathology that was not visible in the image/video clips provided.

Thank you for this referral. If the clinical or image interpretation does not parallel your findings or if I can be of any further assistance please contact me.

Eric Lindquist, DMV, DABVP (CFM), Cert. IVUSS, CEO of SonoPath.com

Info@SonoPath.com