



PATIENT

Coco Calabro

SPECIES

Canine

BREED

Havanese

SEX

Neutered male

AGE

14 years

WEIGHT

-

INTERPRETED BY

Eric Lindquist, DMV,
DABVP (CFM), Cert.
IVUSS, CEO of
SonoPath.com

IMAGING PERFORMED BY

Vincent Ravancho,
CVT

HOSPITAL NAME

Englewood Cliff VH

REFERRING VET

Dr. Attanasi

INVOICE

70980

DATE

1/27/26

PRESENTING CLINICAL SIGNS

- Pancreatic, kidney, liver all elevated; losing wt.
- SDMA 30 Creatinine 2.2 BUN 84

ULTRASONOGRAPHIC EXAMINATION OF THE ABDOMEN

Urinary System

The **urinary bladder**, trigone, and pelvic urethra presented normal thicknesses and normal tone. The pelvic urethra was imaged 2.0 cm beyond the cystourethral junction and appeared normal. The ureters were not visible which is normal. No uroliths or sediment were visualized and anechoic urine was present. No evidence of inflammatory or neoplastic changes was noted. Ureteral papillae were normal.

The **kidneys** revealed largely normal size and structure, corticomedullary definition and ratio (cortex 1/3 of medulla) were essentially maintained with some age-related loss of curvilinear patterns regarding the capsule and C/M junction. The cortices presented largely uniform texture with some increased echogenicity expected for this age patient. Medullary structure differed distinctly from that of the cortex. The kidneys revealed multi-focal, microcystic changes. The right kidney measured 4.7 cm. The left kidney measured 4.63 cm with slight pyelectasia and echogenic debris.

The residual prostate measured 0.5 cm.

Adrenal Glands

Both **adrenal glands** are slightly swollen and slightly enlarged. The left adrenal gland measured 1.8 x 0.58 cm at the cranial pole and 0.63 cm at the caudal pole. The right adrenal gland measured 1.71 x 1.22 cm at the cranial pole and 0.62 cm at the caudal pole.

Spleen

The **spleen** presented a smooth homogeneous parenchyma hyperechoic to liver and renal cortical parenchyma. The capsule was smooth without noticeable expansion or deviation from within the spleen or adjacent pathology. The splenic vasculature demonstrated normal volume without signs of congestion or thrombosis. No sonographic evidence of acute or chronic inflammatory, neoplastic, or infarctual changes was noted.

Liver

The **liver** was uniformly swollen with minor, excessive gallbladder debris and over distension with dependent and suspended bile without evidence of overt mucocele formation. However, excessive sludge was present. The liver presented coarse architecture with mildly increased portal markings and subtle, mixed echogenic changes. This is consistent with vacuolar hepatopathy and some level of remodeling and history of inflammatory component. There was no overt suspicion of neoplasia.



PATIENT

Coco Calabro

SPECIES

Canine

BREED

Havanese

SEX

Neutered male

AGE

14 years

WEIGHT

-

INTERPRETED BY

Eric Lindquist, DMV,
DABVP (CFM), Cert.
IVUSS, CEO of
SonoPath.com

IMAGING PERFORMED BY

Vincent Ravancho,
CVT

HOSPITAL NAME

Englewood Cliff VH

REFERRING VET

Dr. Attanasi

INVOICE

70980

DATE

1/27/26

Gastrointestinal

Examination of the **gastrointestinal tract** revealed a stomach and intestine free of stasis, of normal wall thickness, acceptable curvilinear mural detail, and peristaltic activity. Small and large intestine demonstrated normal luminal chyme and stool consistency respectively. No obstructive or overt infiltrative disease was noted. No associated abnormal lymphatic activity was noted.

Pancreas

The base and limbs of the **pancreas** were observed to be largely isoechoic to surrounding omental fat. Some parenchymal remodeling, however, with mild deviation from curvilinear normalcy was observed. Pancreatic duct and capsular irregularities were present consistent with age related changes. If pain upon imaging (+ Murphy sign) was present or if the patient is focally painful in subxiphoid palpation then low-grade smoldering chronic pancreatitis should be suspected.

ULTRASONOGRAPHIC FINDINGS

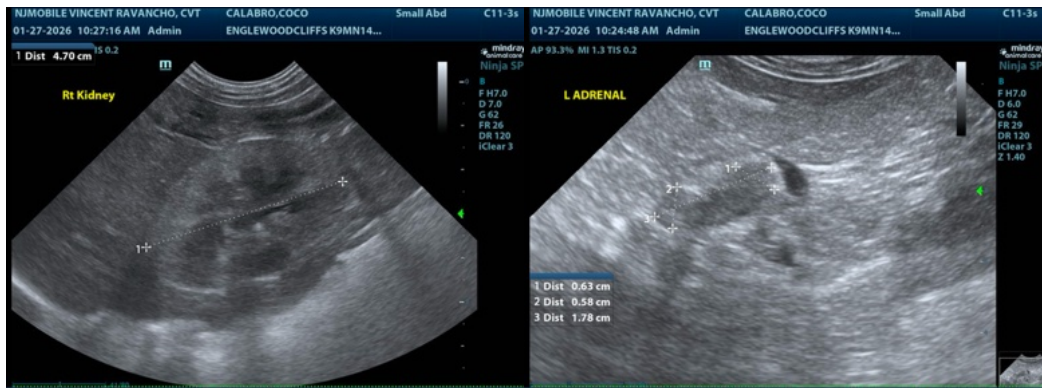
Bilateral adrenal hypertrophy, potential emerging PDH.

Moderate age related renal changes with secondary cortical cysts.

INTERPRETATION OF THE FINDINGS & FURTHER RECOMMENDATIONS

I am concerned about emerging renal failure in this patient. Full urinary work-up is recommended along with culture and sensitivity, blood pressure measurements and IV fluid protocol is all indicated. The cause of weight loss is not evident.

Maldigestion panel, three view chest radiographs and full CNS examination is recommended to examine for occult disease that could be responsible for the weight loss. Evaluation for competitive eating environments should also be considered.





PATIENT

Coco Calabro

SPECIES

Canine

BREED

Havanese

SEX

Neutered male

AGE

14 years

WEIGHT

-

INTERPRETED BY

Eric Lindquist, DMV,
DABVP (CFM), Cert.
IVUSS, CEO of
SonoPath.com

**IMAGING
PERFORMED BY**

Vincent Ravancho,
CVT

HOSPITAL NAME

Englewood Cliff VH

REFERRING VET

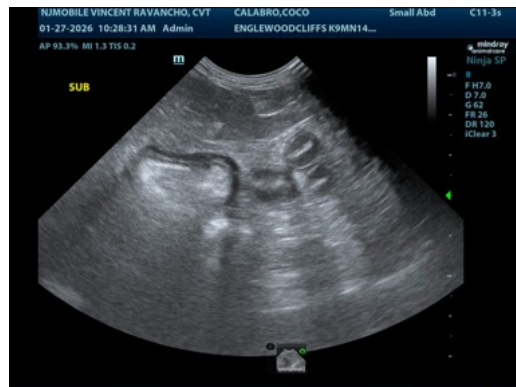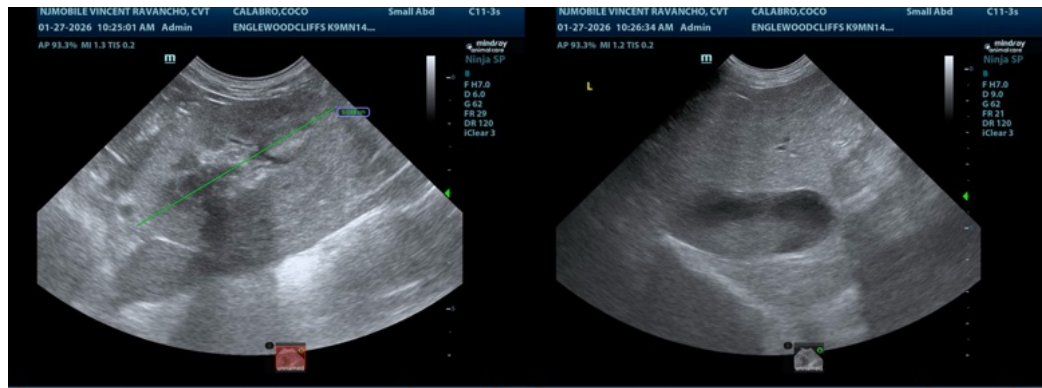
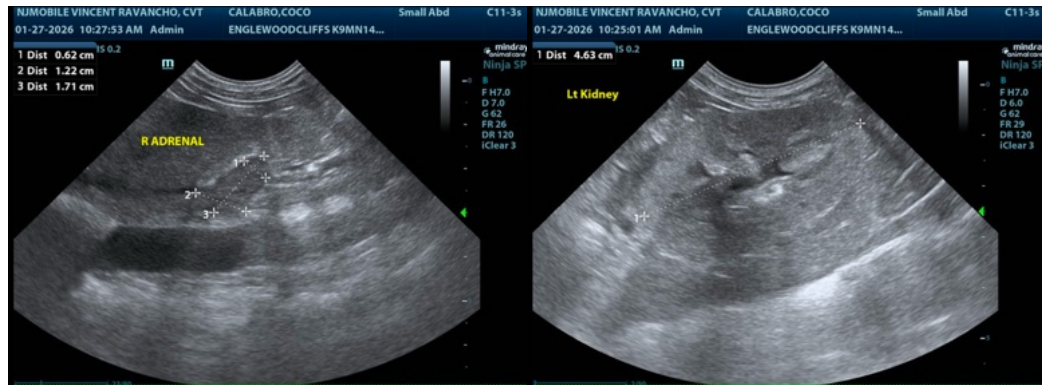
Dr. Attanasi

INVOICE

70980

DATE

1/27/26



The information and recommendations provided are based on the images presented by the referring veterinarian/sonographer. No evaluation can be communicated regarding pathology that was not visible in the image/video clips provided.

Thank you for this referral. If the clinical or image interpretation does not parallel your findings or if I can be of any further assistance please contact me.

Eric Lindquist, DMV, DABVP (CFM), Cert. IVUSS, CEO of SonoPath.com

Info@SonoPath.com