



PATIENT

Skippy Strauss

SPECIES

Canine

BREED

Beagle Mix

SEX

Neutered male

AGE

10 year

WEIGHT

-

INTERPRETED BY

Eric Lindquist, DMV
DABVP, Cert. IVUSS

IMAGING PERFORMED BY

Rebecca Hamilton

HOSPITAL NAME

Summit Dog and Cat
Hospital

REFERRING VET

Dr. Baker

INVOICE

70373

DATE

1/21/26

PRESENTING CLINICAL SIGNS

- Liver enzyme elevation diagnostics
- dental tartar, SQ masses, Epithelial masses
- Meds: Denamarin
- Alkp 318, inc. since 7/1/25 (ALK 295) Urine: Blood trace, USG 1.045

ULTRASONOGRAPHIC EXAMINATION OF THE ABDOMEN

Urinary System

The **urinary bladder**, trigone, and pelvic urethra presented normal thicknesses and normal tone. The pelvic urethra was imaged 3.0 cm beyond the cystourethral junction and appeared normal. The ureters were not visible which is normal. No uroliths or sediment were visualized and anechoic urine was present. No evidence of inflammatory or neoplastic changes was noted. Ureteral papillae were normal.

The **kidneys** revealed largely normal size and structure, corticomedullary definition and ratio (cortex 1/3 of medulla) were essentially maintained with some age-related loss of curvilinear patterns regarding the capsule and C/M junction. The cortices presented largely uniform texture with some increased echogenicity expected for this age patient. Medullary structure differed distinctly from that of the cortex and no evidence of pelvic dilation was present. The right kidney measured 4.75 cm. The left kidney measured 4.91 cm.

The residual prostate measured 0.8 cm.

Adrenal Glands

Both **adrenal glands** were visualized and recognized as having normal shape, size, position and echogenicity for this breed. The phrenic vasculature, glandular echogenicity and detail were unremarkable. Capsule, cortex, and medullary definition were normal for this age patient. The left adrenal gland measured 1.9 x 0.82 cm at the cranial pole and 0.65 cm at the caudal pole. The right adrenal gland measured 2.82 x 0.86 cm at the cranial pole and 0.6 cm at the caudal pole.

Spleen

The **spleen** presented a smooth homogeneous parenchyma hyperechoic to liver and renal cortical parenchyma. The capsule was smooth without noticeable expansion or deviation from within the spleen or adjacent pathology. The splenic vasculature demonstrated normal volume without signs of congestion or thrombosis. No sonographic evidence of acute or chronic inflammatory, neoplastic, or infarctual changes was noted.

Liver

The **liver** images from right and left intercostal as well as subcostal views revealed subjectively normal liver size, contour, and structure. Some age-related parenchymal remodeling was noted but likely not



PATIENT

Skippy Strauss

SPECIES

Canine

BREED

Beagle Mix

SEX

Neutered male

AGE

10 year

WEIGHT

-

INTERPRETED BY

Eric Lindquist, DMV
DABVP, Cert. IVUSS

IMAGING PERFORMED BY

Rebecca Hamilton

HOSPITAL NAME

Summit Dog and Cat
Hospital

REFERRING VET

Dr. Baker

INVOICE

70373

DATE

1/21/26

clinically significant at this time. Vascular and biliary tracts were of normal volume and no evidence of congestion was noted. The gallbladder presented some dependent debris with essentially normal contour. The cystic and common bile ducts were normal. No overt evidence of active inflammatory, infiltrative or regenerative pathology was noted but should be paired with current or past LE elevations regarding any clinical significance to this presentation. The hepatic lymph nodes were unremarkable.

Gastrointestinal

Examination of the **gastrointestinal tract** revealed a stomach and intestine free of stasis, of normal wall thickness, acceptable curvilinear mural detail, and peristaltic activity. Small and large intestine demonstrated normal luminal chyme and stool consistency respectively. No obstructive or overt infiltrative disease was noted. No associated abnormal lymphatic activity was noted.

Pancreas

The base and limbs of the **pancreas** were observed to be largely isoechoic to surrounding omental fat. Some parenchymal remodeling, however, with mild deviation from curvilinear normalcy was observed. Pancreatic duct and capsular irregularities were present consistent with age related changes. If pain upon imaging (+ Murphy sign) was present or if the patient is focally painful in subxiphoid palpation then low-grade smoldering chronic pancreatitis should be suspected.

ULTRASONOGRAPHIC FINDINGS

Non-specific, age related hepatic changes, likely low grade inflammatory hepatopathy or reactive hepatopathy.
Age related pancreatic changes.

INTERPRETATION OF THE FINDINGS & FURTHER RECOMMENDATIONS

FNA of the liver is recommended for further definition, yet subjectively appears benign. The patient was painful upon imaging around the right kidney, yet no visceral pathology was noted that would be responsible for pain response. Referred back pain should be considered as a potential.



PATIENT

Skippy Strauss

SPECIES

Canine

BREED

Beagle Mix

SEX

Neutered male

AGE

10 year

WEIGHT

-

INTERPRETED BY

Eric Lindquist, DMV
 DABVP, Cert. IVUSS

IMAGING PERFORMED BY

Rebecca Hamilton

HOSPITAL NAME

Summit Dog and Cat
 Hospital

REFERRING VET

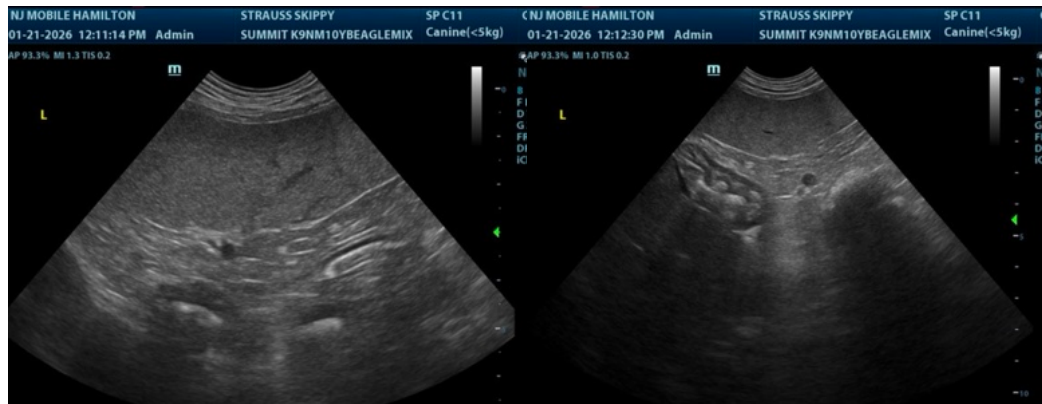
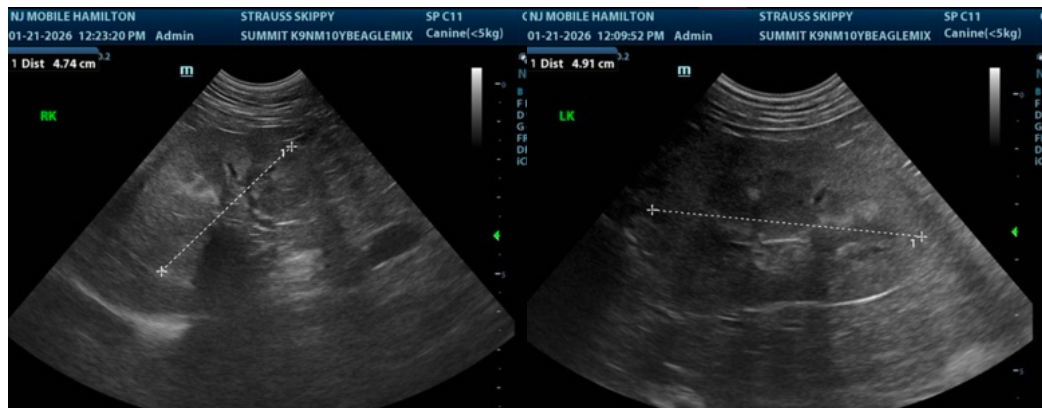
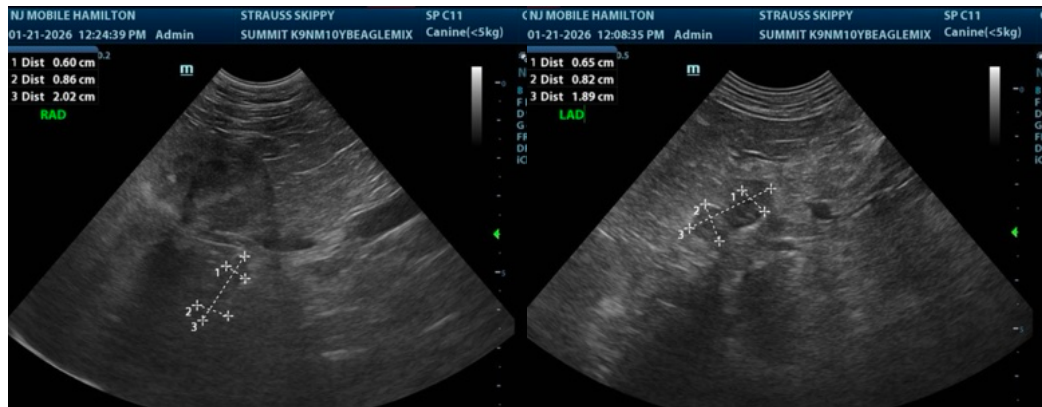
Dr. Baker

INVOICE

70373

DATE

1/21/26





PATIENT

Skippy Strauss

SPECIES

Canine

BREED

Beagle Mix

SEX

Neutered male

AGE

10 year

WEIGHT

-

INTERPRETED BY

Eric Lindquist, DMV
DABVP, Cert. IVUSS

IMAGING PERFORMED BY

Rebecca Hamilton

HOSPITAL NAME

Summit Dog and Cat
Hospital

REFERRING VET

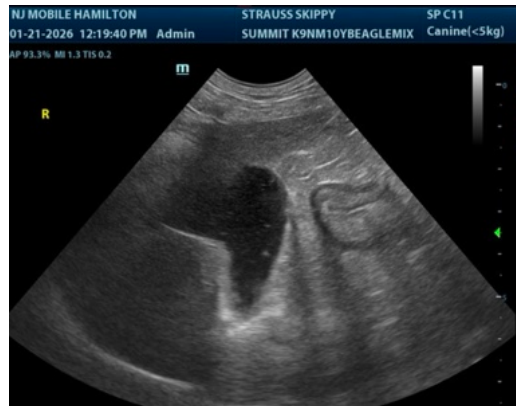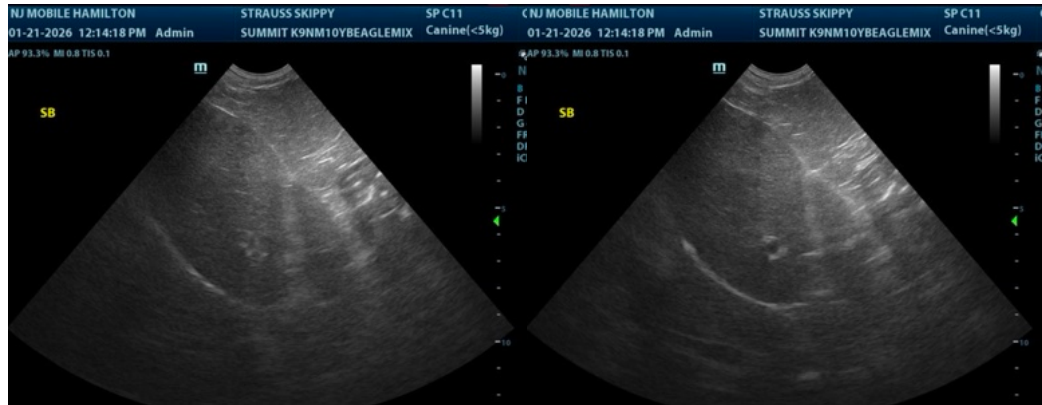
Dr. Baker

INVOICE

70373

DATE

1/21/26



The information and recommendations provided are based on the images presented by the referring veterinarian/sonographer. No evaluation can be communicated regarding pathology that was not visible in the image/video clips provided.

Thank you for this referral. If the clinical or image interpretation does not parallel your findings or if I can be of any further assistance please contact me.

Eric Lindquist, DMV, DABVP, Cert. IVUSS, CEO of SonoPath.com

info@SonoPath.com