



PATIENT

Appa Slack

SPECIES

Canine

BREED

Golden Retriever

SEX

Neutered male

AGE

8 years

WEIGHT

67.6 lbs

PRESENTING CLINICAL SIGNS

Heart murmur grade I-II/VI.

Normal PE exam

ULTRASONOGRAPHIC EXAMINATION OF THE HEART

The echocardiogram in this patient demonstrated normal **left atrial** size based on 3 separate methods of LA evaluation. The cranial and caudal **mitral** valve leaflets presented normal linear structure, extension in systole, and union in diastole with normal kinesis. The **left ventricle** presented thicknesses with linear contour and was not dilated nor restricted. The **myocardium** presented normal echogenicity without subjective evidence of significant fibrotic or ischemic disease. **Contractility** of the ventricular walls was adequate and in normal range for this patient evidenced by the fractional shortening measurement and subjective evaluation of the different regions of the myocardium. Mild increased idiopathic **left ventricular outflow** tract was noted. The **right atrium** and auricle revealed normal size, structure and content. No evidence of masses was noted. **Tricuspid** valvular assessment demonstrated adequate linear morphology and kinesis. The **right ventricle** was of normal size (1/3 diameter of LV), chordae structure, myocardial echogenicity and thickness. **Pulmonary outflow** tract assessment revealed normal valve structure, laminar flow, and diameter (approx. 1:1 pa/ao ratio). No visible **pericardial** or free pleura fluid was noted. The cranial **mediastinum and pericardial and extra-cardiac regions** were free of masses in the visible window.

INTERPRETED BY

Eric Lindquist, DMV,
 DABVP, Cert. IVUSS,
 CEO of SonoPath.com

IMAGING PERFORMED BY

Eric Lindquist, DMV,
 DABVP, Cert. IVUSS,
 CEO of SonoPath.com

HOSPITAL NAME

Greenwood Lake AH

REFERRING VET

Dr. Lauer

INVOICE

70300

DATE

1/20/26

ULTRASONOGRAPHIC FINDINGS

- Mildly increased idiopathic LVOT, not clinically significant.
- Mild flow murmur.

CANINE CARDIAC PARAMETERS	MR VMAX (m/s)	TR VMAX (m/s)	LA/AO	LA/AO (Heart Base)	FS (%)	EF (%)	EPSS (cm)
NORMAL PARAMETER	4.5-5.5	<2.7	1.3	<1.6	28-40	40-100	<0.6
PATIENT	-	-	1.0	1.3	41	73	NM
CANINE CARDIAC PARAMETERS	HR (BPM)	AV VMAX (m/s)	PV MAX (m/s)	BODY WEIGHT	LA 2D short axis Base view (cm)	LVIDd Avg; 2D and m-mode short axis (cm)	LVIDs Avg; 2D and m-mode short axis (cm)
NORMAL PARAMETER	50-100	0.7-1.7	0.7-1.6	BELOW	BELOW	BELOW	BELOW
PATIENT	170	2.2-2.4	1.34	67.6 lbs	3.1	3.15	



PATIENT

Appa Slack

SPECIES

Canine

BREED

Golden Retriever

SEX

Neutered male

AGE

8 years

WEIGHT

67.6 lbs

INTERPRETED BY

Eric Lindquist, DMV,
 DABVP, Cert. IVUSS,
 CEO of SonoPath.com

IMAGING PERFORMED BY

Eric Lindquist, DMV,
 DABVP, Cert. IVUSS,
 CEO of SonoPath.com

HOSPITAL NAME

Greenwood Lake AH

REFERRING VET

Dr. Lauer

INVOICE

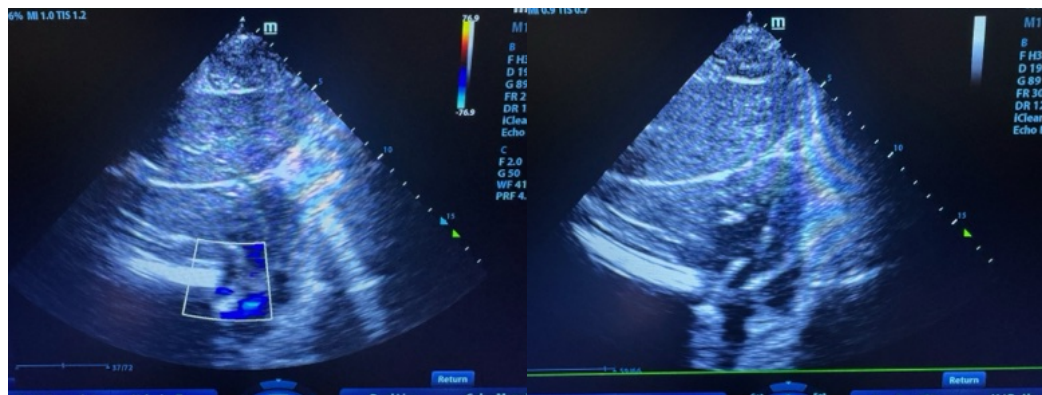
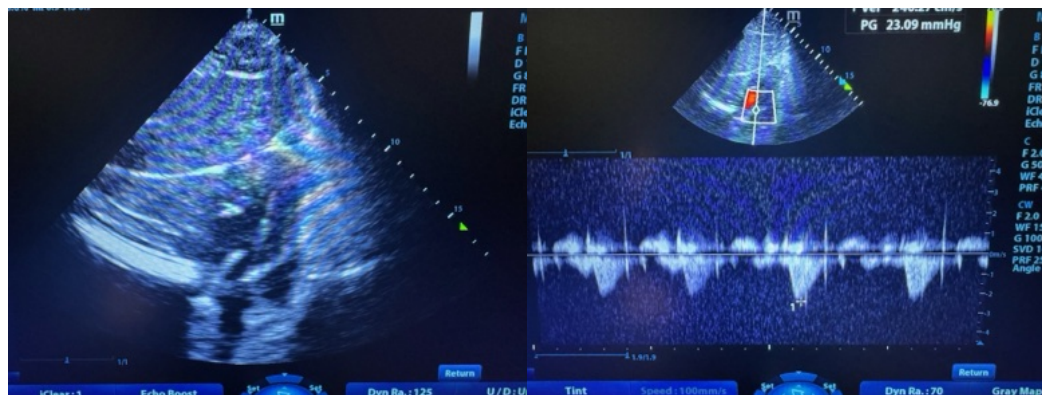
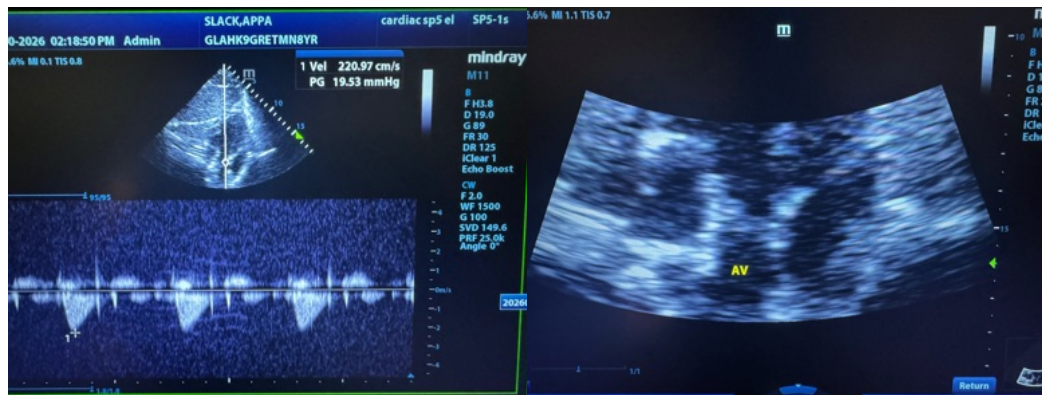
70300

DATE

1/20/26

INTERPRETATION OF THE FINDINGS & FURTHER RECOMMENDATIONS

There was no structural evidence of subaortic stenosis. There was no evidence of clinical disease, benign change.





PATIENT

Appa Slack

SPECIES

Canine

BREED

Golden Retriever

SEX

Neutered male

AGE

8 years

WEIGHT

67.6 lbs

INTERPRETED BY

Eric Lindquist, DMV,
 DABVP, Cert. IVUSS,
 CEO of SonoPath.com

IMAGING PERFORMED BY

Eric Lindquist, DMV,
 DABVP, Cert. IVUSS,
 CEO of SonoPath.com

HOSPITAL NAME

Greenwood Lake AH

REFERRING VET

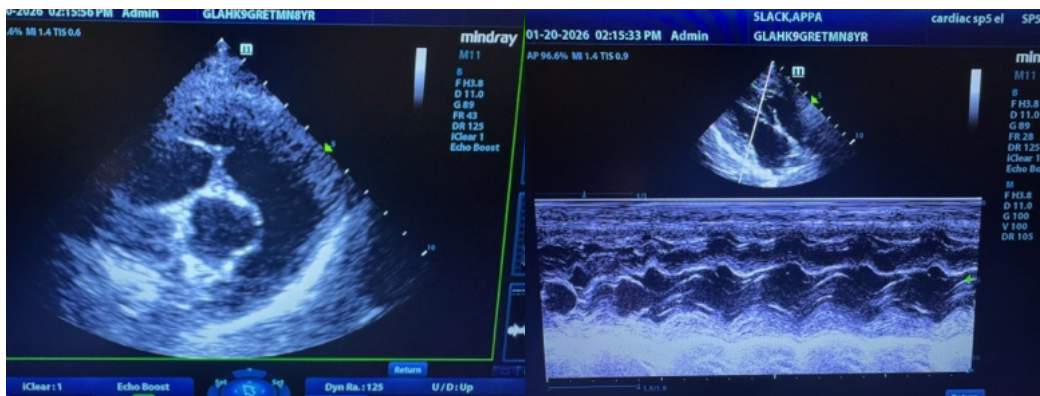
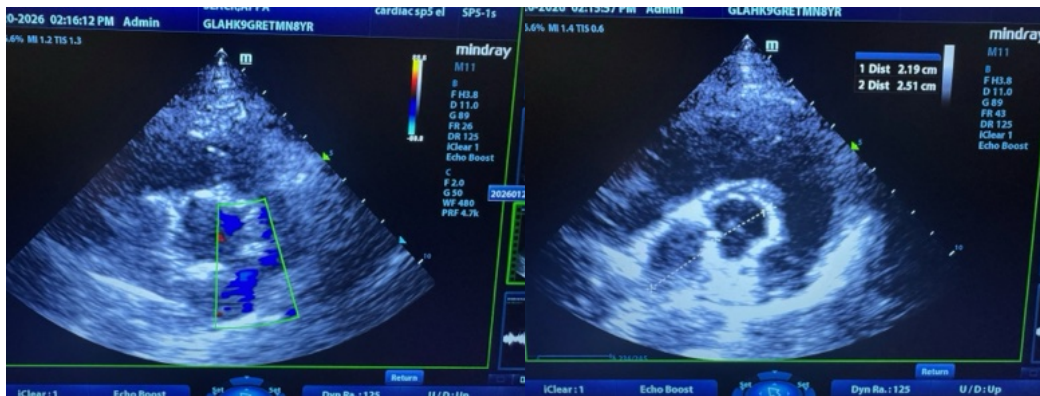
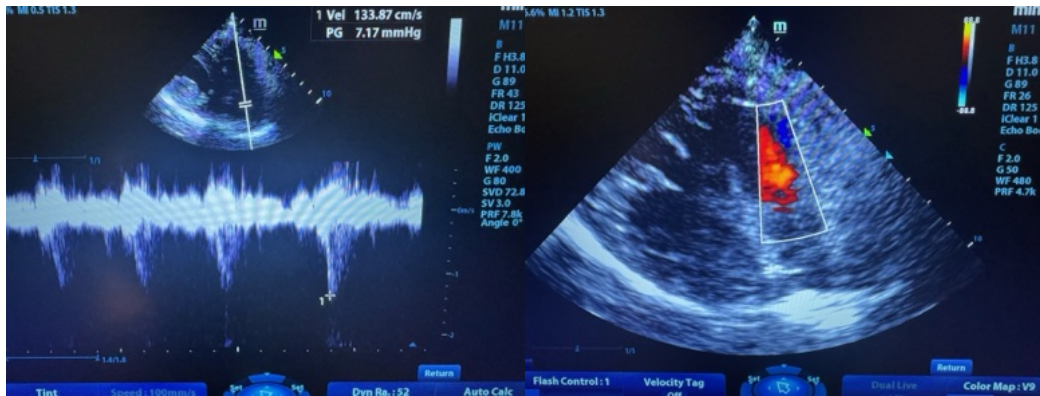
Dr. Lauer

INVOICE

70300

DATE

1/20/26





PATIENT

Appa Slack

SPECIES

Canine

BREED

Golden Retriever

SEX

Neutered male

AGE

8 years

WEIGHT

67.6 lbs

INTERPRETED BY

Eric Lindquist, DMV,
 DABVP, Cert. IVUSS,
 CEO of SonoPath.com

IMAGING PERFORMED BY

Eric Lindquist, DMV,
 DABVP, Cert. IVUSS,
 CEO of SonoPath.com

HOSPITAL NAME

Greenwood Lake AH

REFERRING VET

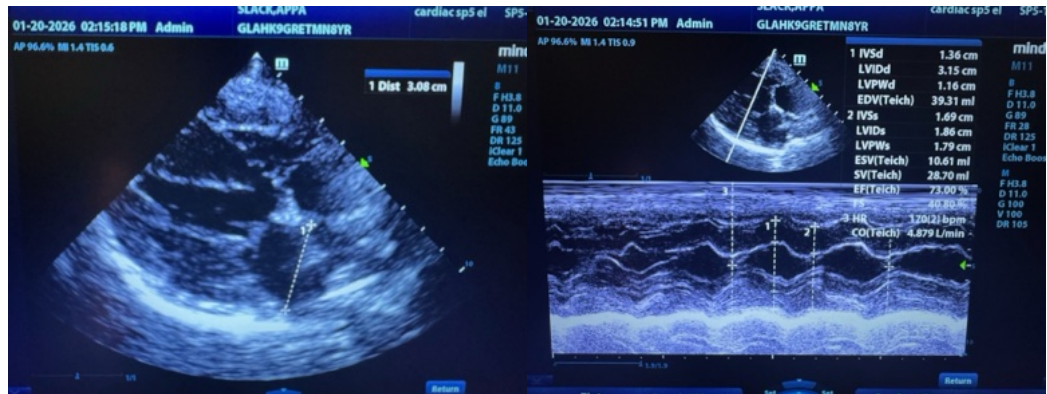
Dr. Lauer

INVOICE

70300

DATE

1/20/26



The information and recommendations provided are based on the images presented by the referring veterinarian/sonographer. No evaluation can be communicated regarding pathology that was not visible in the image/video clips provided.

Thank you for this referral. If the clinical or image interpretation does not parallel your findings or if I can be of any further assistance please contact me.

Eric Lindquist, DMV, DABVP, Cert. IVUSS, CEO of SonoPath.com

Info@SonoPath.com