



## PATIENT

Patrick Wagner

## SPECIES

Canine

## BREED

Golden Retriever

## SEX

Intact male

## AGE

9 years

## WEIGHT

71 lbs

## INTERPRETED BY

Eric Lindquist, DMV,  
DABVP, Cert. IVUSS,  
CEO of SonoPath.com

## IMAGING PERFORMED BY

Meghan Morse, LVT,  
CVT

## HOSPITAL NAME

Animal Hospital of  
Sussex County

## REFERRING VET

Dr. Lovell

## INVOICE

70265

## DATE

1/19/26

## PRESENTING CLINICAL SIGNS

- Recheck AUS to look at splenic nodules, clinically WNL

## ULTRASONOGRAPHIC EXAMINATION OF THE ABDOMEN

### *Urinary System*

The **urinary bladder**, trigone, and pelvic urethra presented normal thicknesses and normal tone. The ureters were not visible which is normal. No uroliths or sediment were visualized and anechoic urine was present. No evidence of inflammatory or neoplastic changes was noted. Ureteral papillae were normal.

The **kidneys** revealed normal size and structure, corticomedullary definition and ratio for this age. The cortices presented largely uniform texture with normal echogenic relationship to liver and spleen. Medullary structure differed distinctly from the cortex and no evidence of pelvic dilation was present. The capsules were acceptably uniform without significant irregularities. The right kidney measured 6.3 cm.

The **prostate** was uniformly enlarged with lobar swelling appeared to impinge upon the urethra and mildly deviate the descending colon. The prostatic tissue was hyperechoic containing focal areas of decreased echogenicity. These changes are suggestive of either chronic inflammatory episodes, benign cystic pathology or both. Underlying neoplasia cannot be completely ruled-out but is lower on the differential list. This presentation is most consistent with benign prostatic hyperplasia with possible active prostatitis. Neutering or off-label Finasteride (Propecia) (0.1-0.5 mg/kg Sid) treatment is indicated +/- FNA or prostatic wash cytology and culture. The prostate measured 3.0 cm.

The testicles were imaged and found to be uniform with no evidence of pathology.

### *Adrenal Glands*

Both **adrenal glands** were visualized and recognized as having normal shape, size, position and echogenicity for this breed. The phrenic vasculature, glandular echogenicity and detail were unremarkable. Capsule, cortex, and medullary definition were normal for this age patient. The right adrenal gland measured 3.16 x 1.1 cm at the cranial pole and 0.51 cm at the caudal pole. The left adrenal gland measured 2.42 x 0.9 cm at the cranial pole and 0.68 cm at the caudal pole.

### *Spleen*

The **spleen** had a nodule in the midbody measuring 0.75 cm. There was no progression. A separate nodule measured 0.69 cm at the mid caudal body.

### *Liver*

The **liver** images from right and left intercostal as well as subcostal views revealed subjectively normal liver size, contour, and structure. Some age-related parenchymal remodeling was noted but likely not clinically significant at this time. Vascular and biliary tracts were of normal volume and no evidence of



**PATIENT**

Patrick Wagner

**SPECIES**

Canine

**BREED**

Golden Retriever

**SEX**

Intact male

**AGE**

9 years

**WEIGHT**

71 lbs

**INTERPRETED BY**

Eric Lindquist, DMV,  
DABVP, Cert. IVUSS,  
CEO of SonoPath.com

**IMAGING PERFORMED BY**

Meghan Morse, LVT,  
CVT

**HOSPITAL NAME**

Animal Hospital of  
Sussex County

**REFERRING VET**

Dr. Lovell

**INVOICE**

70265

**DATE**

1/19/26

congestion was noted. The gallbladder presented some dependent debris with essentially normal contour. The cystic and common bile ducts were normal. No overt evidence of active inflammatory, infiltrative or regenerative pathology was noted but should be paired with current or past LE elevations regarding any clinical significance to this presentation. The hepatic lymph nodes were unremarkable.

**Gastrointestinal**

Examination of the **gastrointestinal tract** revealed a stomach and intestine free of stasis, of normal wall thickness, acceptable curvilinear mural detail, and peristaltic activity. Small and large intestine demonstrated normal luminal chyme and stool consistency respectively. No obstructive or overt infiltrative disease was noted. No associated abnormal lymphatic activity was noted.

**Pancreas**

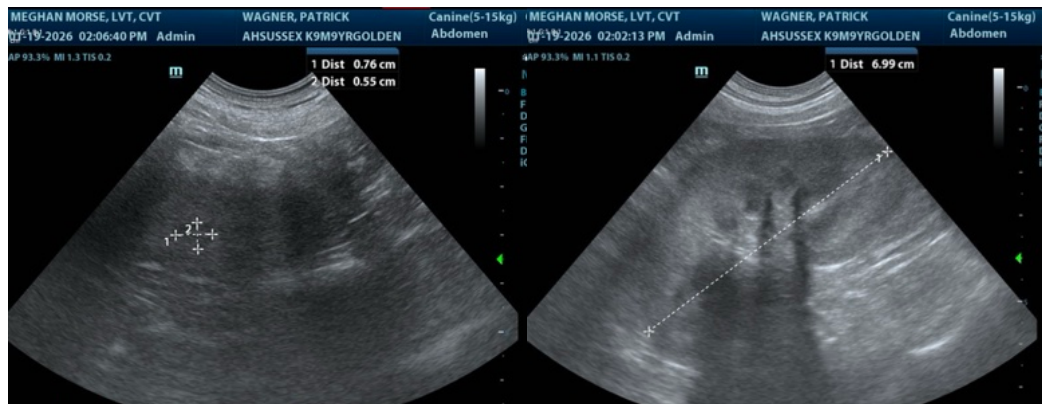
The base and limbs of the **pancreas** were observed to be largely isoechoic to surrounding omental fat. Pancreatic duct and capsular contour were acceptably normal and parenchyma respected normal curvilinear patterns. No overt evidence of active inflammatory or neoplastic disease was noted.

**ULTRASONOGRAPHIC FINDINGS**

Stable splenic nodules.

**INTERPRETATION OF THE FINDINGS & FURTHER RECOMMENDATIONS**

There was no evidence of progression. A recheck sonogram is recommended at the practitioners discretion. This is most consistent with hyperplasia; however, pre-neoplastic state cannot be completely ruled out.





**PATIENT**

Patrick Wagner

**SPECIES**

Canine

**BREED**

Golden Retriever

**SEX**

Intact male

**AGE**

9 years

**WEIGHT**

71 lbs

**INTERPRETED BY**

Eric Lindquist, DMV,  
 DABVP, Cert. IVUSS,  
 CEO of SonoPath.com

**IMAGING PERFORMED BY**

Meghan Morse, LVT,  
 CVT

**HOSPITAL NAME**

Animal Hospital of  
 Sussex County

**REFERRING VET**

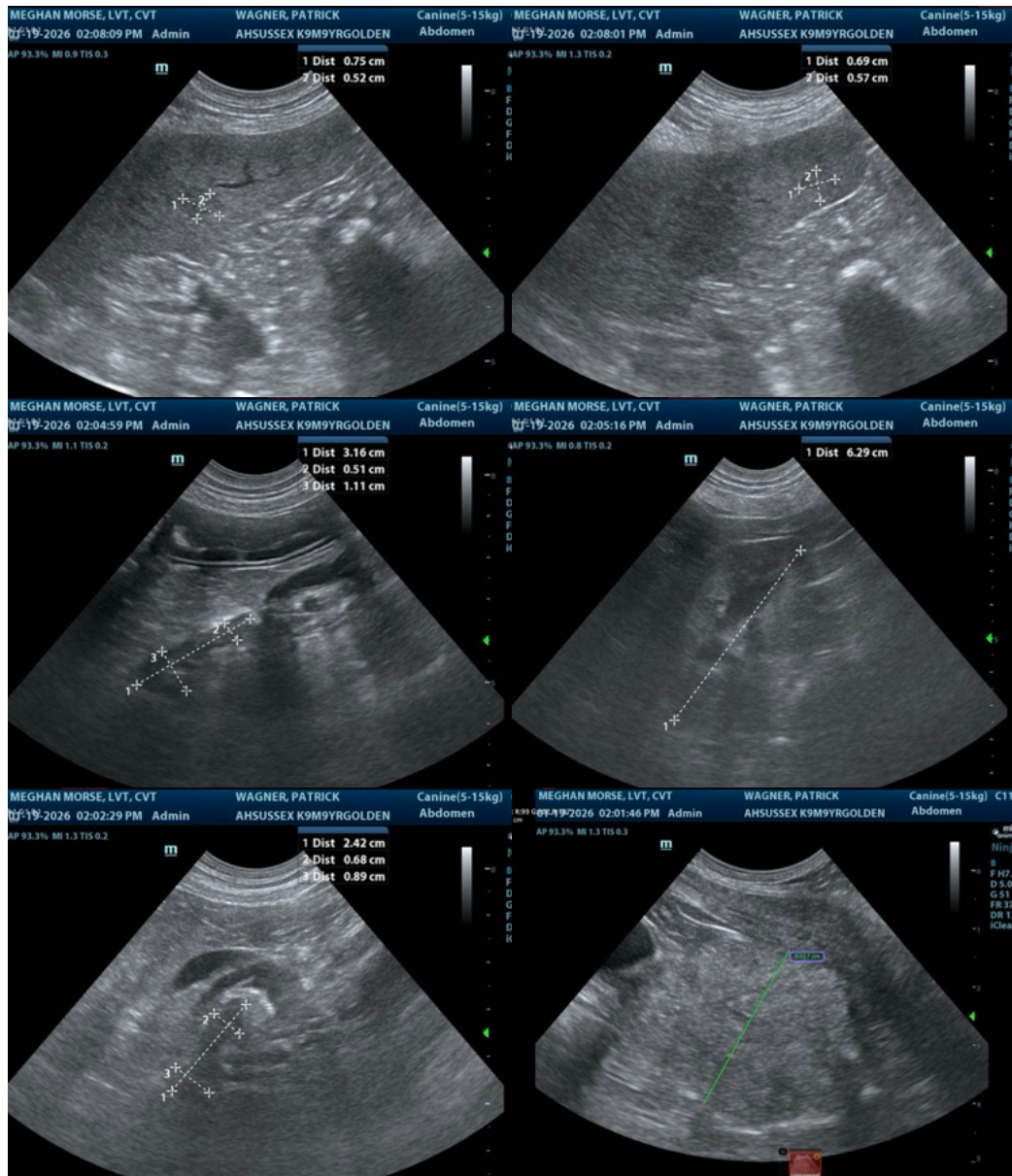
Dr. Lovell

**INVOICE**

70265

**DATE**

1/19/26





**PATIENT**

Patrick Wagner

**SPECIES**

Canine

**BREED**

Golden Retriever

**SEX**

Intact male

**AGE**

9 years

**WEIGHT**

71 lbs

**INTERPRETED BY**

Eric Lindquist, DMV,  
DABVP, Cert. IVUSS,  
CEO of SonoPath.com

**IMAGING  
PERFORMED BY**

Meghan Morse, LVT,  
CVT

**HOSPITAL NAME**

Animal Hospital of  
Sussex County

**REFERRING VET**

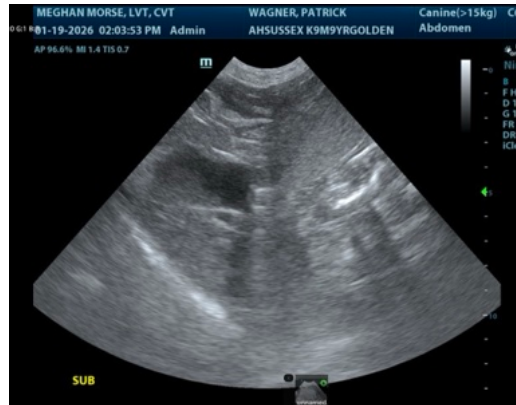Dr. Lovell

**INVOICE**

70265

**DATE**

1/19/26



The information and recommendations provided are based on the images presented by the referring veterinarian/sonographer. No evaluation can be communicated regarding pathology that was not visible in the image/video clips provided.

Thank you for this referral. If the clinical or image interpretation does not parallel your findings or if I can be of any further assistance please contact me.

Eric Lindquist, DMV, DABVP, Cert. IVUSS, CEO of SonoPath.com

Info@SonoPath.com