



PATIENT

Abe Goldberg

SPECIES

Feline

BREED

Domestic Shorthair

SEX

Neutered male

AGE

7 years

WEIGHT

10 lbs

INTERPRETED BY

Eric Lindquist, DMV,
DABVP, Cert. IVUSS,
CEO of SonoPath.com

IMAGING PERFORMED BY

Meghan Morse, LVT,
CVT

HOSPITAL NAME

Loving Care VH

REFERRING VET

Dr. Steele

INVOICE

70264

DATE

1/19/26

PRESENTING CLINICAL SIGNS

- Suspect cystic calculus
- 36 hrs not eating- r/o mass

ULTRASONOGRAPHIC EXAMINATION OF THE ABDOMEN

Urinary System

The **urinary bladder**, trigone, and pelvic urethra presented normal thicknesses and normal tone. The ureters were not visible which is normal. The proximal urethra revealed a slight calculus measuring 0.15 cm. No evidence of inflammatory or neoplastic changes was noted. Ureteral papillae were normal.

The **kidneys** revealed normal size and structure, corticomedullary definition and ratio for this age. The cortices presented largely uniform texture with normal echogenic relationship to liver and spleen. Medullary structure differed distinctly from the cortex and no evidence of pelvic dilation was present. The capsules were acceptably uniform without significant irregularities. Slight pinpoint renal mineralization was noted. The left kidney measured 3.62 cm. The right kidney measured 3.91 cm.

Adrenal Glands

Both **adrenal glands** were visualized and recognized as having normal shape, size, position and echogenicity for this breed. The phrenic vasculature, glandular echogenicity and detail were unremarkable. Capsule, cortex, and medullary definition were normal for this age patient. The right adrenal gland measured 0.4 cm. The left adrenal gland measured 0.5 cm.

Spleen

The **spleen** presented a smooth homogeneous parenchyma hyperechoic to liver and renal cortical parenchyma. The capsule was smooth without noticeable expansion or deviation from within the spleen or adjacent pathology. The splenic vasculature demonstrated normal volume without signs of congestion or thrombosis. No sonographic evidence of acute or chronic inflammatory, neoplastic, or infarctual changes was noted.

Liver

The **liver** images submitted revealed subjectively normal liver size, contour, and structure. Parenchymal echogenicity was naturally coarse and hypoechoic to the spleen. Vascular and biliary tracts were of normal volume with no evidence of congestion. The gallbladder presented acceptably thin walls with primarily anechoic content. The cystic and common bile ducts were normal. No pathological hepatic lymphadenopathy was evident. No overt structural evidence of inflammatory, infiltrative or regenerative pathology was evident.



PATIENT

Abe Goldberg

SPECIES

Feline

BREED

Domestic Shorthair

SEX

Neutered male

AGE

7 years

WEIGHT

10 lbs

INTERPRETED BY

Eric Lindquist, DMV,
DABVP, Cert. IVUSS,
CEO of SonoPath.com

IMAGING PERFORMED BY

Meghan Morse, LVT,
CVT

HOSPITAL NAME

Loving Care VH

REFERRING VET

Dr. Steele

INVOICE

70264

DATE

1/19/26

Gastrointestinal

Examination of the **gastrointestinal tract** revealed a stomach and intestine free of stasis, of normal wall thickness, acceptable curvilinear mural detail, and peristaltic activity. Small and large intestine demonstrated normal luminal chyme and stool consistency respectively. No obstructive or overt infiltrative disease was noted. No associated abnormal lymphatic activity was noted.

Pancreas

The base and limbs of the **pancreas** were observed to be largely isoechoic to surrounding omental fat. Pancreatic duct and capsular contour were acceptably normal and parenchyma respected normal curvilinear patterns. No overt evidence of active inflammatory or neoplastic disease was noted.

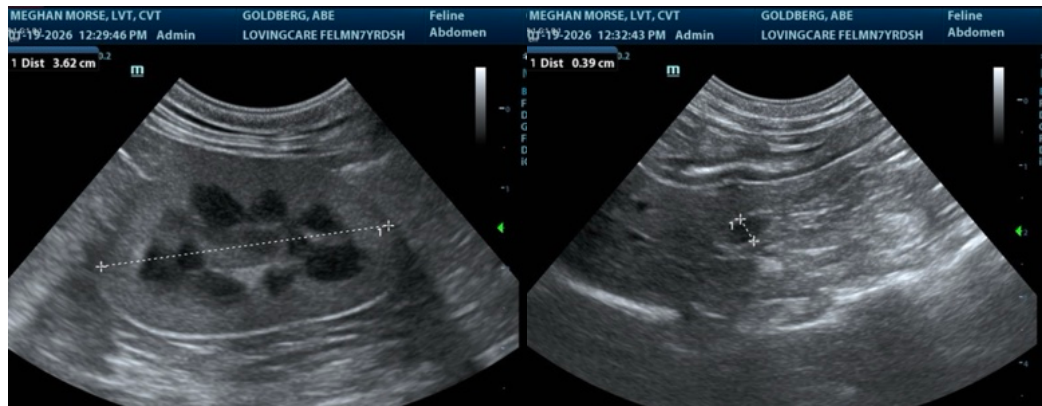
ULTRASONOGRAPHIC FINDINGS

Slight, small proximal urethral sand granule, stable. This was lodged approximately 1.0 cm distal from the cystourethral junction. However, this is exceedingly small.

Otherwise, unremarkable abdomen.

INTERPRETATION OF THE FINDINGS & FURTHER RECOMMENDATIONS

The patient is likely passing sand granule periodically from the kidneys to the lower urinary tract. If clinical signs of straining are present, then cystotomy with retrograde flush is recommended. Intervention is based on any clinical abnormalities of straining.





PATIENT

Abe Goldberg

SPECIES

Feline

BREED

Domestic Shorthair

SEX

Neutered male

AGE

7 years

WEIGHT

10 lbs

INTERPRETED BY

Eric Lindquist, DMV,
 DABVP, Cert. IVUSS,
 CEO of SonoPath.com

IMAGING PERFORMED BY

Meghan Morse, LVT,
 CVT

HOSPITAL NAME

Loving Care VH

REFERRING VET

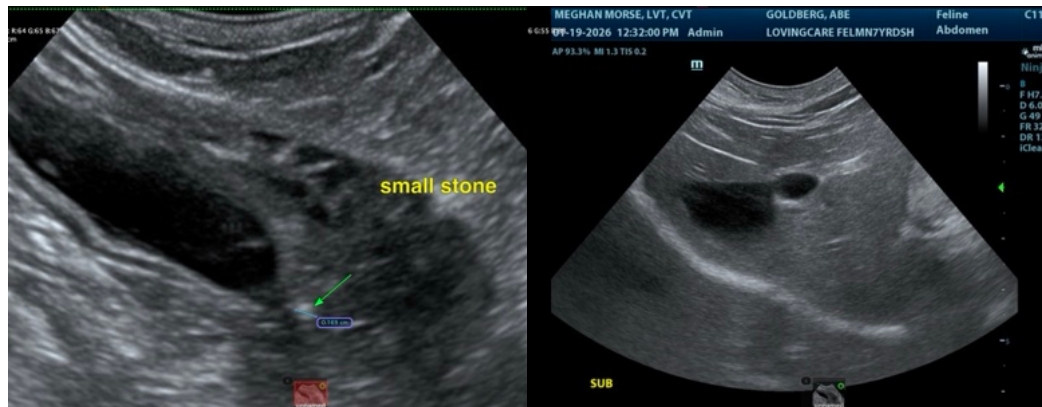
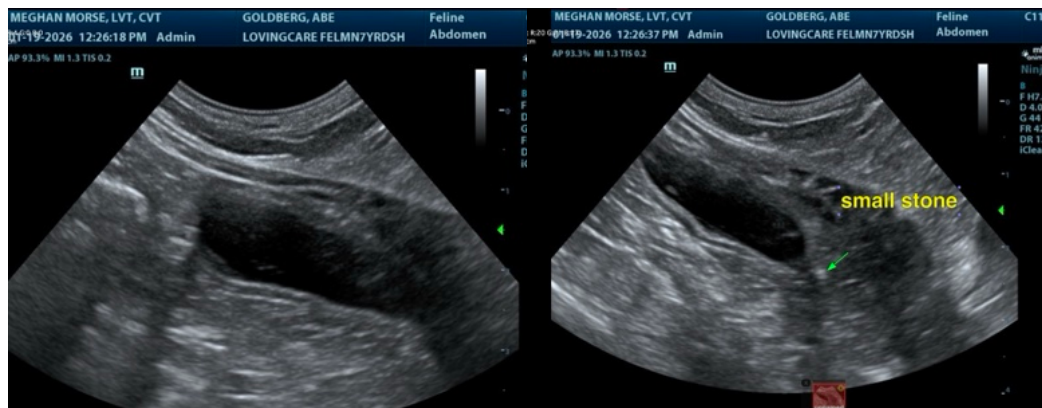
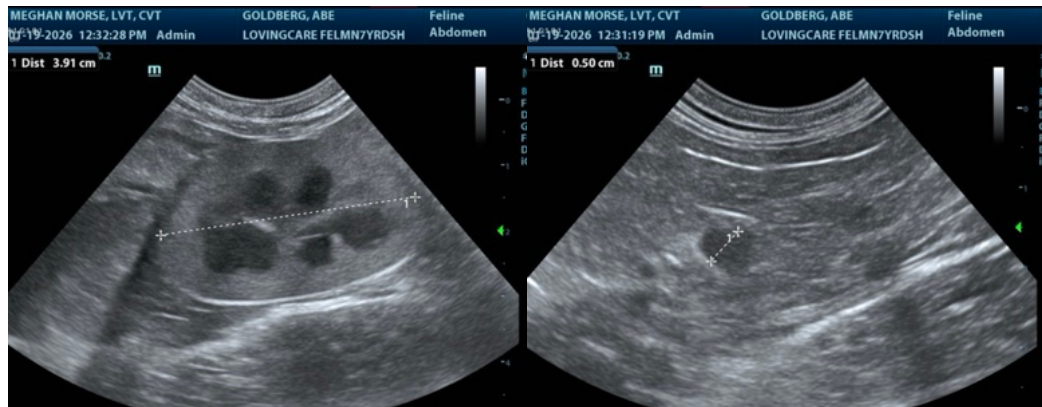
Dr. Steele

INVOICE

70264

DATE

1/19/26





PATIENT

Abe Goldberg

SPECIES

Feline

BREED

Domestic Shorthair

SEX

Neutered male

AGE

7 years

WEIGHT

10 lbs

INTERPRETED BY

Eric Lindquist, DMV,
DABVP, Cert. IVUSS,
CEO of SonoPath.com

**IMAGING
PERFORMED BY**

Meghan Morse, LVT,
CVT

HOSPITAL NAME

Loving Care VH

REFERRING VET

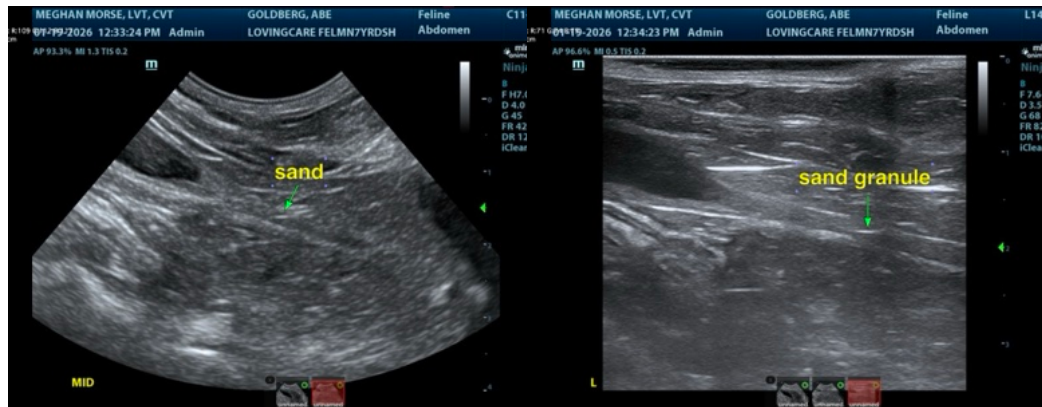
Dr. Steele

INVOICE

70264

DATE

1/19/26



The information and recommendations provided are based on the images presented by the referring veterinarian/sonographer. No evaluation can be communicated regarding pathology that was not visible in the image/video clips provided.

Thank you for this referral. If the clinical or image interpretation does not parallel your findings or if I can be of any further assistance please contact me.

Eric Lindquist, DMV, DABVP, Cert. IVUSS, CEO of SonoPath.com

Info@SonoPath.com