



PATIENT

Hunter Lawn

SPECIES

Canine

BREED

Labradoodle

SEX

Neutered male

AGE

8 years

WEIGHT

45 lbs

PRESENTING CLINICAL SIGNS

History: Chronic Vomiting with blood Clinical findings: For a few wks V+ on/off in the morning. Progressed to having blood in it. Lost weight past few wks.

Abnormal PE/Chem/CBC/UA Results: WNL 12/29 including CPL

ULTRASONOGRAPHIC EXAMINATION OF THE ABDOMEN

Urinary System

The **urinary bladder**, trigone, and pelvic urethra presented normal thicknesses and normal tone. The pelvic urethra was imaged 3.0 cm beyond the cystourethral junction and appeared normal. The ureters were not visible which is normal. No uroliths or sediment were visualized and anechoic urine was present. No evidence of inflammatory or neoplastic changes was noted. Ureteral papillae were normal.

The **kidneys** revealed normal size and structure, corticomedullary definition and ratio for this age. The cortices presented largely uniform texture with normal echogenic relationship to liver and spleen. Medullary structure differed distinctly from the cortex and no evidence of pelvic dilation was present. The capsules were acceptably uniform without significant irregularities. The right kidney measured 5.07 cm. the left kidney measured 6.25 cm.

The residual prostate was noted and measured 1.0 cm.

INTERPRETED BY

Eric Lindquist, DMV,
DABVP (CFM), Cert.
IVUSS, CEO of
SonoPath.com

IMAGING PERFORMED BY

Vincent Ravancho,
CVT

HOSPITAL NAME

Park Ridge AH

REFERRING VET

Dr. Doyle

INVOICE

70120

DATE

1/14/26

Adrenal Glands

Both **adrenal glands** were visualized and recognized as having normal shape, size, position and echogenicity for this breed. The phrenic vasculature, glandular echogenicity and detail were unremarkable. Capsule, cortex, and medullary definition were normal for this age patient. The left adrenal gland measured 2.12 x 0.43 cm at the cranial pole and 0.45 cm at the caudal pole. The right adrenal gland measured 1.8 x 0.96 cm at the cranial pole and 0.52 cm at the caudal pole.

Spleen

The **spleen** in this patient was mildly enlarged with uniform parenchyma and was folded upon itself caudally. This is a positional variant and is not pathological. There was no evidence of significant disease.

Liver

The **liver** images submitted revealed subjectively normal liver size, contour, and structure. Parenchymal echogenicity was naturally coarse and hypoechoic to the spleen. Vascular and biliary tracts were of normal volume with no evidence of congestion. The gallbladder presented acceptably thin walls with primarily anechoic content. The cystic and common bile ducts were normal. No pathological hepatic lymphadenopathy was evident. No overt structural evidence of inflammatory, infiltrative or regenerative pathology was evident.



PATIENT

Hunter Lawn

SPECIES

Canine

BREED

Labradoodle

SEX

Neutered male

AGE

8 years

WEIGHT

45 lbs

INTERPRETED BY

Eric Lindquist, DMV,
DABVP (CFM), Cert.
IVUSS, CEO of
SonoPath.com

**IMAGING
PERFORMED BY**

Vincent Ravancho,
CVT

HOSPITAL NAME

Park Ridge AH

REFERRING VET

Dr. Doyle

INVOICE

70120

DATE

1/14/26

Gastrointestinal

Examination of the **gastrointestinal tract** revealed a stomach and intestine free of stasis, of normal wall thickness, acceptable curvilinear mural detail, and peristaltic activity. A minor amount of fluid filled lumen was noted. This is consistent with low-grade gastritis, yet no evidence of neoplasia or foreign body. Small and large intestine demonstrated normal luminal chyme and stool consistency respectively. No obstructive or overt infiltrative disease was noted. No associated abnormal lymphatic activity was noted.

Pancreas

The base and limbs of the **pancreas** were observed to be largely isoechoic to surrounding omental fat. Some parenchymal remodeling, however, with mild deviation from curvilinear normalcy was observed. Pancreatic duct and capsular irregularities were present consistent with age related changes. If pain upon imaging (+ Murphy sign) was present or if the patient is focally painful in subxiphoid palpation then low-grade smoldering chronic pancreatitis should be suspected.

ULTRASONOGRAPHIC FINDINGS

Slightly fluid filled gastric lumen, low-grade gastritis. No evidence of neoplasia or foreign body.

Otherwise unremarkable abdomen.

INTERPRETATION OF THE FINDINGS & FURTHER RECOMMENDATIONS

There was no evidence of visceral pathology.

Maldigestion panel, three view chest radiographs and full CNS examination is recommended to examine for occult disease that could be responsible for the weight loss. Evaluation for competitive eating environments should also be considered.

A clinical trial of the following may prove effective.

Helicobacter/Gastritis protocol

A clinical trial of **Zithromax (Dogs: 5-10 mg/kg p.o. q24h. May increase dosing interval to q48h after 3-5 days of treatment)**, **Metronidazole (10-20 mg/kg p.o. b.i.d.)**, **Pepcid (0.5-1 mg/kg s.i.d.)** and **Sucralfate (0.5-2 g/dog PO)** or **Omeprazole (1 mg/kg p.o. s.i.d.)** over the next 3 weeks along with a **novel-protein or hydrolyzed diet** with slurry feeding b.i.d./t.i.d. over the next 2-4 days and then increase to canned diet bid. Dry food should be avoided over the next 4 weeks. A recheck sonogram to assess GI improvement or progression would be ideal in 4 weeks.



PATIENT

Hunter Lawn

SPECIES

Canine

BREED

Labradoodle

SEX

Neutered male

AGE

8 years

WEIGHT

45 lbs

INTERPRETED BY

Eric Lindquist, DMV,
 DABVP (CFM), Cert.
 IVUSS, CEO of
 SonoPath.com

IMAGING PERFORMED BY

Vincent Ravancho,
 CVT

HOSPITAL NAME

Park Ridge AH

REFERRING VET

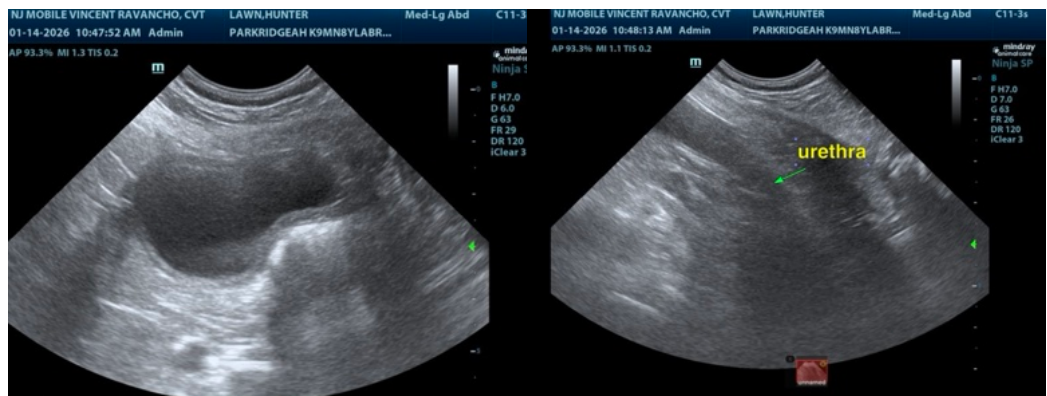
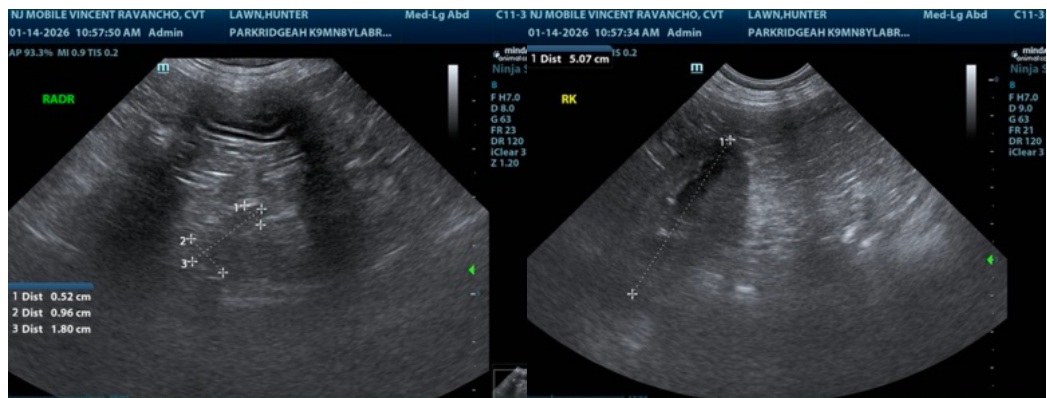
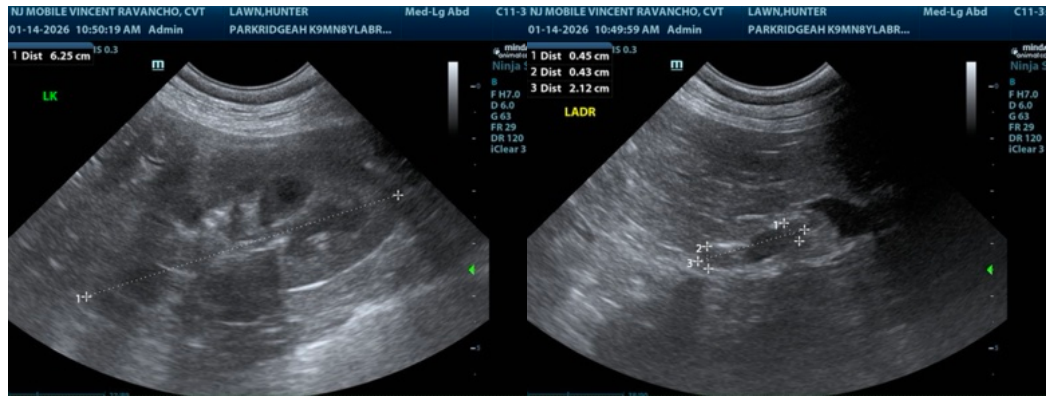
Dr. Doyle

INVOICE

70120

DATE

1/14/26





PATIENT

Hunter Lawn

SPECIES

Canine

BREED

Labradoodle

SEX

Neutered male

AGE

8 years

WEIGHT

45 lbs

INTERPRETED BY

Eric Lindquist, DMV,
DABVP (CFM), Cert.
IVUSS, CEO of
SonoPath.com

IMAGING PERFORMED BY

Vincent Ravancho,
CVT

HOSPITAL NAME

Park Ridge AH

REFERRING VET

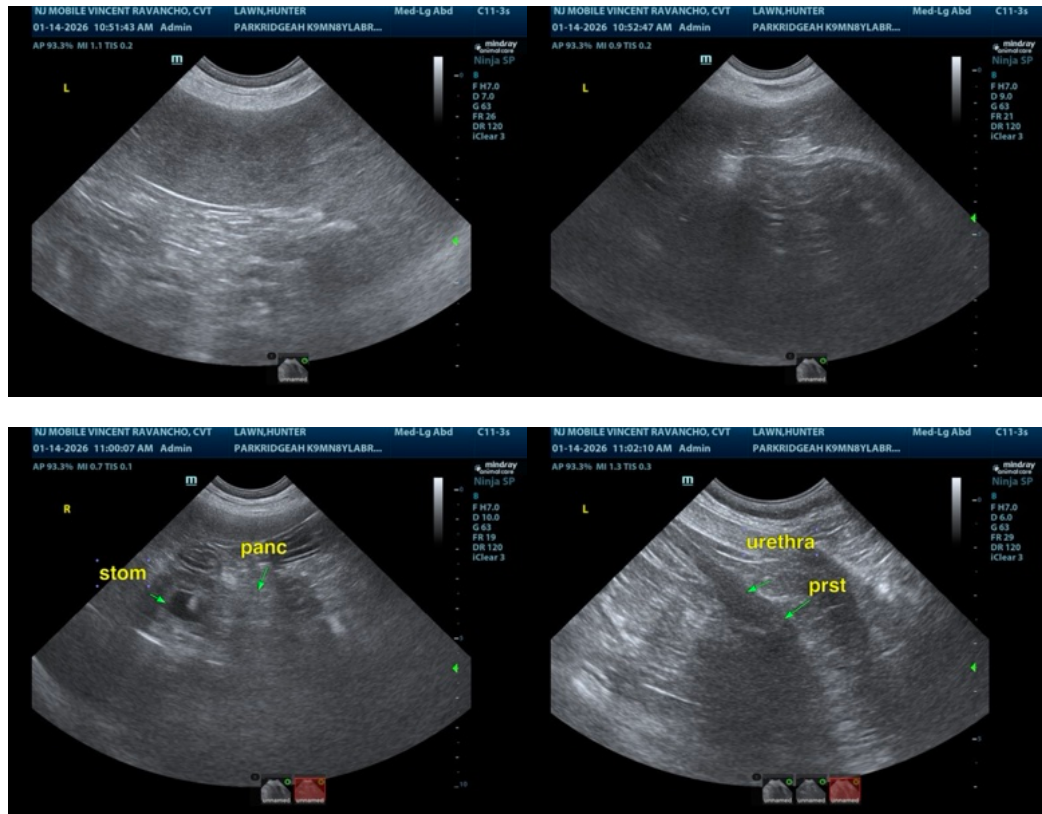
Dr. Doyle

INVOICE

70120

DATE

1/14/26



The information and recommendations provided are based on the images presented by the referring veterinarian/sonographer. No evaluation can be communicated regarding pathology that was not visible in the image/video clips provided.

Thank you for this referral. If the clinical or image interpretation does not parallel your findings or if I can be of any further assistance please contact me.

Eric Lindquist, DMV, DABVP (CFM), Cert. IVUSS, CEO of SonoPath.com

Info@SonoPath.com