



PATIENT

Midnight Center for
Animal Health

SPECIES

Canine

BREED

Mix

SEX

Neutered male

AGE

3 months

WEIGHT

15.5 lbs

INTERPRETED BY

Eric Lindquist, DMV,
DABVP, Cert. IVUSS,
CEO of SonoPath.com

IMAGING PERFORMED BY

Shari Reffi, CVT

HOSPITAL NAME

William Penn VH

REFERRING VET

Dr. Abouemara

INVOICE

70087

DATE

1/13/26

PRESENTING CLINICAL SIGNS

History: Elevates LE. Current meds: Amoxi/Clav; Metro; Sucralfate
Abnormal PE/Chem/CBC/UA Results: ALT 352

ULTRASONOGRAPHIC EXAMINATION OF THE ABDOMEN

Urinary System

The **urinary bladder**, trigone, and pelvic urethra presented normal thicknesses and normal tone. The ureters were not visible which is normal. No uroliths or sediment were visualized and anechoic urine was present. No evidence of inflammatory or neoplastic changes was noted. Ureteral papillae were normal.

The **kidneys** revealed normal size and structure, corticomedullary definition and ratio for this age. The cortices presented largely uniform texture with normal echogenic relationship to liver and spleen. Medullary structure differed distinctly from the cortex and no evidence of pelvic dilation was present. The capsules were acceptably uniform without significant irregularities. The left kidney measured 5.07 cm. The right kidney measured 5.53 cm.

Adrenal Glands

Both **adrenal glands** were visualized and recognized as having normal shape, size, position and echogenicity for this breed. The phrenic vasculature, glandular echogenicity and detail were unremarkable. Capsule, cortex, and medullary definition were normal for this age patient. The right adrenal gland measured 0.72 cm at the cranial pole and 0.43 cm at the caudal pole. The left adrenal gland measured 0.4 cm at the cranial pole and 0.31 cm at the caudal pole.

Spleen

The **spleen** presented a smooth homogeneous parenchyma hyperechoic to liver and renal cortical parenchyma. The capsule was smooth without noticeable expansion or deviation from within the spleen or adjacent pathology. The splenic vasculature demonstrated normal volume without signs of congestion or thrombosis. No sonographic evidence of acute or chronic inflammatory, neoplastic, or infarctual changes was noted.

Liver

The **liver** images submitted revealed subjectively normal liver size, contour, and structure. Parenchymal echogenicity was naturally coarse and hypoechoic to the spleen. The portal vein to vena cava ratio was 1:1. The gallbladder presented acceptably thin walls with primarily anechoic content. The cystic and common bile ducts were normal. No pathological hepatic lymphadenopathy was evident. No overt structural evidence of inflammatory, infiltrative or regenerative pathology was evident.



PATIENT

Midnight Center for Animal Health

SPECIES

Canine

BREED

Mix

SEX

Neutered male

AGE

3 months

WEIGHT

15.5 lbs

INTERPRETED BY

Eric Lindquist, DMV, DABVP, Cert. IVUSS, CEO of SonoPath.com

IMAGING PERFORMED BY

Shari Reffi, CVT

HOSPITAL NAME

William Penn VH

REFERRING VET

Dr. Abouemara

INVOICE

70087

DATE

1/13/26

Gastrointestinal

There was some residual chyme and gas was noted in the **stomach**, yet not pathological. This is consistent with post prandial presentation. Transit of chyme into the small intestine was normal. Curvilinear patterns were maintained throughout the GI tract. No evidence of pathology. Small and large intestine demonstrated normal luminal chyme and stool consistency respectively. The colon was fluid filled.

Pancreas

The base and limbs of the **pancreas** were observed to be largely isoechoic to surrounding omental fat. Pancreatic duct and capsular contour were acceptably normal and parenchyma respected normal curvilinear patterns. No overt evidence of active inflammatory or neoplastic disease was noted.

ULTRASONOGRAPHIC FINDINGS

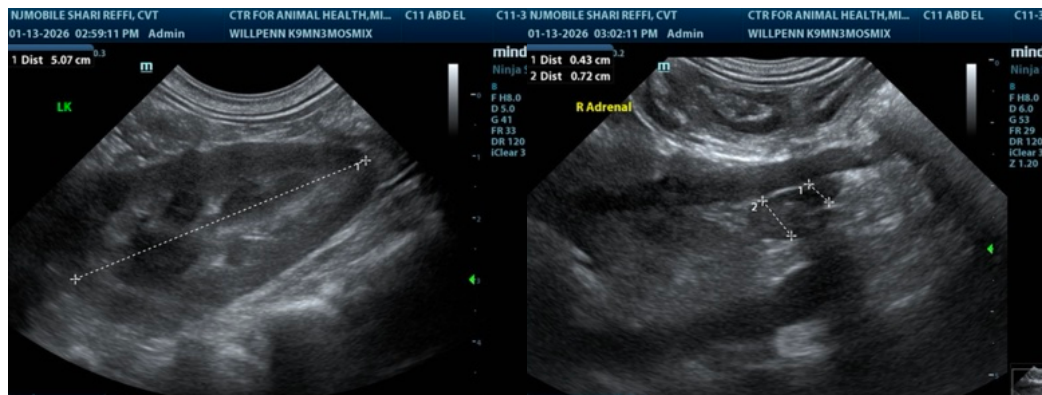
Enterocolitis pattern.

Likely reactive hepatopathy.

INTERPRETATION OF THE FINDINGS & FURTHER RECOMMENDATIONS

There was no evidence of portosystemic shunting.

Differentials for diarrhea include occult parasitism. Dietary indiscretion, dietary intolerance, antibiotic responsive colitis, intestinal dysbiosis and occult Addison's should all be considered as causes of diarrhea in this patient. A hydrolyzed diet trial may be in this patient's best interest +/- probiotics. 24-hour NPO and reintroduction of bland diet indicated. I recommend a baseline cortisol or ACTH stimulation test, a fresh fecal smear and fecal floatation analysis if not already performed





PATIENT

Midnight Center for Animal Health

SPECIES

Canine

BREED

Mix

SEX

Neutered male

AGE

3 months

WEIGHT

15.5 lbs

INTERPRETED BY

Eric Lindquist, DMV,
 DABVP, Cert. IVUSS,
 CEO of SonoPath.com

IMAGING PERFORMED BY

Shari Reffi, CVT

HOSPITAL NAME

William Penn VH

REFERRING VET

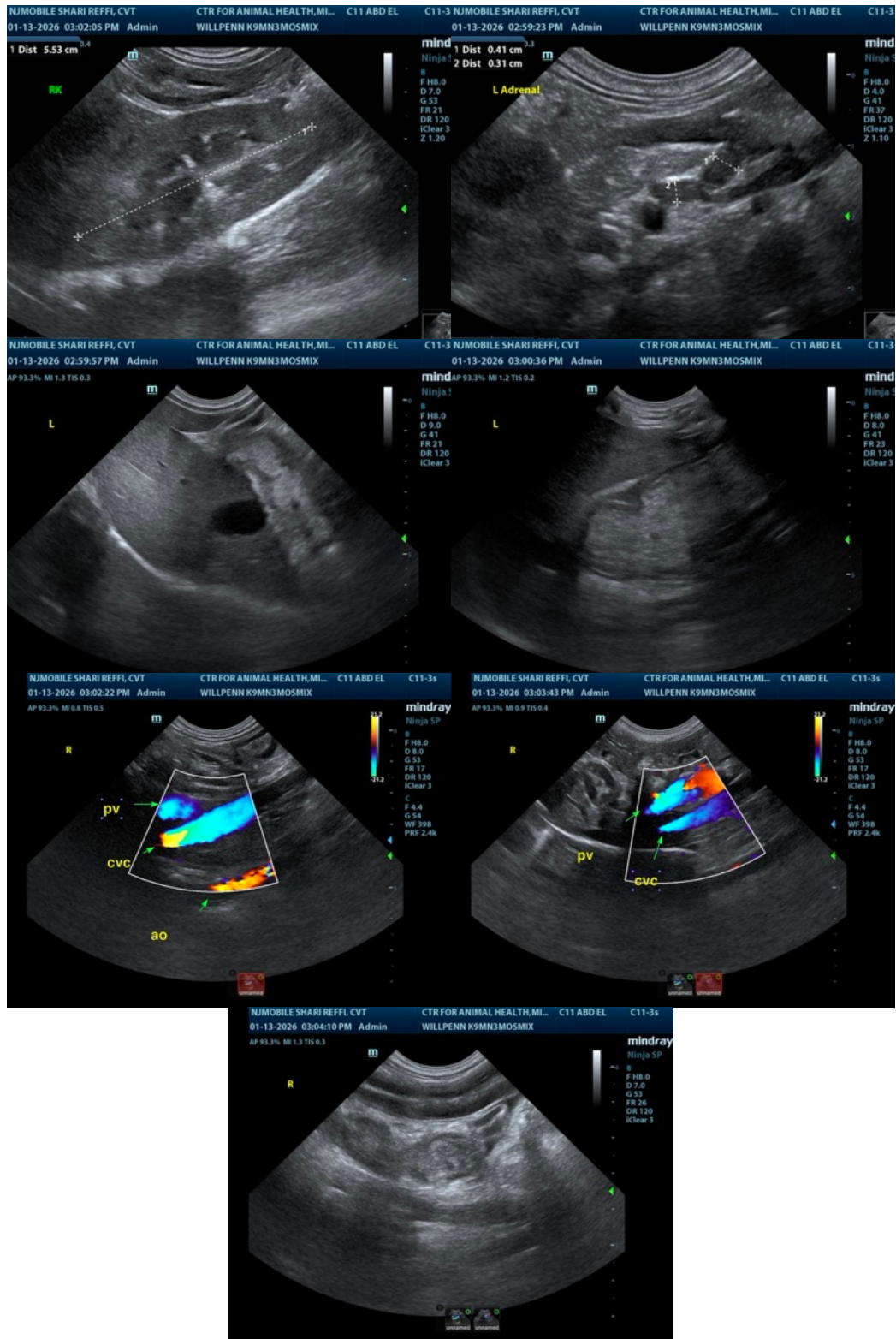
Dr. Abouemara

INVOICE

70087

DATE

1/13/26





PATIENT

Midnight Center for
Animal Health

SPECIES

Canine

BREED

Mix

SEX

Neutered male

AGE

3 months

WEIGHT

15.5 lbs

INTERPRETED BY

Eric Lindquist, DMV,
DABVP, Cert. IVUSS,
CEO of SonoPath.com

**IMAGING
PERFORMED BY**

Shari Reffi, CVT

HOSPITAL NAME

William Penn VH

REFERRING VET

Dr. Abouemara

INVOICE

70087

DATE

1/13/26

The information and recommendations provided are based on the images presented by the referring veterinarian/sonographer. No evaluation can be communicated regarding pathology that was not visible in the image/video clips provided.

Thank you for this referral. If the clinical or image interpretation does not parallel your findings or if I can be of any further assistance please contact me.

Eric Lindquist, DMV, DABVP, Cert. IVUSS, CEO of SonoPath.com

Info@SonoPath.com