



PATIENT PRESENTING CLINICAL SIGNS

PATIENT Otis Ouellette
SPECIES Canine
BREED Boxer
SEX Neutered male
AGE 10 years
WEIGHT 27 kg

History: Urinating in house, large amounts for last 2 weeks. Roughly 4 times daily. Also seems to be thirstier. No hematuria or stranguria seen. No diet or environment changes. Eats more. No vomiting or diarrhea. Lump palpable SQ on left side of lower neck about 3-4 cm in diameter, round and soft and attached. Concerned about tumor on Thyroid. Only meds currently is Glucosamine.
Abnormal PE/Chem/CBC/UA Results: TT4 high 104, ALT high 193, RBCs high 9.14, HGB high 21.2.

ULTRASONOGRAPHIC EXAMINATION OF THE ABDOMEN

Urinary System

The **urinary bladder**, trigone, and pelvic urethra presented normal thicknesses and normal tone. The ureters were not visible which is normal. No uroliths or sediment were visualized and anechoic urine was present. No evidence of inflammatory or neoplastic changes was noted. Ureteral papillae were normal.

The **kidneys** revealed normal size and structure, corticomedullary definition and ratio for this age. The cortices presented largely uniform texture with normal echogenic relationship to liver and spleen. Medullary structure differed distinctly from the cortex and no evidence of pelvic dilation was present. The capsules were acceptably uniform without significant irregularities. The right kidney measured 6.06 cm. The left kidney measured 7.76 cm.

Adrenal Glands

Both **adrenal glands** were visualized and recognized as having normal shape, size, position and echogenicity for this breed. The phrenic vasculature, glandular echogenicity and detail were unremarkable. Capsule, cortex, and medullary definition were normal for this age patient. The left adrenal gland measured 1.67 x 0.45 cm at the caudal pole and 0.44 cm at the cranial pole. The right adrenal gland measured 3.08 x 0.97 cm at the cranial pole and 0.87 cm at the caudal pole.

Spleen

The **spleen** presented a smooth homogeneous parenchyma hyperechoic to liver and renal cortical parenchyma. The capsule was smooth without noticeable expansion or deviation from within the spleen or adjacent pathology. The splenic vasculature demonstrated normal volume without signs of congestion or thrombosis. No sonographic evidence of acute or chronic inflammatory, neoplastic, or infarctual changes was noted.

Liver

The **liver** images submitted revealed subjectively normal liver size, contour, and structure. Parenchymal echogenicity was naturally coarse and hypoechoic to the spleen. Vascular and biliary tracts were of normal volume with no evidence of congestion. The gallbladder presented acceptably thin walls with primarily anechoic content. The cystic and common bile ducts were normal. No pathological hepatic lymphadenopathy was evident. No overt structural evidence of inflammatory, infiltrative or regenerative pathology was evident.

INTERPRETED BY

Eric Lindquist, DMV
DABVP, Cert. IVUSS

IMAGING PERFORMED BY

Crystal Hill

HOSPITAL NAME

Beatties Burlington PH

REFERRING VET

Dr. Ruggieri

INVOICE

91897

DATE

9/21/21



PATIENT *Gastrointestinal*

Otis Ouellette Examination of the **gastrointestinal tract** revealed a stomach and intestine free of stasis, of normal wall thickness, acceptable curvilinear mural detail, and peristaltic activity. Small and large intestine demonstrated normal luminal chyme and stool consistency respectively. No obstructive or overt infiltrative disease was noted. No associated abnormal lymphatic activity was noted.

SPECIES

Canine

BREED

Boxer

Pancreas

The base and limbs of the **pancreas** were observed to be largely isoechoic to surrounding omental fat. Pancreatic duct and capsular contour were acceptably normal and parenchyma respected normal curvilinear patterns. No overt evidence of active inflammatory or neoplastic disease was noted.

SEX

Neutered male

Thyroid

The left cervical region revealed a cavitated expansive, irregular mass. The mass measured 4.0 cm. A cavitated right lobar thyroid mass was also noted and measured 2.0 cm. This is highly vascular. No normal thyroid tissue was noted. This appears to be deriving from the left thyroid lobe.

AGE

10 years

WEIGHT

27 kg

ULTRASONOGRAPHIC FINDINGS

Structurally unremarkable abdomen.

Non-specific inflammatory hepatopathy without significant structural changes.

Bilateral thyroid lobar masses. Strongly suggestive for carcinoma.

INTERPRETED BY

Eric Lindquist, DMV
DABVP, Cert. IVUSS

INTERPRETATION OF THE FINDINGS & FURTHER RECOMMENDATIONS

The thyroid masses are not likely resectable given the bilateral enlargement. The masses appear encapsulated, but do deviate regional vascular structures. CT with contrast is warranted for potential surgical planning. However, clean resection would likely be difficult.

IMAGING PERFORMED BY

Crystal Hill

HOSPITAL NAME

Beatties Burlington PH

REFERRING VET

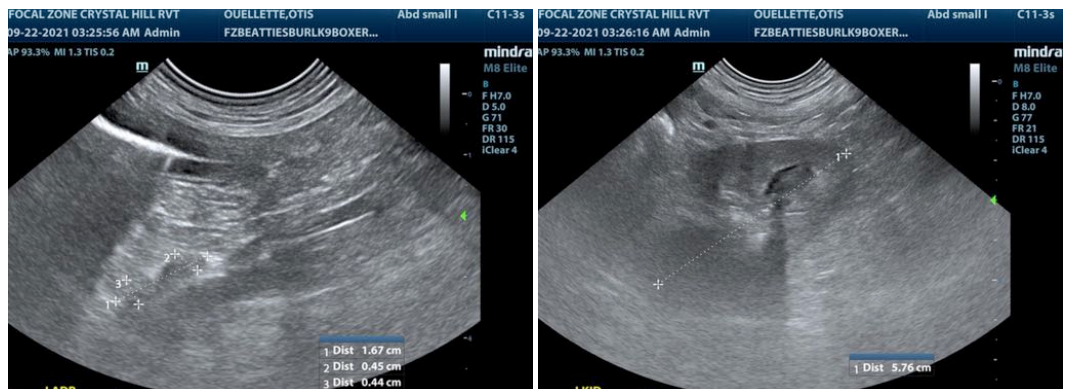
Dr. Ruggieri

INVOICE

91897

DATE

9/21/21





PATIENT

Otis Ouellette

SPECIES

Canine

BREED

Boxer

SEX

Neutered male

AGE

10 years

WEIGHT

27 kg

INTERPRETED BY

Eric Lindquist, DMV
DABVP, Cert. IVUS

**IMAGING
PERFORMED BY**

Crystal Hill

HOSPITAL NAME

Beatties Burlington PH

REFERRING VET

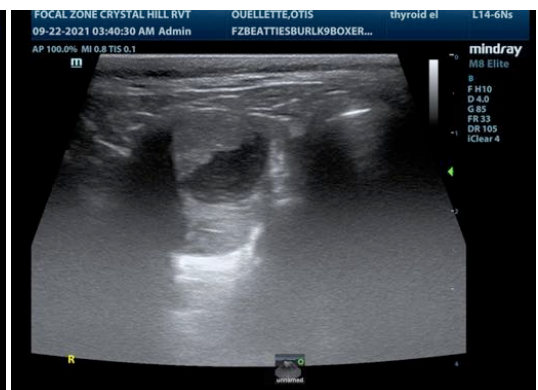
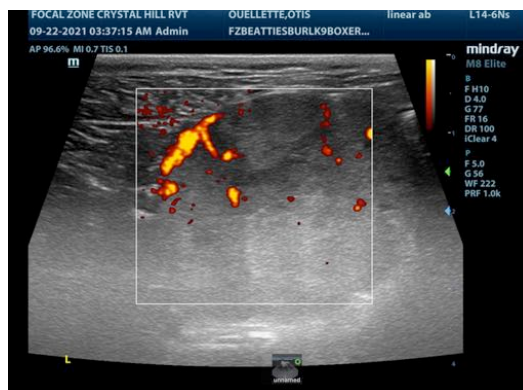
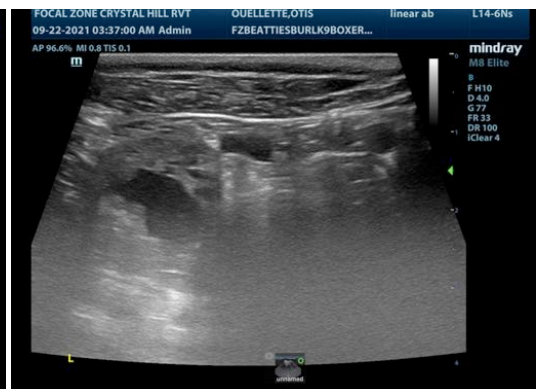
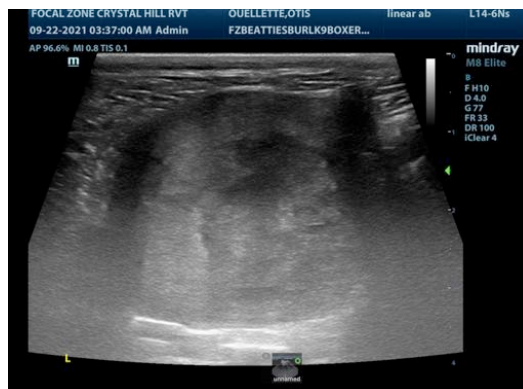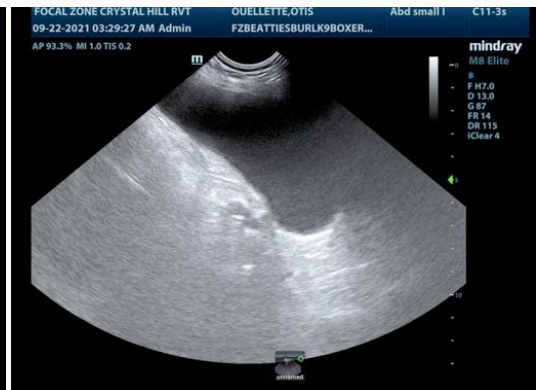
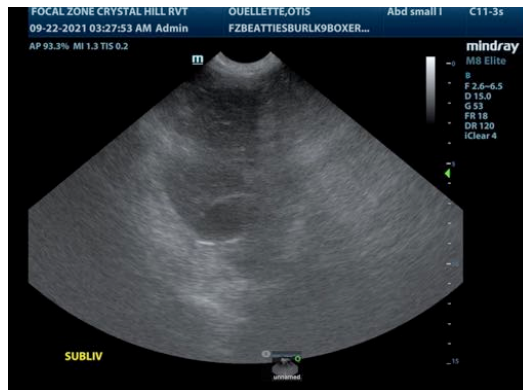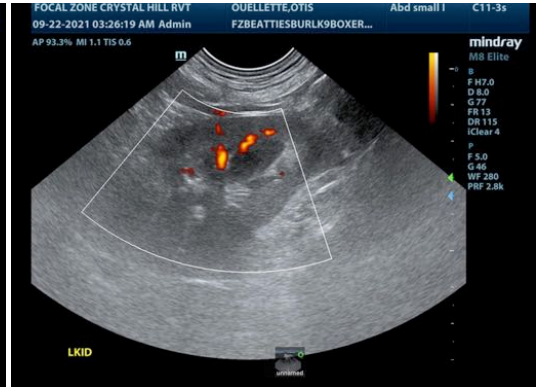
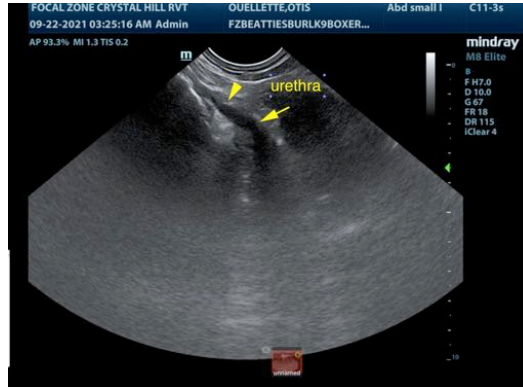
Dr. Ruggieri

INVOICE

91897

DATE

9/21/21





PATIENT

Otis Ouellette

The information and recommendations provided are based on the images presented by the referring veterinarian. No evaluation can be communicated regarding pathology that was not visible in the image/video clips provided.

SPECIES

Canine

Thank you for this referral. If the clinical or image interpretation does not parallel your findings or if I can be of any further assistance please contact me.

BREED

Boxer

Eric Lindquist, DMV, DABVP, Cert. IVUSS, CEO of SonoPath.com
Eric.Lindquist@SonoPath.com

SEX

Neutered male

AGE

10 years

WEIGHT

27 kg

INTERPRETED BY

Eric Lindquist, DMV
DABVP, Cert. IVUSS

**IMAGING
PERFORMED BY**

Crystal Hill

HOSPITAL NAME

Beatties Burlington PH

REFERRING VET

Dr. Ruggieri

INVOICE

91897

DATE

9/21/21