



PATIENT PRESENTING CLINICAL SIGNS

Kevin Walker

History: Patient is shedding more, drinking more and peeing more. Always seems hungry. Thyroid values are elevated. No current meds.
Abnormal PE/Chem/CBC/UA Results: Elevation in thyroid parameters except for low TSH. Please see attached bloodwork and rads.

SPECIES

Canine

ULTRASONOGRAPHIC EXAMINATION OF THE THYROID

BREED

Shepherd Mix

The cervical region was imaged. The salivary glands, esophagus, trachea and surrounding tissues all appeared normal. The left and right thyroid lobes were clearly visualized. There was no evidence of pathology noted. The parenchyma was uniform. There was no evidence of masses. The parathyroids were also visible and unremarkable in both lobes.

SEX

Neutered male

ULTRASONOGRAPHIC FINDINGS

Normal thyroid and parathyroid region. No evidence of masses.

AGE

10 years

INTERPRETATION OF THE FINDINGS & FURTHER RECOMMENDATIONS

WEIGHT

27.9 kg

I recommend assessment of the feeding history to assess if any neck meat has been utilized in the diet and can create an artificial, hyperthyroid type profile. Otherwise, ectopic thyroid tissue is a potential, yet the thyroid lobes themselves appear normal.

INTERPRETED BY

Eric Lindquist, DMV
DABVP, Cert. IVUSS

For an additional charge an internal medicine consult can be utilized through [Sonopath.com](http://sonopath.com). You can select the internal medicine drop down at <http://spa.sonopath.com/>.

One of the world's top internists & SonoPath associate Dr. Remo Lobetti BVSc, MMedVet, PhD, DECVIM can evaluate your case through SonoPath. <https://sonopath.com/resources/sonopath-services/internal-medicine-teleconsultation-services>

IMAGING PERFORMED BY

Crystal Hill

HOSPITAL NAME

Oxford County VC

REFERRING VET

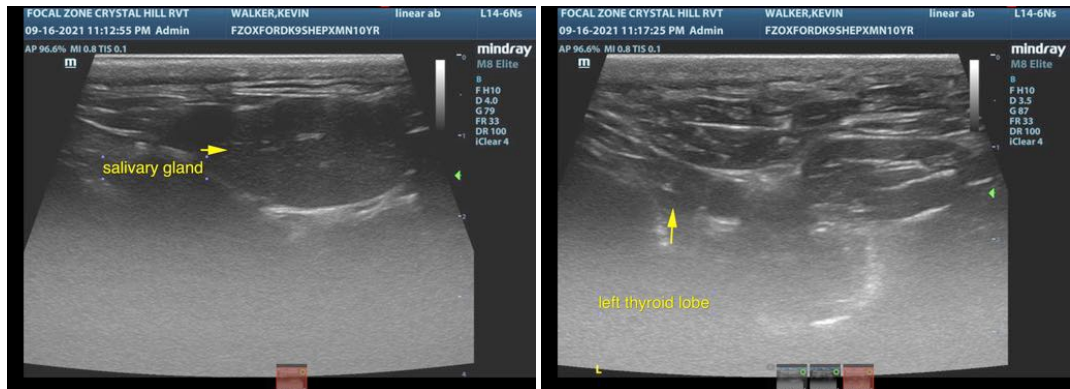Dr. Haflon

INVOICE

91890

DATE

9/16/21





PATIENT

Kevin Walker

SPECIES

Canine

BREED

Shepherd Mix

SEX

Neutered male

AGE

10 years

WEIGHT

27.9 kg

INTERPRETED BY

Eric Lindquist, DMV
DABVP, Cert. IVUSS

**IMAGING
PERFORMED BY**

Crystal Hill

HOSPITAL NAME

Oxford County VC

REFERRING VET

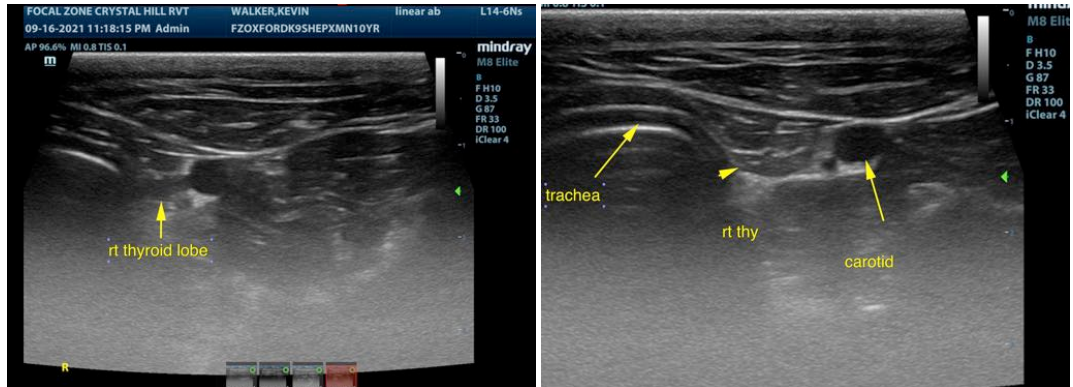
Dr. Haflon

INVOICE

91890

DATE

9/16/21



The information and recommendations provided are based on the images presented by the referring veterinarian. No evaluation can be communicated regarding pathology that was not visible in the image/video clips provided.

Thank you for this referral. If the clinical or image interpretation does not parallel your findings or if I can be of any further assistance please contact me.

Eric Lindquist, DMV, DABVP, Cert. IVUSS, CEO of SonoPath.com
Eric.Lindquist@SonoPath.com