
PATIENT PRESENTING CLINICAL SIGNS

Fozzy Miller History: P currently on phenobarb 30mg BID. Presented today having 3 seizures early this morning. The one lasted about 3 minutes. Also had one thursday mild cardiac enlargement with murmur
 Abnormal PE/Chem/CBC/UA Results: BW pending

SPECIES

Canine

ULTRASONOGRAPHIC EXAMINATION OF THE HEART
BREED

Lhaasa Apso

The echocardiogram in this patient demonstrated normal **left atrial** size based on 3 different LA measurement methods. Chamber volumes and echogenicity were normal. The cranial and caudal **mitral** valve leaflets presented vegetative thickening consistent with endocardiosis. Doppler indicated measurable insufficiency. The **left ventricle** presented thicknesses with linear contour and was not dilated nor restricted. The **myocardium** presented normal echogenicity without subjective evidence of significant fibrotic or ischemic disease. **Contractility** of the ventricular walls was adequate and in normal range for this patient evidenced by the fractional shortening measurement and subjective evaluation of the different regions of the myocardium. The **left ventricular outflow** tract demonstrated normal laminar flow and subjective structural integrity. The **right atrium** and auricle revealed normal size, structure and content. No evidence of masses was noted or chamber overload. Minor **tricuspid** insufficiency was noted at 2.3 m/sec. The **right ventricle** was of normal size (1/3 diameter of LV), chordae structure, myocardial echogenicity and thickness. **Pulmonic** tract assessment revealed normal valve structure, laminar flow, and diameter (approx. 1:1 pa/ao ratio). No visible **pericardial** or free pleura fluid was noted. No echographically detectable evidence of infiltrative disease was visible. The cranial **mediastinum and pericardial regions** were free of masses in the visible window.

SEX

Neutered male

AGE

12 years

WEIGHT

8.8 kg

INTERPRETED BY

 Eric Lindquist, DMV
 DABVP, Cert. IVUSS

IMAGING PERFORMED BY

Kelly Reshny, RVT

HOSPITAL NAME

 Beattie Pet Hospital
 Stoney Creek

REFERRING VET

Dr. Wittenrich

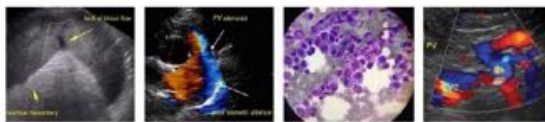
CANINE CARDIAC PARAMETERS	MR VMAX (m/s)	TR VMAX (m/s)	LA/AO (Boon method)	LA/AO (Heart Base; Swe)	FS (%)	EF (%)	EPSS (cm)
NORMAL PARAMETER	4.5-5.5	<2.7	1.3	<1.6	28-40	40-100	<0.6
PATIENT	5.74	2.3	1.07	1.14	41	74	0.1
CANINE CARDIAC PARAMETERS	HR (BPM)	AV VMAX (m/s)	PV MAX (m/s)	BODY WEIGHT (kg)	LA 2D short axis Base view (cm)	LVIDd Avg; 2D and m- mode short axis (cm)	LVIDs Avg; 2D and m- mode short axis (cm)
NORMAL PARAMETER	50-100	0.7-1.7	0.7-1.6	BELOW	BELOW	BELOW	BELOW
PATIENT	156		1.13	8.8	2.36	2.87	

INVOICE

32155

DATE

8/4/22



PATIENT **ULTRASONOGRAPHIC EXAMINATION OF THE ABDOMEN**

Fozzy Miller

Urinary System

SPECIES

Canine

The **urinary bladder**, trigone, and pelvic urethra presented normal thicknesses and normal tone. The ureters were not visible which is normal. No uroliths or sediment were visualized and anechoic urine was present. No evidence of inflammatory or neoplastic changes was noted. Ureteral papillae were normal.

BREED

Lhaasa Apso

The **kidneys** revealed largely normal size and structure, corticomedullary definition and ratio (cortex 1/3 of medulla) were essentially maintained with some age-related loss of curvilinear patterns regarding the capsule and C/M junction. The cortices presented largely uniform texture with some increased echogenicity expected for his age patient. Medullary structure differed distinctly from that of the cortex and no evidence of pelvic dilation was present. The right kidney measured 5.13 cm. The left kidney measured 4.87 cm.

SEX

Neutered male

AGE

12 years

Adrenal Glands

WEIGHT

8.8 kg

Both **adrenal glands** were visualized and recognized as having normal shape, size, position and echogenicity for this breed. The phrenic vasculature, glandular echogenicity and detail were unremarkable. Capsule, cortex, and medullary definition were normal for this age patient. The right adrenal gland measured 1.78 x 0.58 cm at the caudal pole and 1.89 cm at the cranial pole. The left adrenal gland measured 1.76 x 0.43 cm at the caudal pole and 0.45 cm at the cranial pole.

INTERPRETED BY

Eric Lindquist, DMV
DABVP, Cert. IVUSS

Spleen

IMAGING PERFORMED BY

Kelly Reshny, RVT

The **spleen** presented a smooth homogeneous parenchyma hyperechoic to liver and renal cortical parenchyma. The capsule was smooth without noticeable expansion or deviation from within the spleen or adjacent pathology. The splenic vasculature demonstrated normal volume without signs of congestion or thrombosis. No sonographic evidence of acute or chronic inflammatory, neoplastic, or infarctual changes was noted.

HOSPITAL NAME

Beattie Pet Hospital
Stoney Creek

Liver

REFERRING VET

Dr. Wittenrich

The **liver** was uniformly swollen with minor, excessive gallbladder debris and over distension with dependent and suspended bile without evidence of overt mucocele formation. However, excessive sludge was present. The liver presented coarse architecture with mildly increased portal markings and subtle, mixed echogenic changes. This is consistent with vacuolar hepatopathy and some level of remodeling and history of inflammatory component. Occasional parenchymal cyst was noted in the caudate process of the liver with an isoechoic nodule that measured 0.3 cm. There was no overt suspicion of neoplasia.

INVOICE

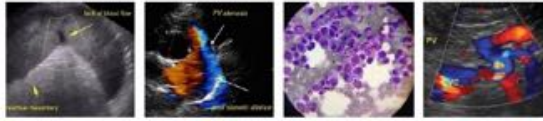
32155

Gastrointestinal

DATE

8/4/22

Examination of the **gastrointestinal tract** revealed a stomach and intestine free of stasis, of normal wall thickness, acceptable curvilinear mural detail, and peristaltic activity. Small and large intestine



PATIENT

Fozzy Miller

demonstrated normal luminal chyme and stool consistency respectively. No obstructive or overt infiltrative disease was noted. No associated abnormal lymphatic activity was noted.

Pancreas

SPECIES

Canine

The base and limbs of the **pancreas** were observed to be largely isoechoic to surrounding omental fat. Pancreatic duct and capsular contour were acceptably normal and parenchyma respected normal curvilinear patterns. No overt evidence of active inflammatory or neoplastic disease was noted.

BREED

Lhaasa Apso

ULTRASONOGRAPHIC FINDINGS

Stage B1 valvular disease, not a clinical issue.

SEX

Neutered male

Age related hepatic changes with a cystic nodule, likely benign.

Age related renal changes.

AGE

12 years

INTERPRETATION OF THE FINDINGS & FURTHER RECOMMENDATIONS

There was no evidence of significant disease regarding the abdominal cardiac presentation. Given the patient's history I recommend skull CT with contrast. The liver is consistent with benign hepatopathy. This may be related to phenobarbital presentation.

WEIGHT

8.8 kg

INTERPRETED BY

Eric Lindquist, DMV
DABVP, Cert. IVUSS

IMAGING PERFORMED BY

Kelly Reshny, RVT

HOSPITAL NAME

Beattie Pet Hospital
Stoney Creek

REFERRING VET

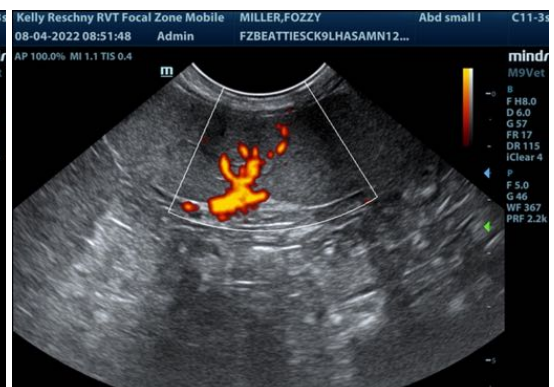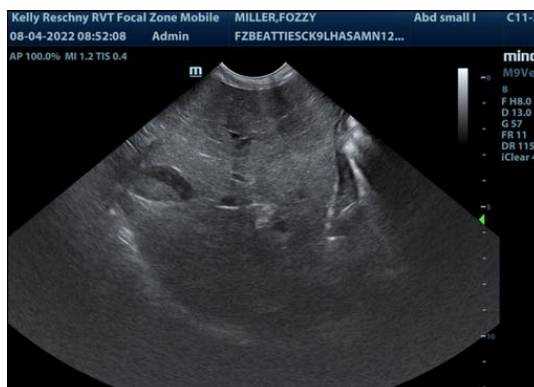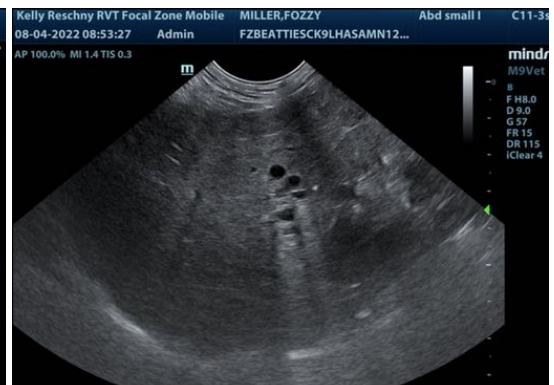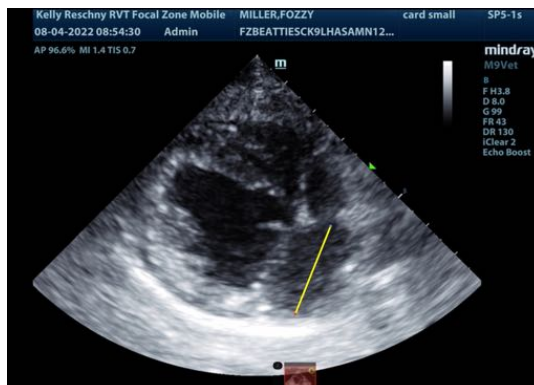
Dr. Wittenrich

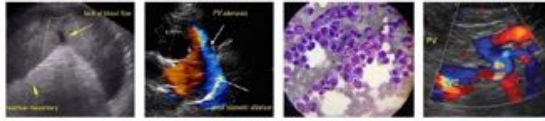
INVOICE

32155

DATE

8/4/22





PATIENT

Fozzy Miller

SPECIES

Canine

BREED

Lhaasa Apso

SEX

Neutered male

AGE

12 years

WEIGHT

8.8 kg

INTERPRETED BY

Eric Lindquist, DMV
DABVP, Cert. IVUSS

**IMAGING
PERFORMED BY**

Kelly Reshny, RVT

HOSPITAL NAME

Beattie Pet Hospital
Stoney Creek

REFERRING VET

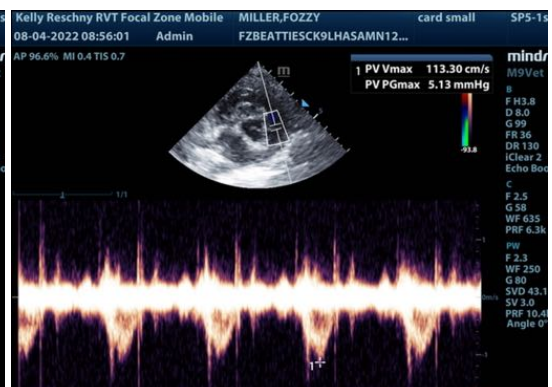
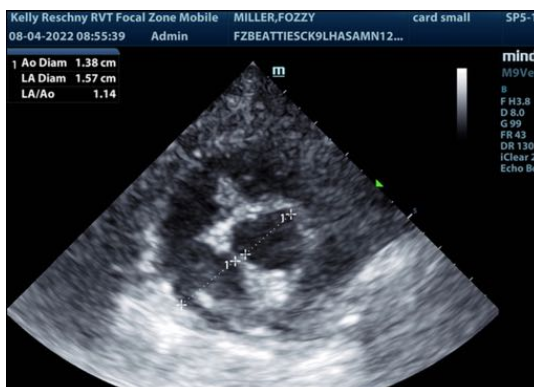
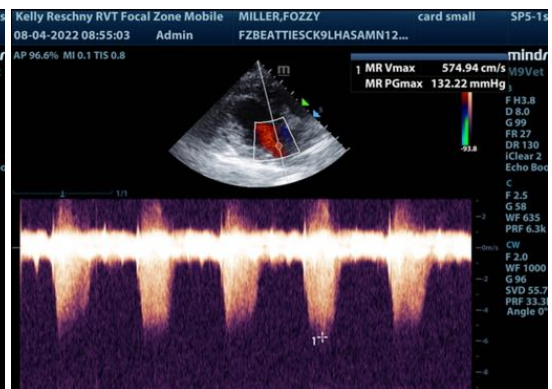
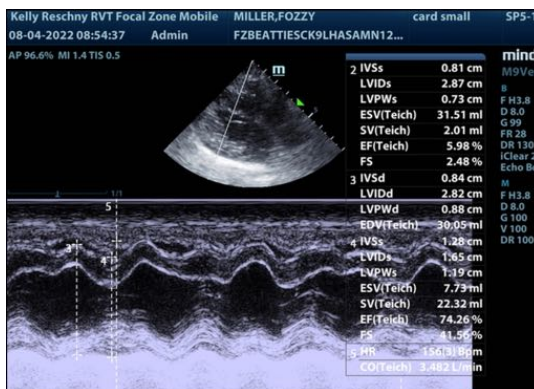
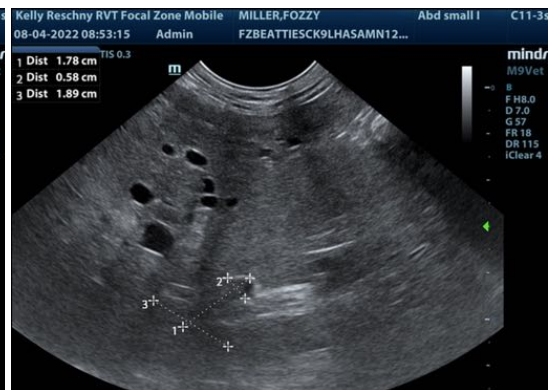
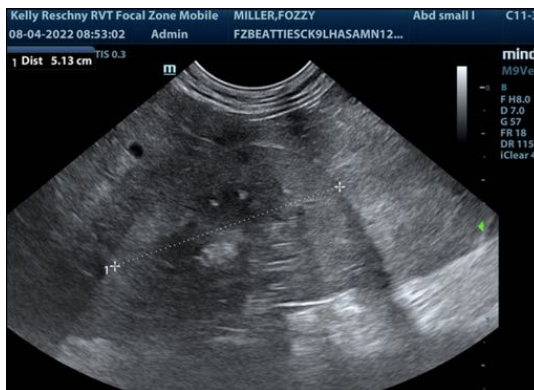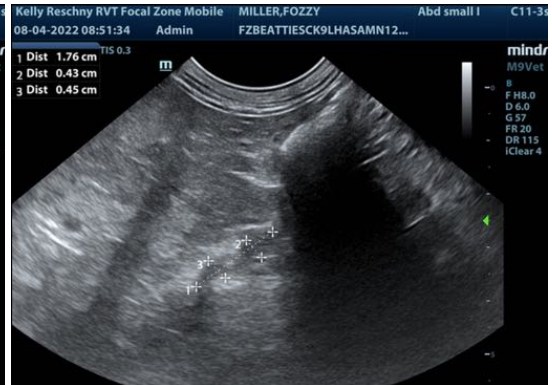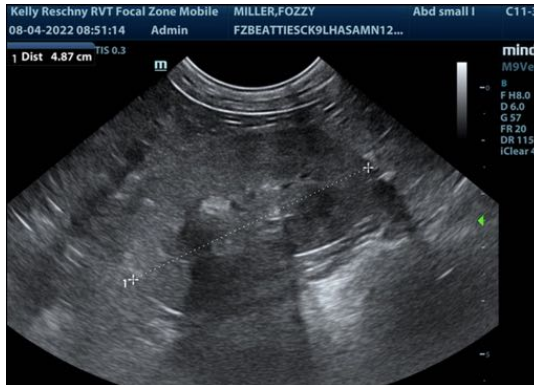Dr. Wittenrich

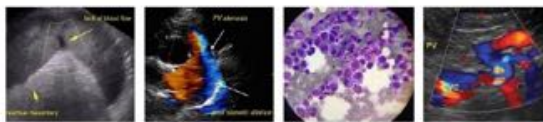
INVOICE

32155

DATE

8/4/22





PATIENT

Fozzy Miller

SPECIES

Canine

BREED

Lhaasa Apso

SEX

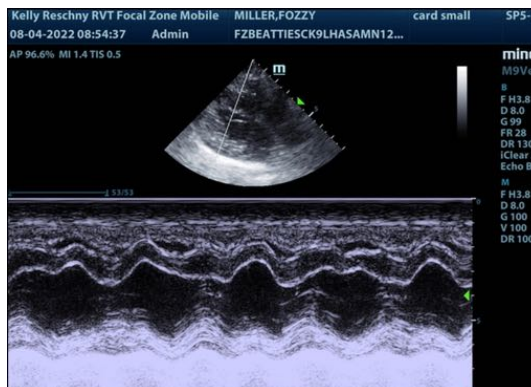
Neutered male

AGE

12 years

WEIGHT

8.8 kg



The information and recommendations provided are based on the images presented by the referring veterinarian/sonographer. No evaluation can be communicated regarding pathology that was not visible in the image/video clips provided.

Thank you for this referral. If the clinical or image interpretation does not parallel your findings or if I can be of any further assistance please contact me.

Eric Lindquist, DMV, DABVP, Cert. IVUSS, CEO of SonoPath.com
Eric.Lindquist@SonoPath.com

INTERPRETED BY

Eric Lindquist, DMV
DABVP, Cert. IVUSS

IMAGING PERFORMED BY

Kelly Reshny, RVT

HOSPITAL NAME

Beattie Pet Hospital
Stoney Creek

REFERRING VET

Dr. Wittenrich

INVOICE

32155

DATE

8/4/22