



PATIENT PRESENTING CLINICAL SIGNS

Kona Ellis

History: presented on July 15 for coughing, diagnosed with kennel cough, during exam found abd mass. Cranial abd, approx size and firmness of baseball, has since vomited up something approx that size
meds: clavaseptin

SPECIES

Canine

BREED

Blue Picardy Spaniel

SEX

Spayed female

AGE

9 years

WEIGHT

22.4 kg

INTERPRETED BY

Eric Lindquist, DMV
DABVP, Cert. IVUSS

IMAGING PERFORMED BY

Kelly Reshny, RVT

HOSPITAL NAME

Buck AH

REFERRING VET

Dr. Morin

INVOICE

31898

DATE

7/25/22

ULTRASONOGRAPHIC EXAMINATION OF THE ABDOMEN

Urinary System

The **urinary bladder**, trigone, and pelvic urethra presented normal thicknesses and normal tone. The ureters were not visible which is normal. No uroliths or sediment were visualized and anechoic urine was present. No evidence of inflammatory or neoplastic changes was noted. Ureteral papillae were normal.

The **kidneys** revealed normal size and structure, corticomedullary definition and ratio for this age. The cortices presented largely uniform texture with normal echogenic relationship to liver and spleen. Medullary structure differed distinctly from the cortex and no evidence of pelvic dilation was present. The capsules were acceptably uniform without significant irregularities. The left kidney measured 4.92 cm. The right kidney measured 6.71 cm.

Adrenal Glands

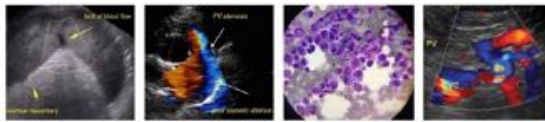
Both **adrenal glands** were visualized and recognized as having normal shape, size, position and echogenicity for this breed. The phrenic vasculature, glandular echogenicity and detail were unremarkable. Capsule, cortex, and medullary definition were normal for this age patient. The right adrenal gland measured 2.11 x 1.87 cm at the cranial pole and 0.71 cm at the caudal pole. The left adrenal gland measured 2.35 x 0.71 cm at the caudal pole and 0.86 cm at the cranial pole.

Spleen

The **spleen** was folded cranially, yet there was no evidence of masses.

Liver

The **liver** images submitted revealed subjectively normal liver size, contour, and structure. Parenchymal echogenicity was naturally coarse and hypoechoic to the spleen. Vascular and biliary tracts were of normal volume with no evidence of congestion. The gallbladder presented acceptably thin walls with primarily anechoic content. The cystic and common bile ducts were normal. No pathological hepatic lymphadenopathy was evident. No overt structural evidence of inflammatory, infiltrative or regenerative pathology was evident.



PATIENT

Kona Ellis

SPECIES

Canine

BREED

Blue Picardy Spaniel

SEX

Spayed female

AGE

9 years

WEIGHT

22.4 kg

Gastrointestinal

Examination of the **gastrointestinal tract** revealed a stomach and intestine free of stasis, of normal wall thickness, acceptable curvilinear mural detail, and peristaltic activity. Small and large intestine demonstrated normal luminal chyme and stool consistency respectively. No obstructive or overt infiltrative disease was noted. No associated abnormal lymphatic activity was noted.

Pancreas

The base and limbs of the **pancreas** were observed to be largely isoechoic to surrounding omental fat. Pancreatic duct and capsular contour were acceptably normal and parenchyma respected normal curvilinear patterns. No overt evidence of active inflammatory or neoplastic disease was noted.

ULTRASONOGRAPHIC FINDINGS

Normal abdomen with folded spleen.

INTERPRETATION OF THE FINDINGS & FURTHER RECOMMENDATIONS

There is no evidence of masses. The palpation may be the splenic fold.

INTERPRETED BY

Eric Lindquist, DMV
DABVP, Cert. IVUSS

IMAGING PERFORMED BY

Kelly Reshny, RVT

HOSPITAL NAME

Buck AH

REFERRING VET

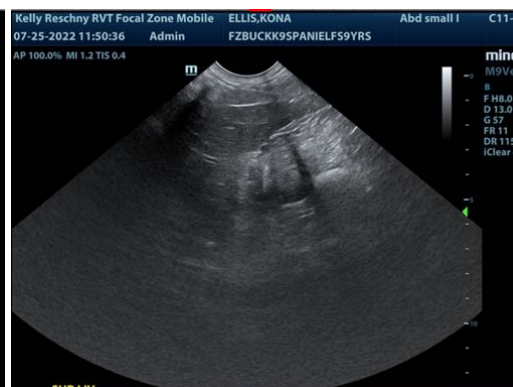
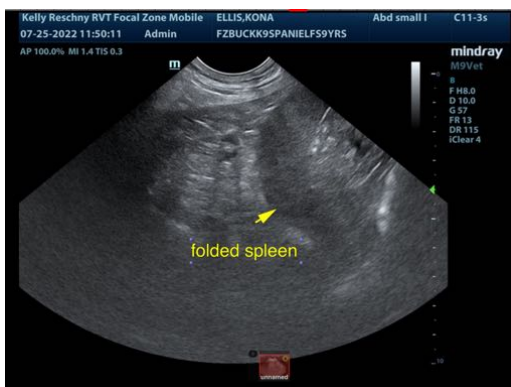
Dr. Morin

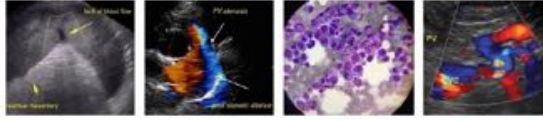
INVOICE

31898

DATE

7/25/22





PATIENT

Kona Ellis

SPECIES

Canine

BREED

Blue Picardy Spaniel

SEX

Spayed female

AGE

9 years

WEIGHT

22.4 kg

INTERPRETED BY

Eric Lindquist, DMV
DABVP, Cert. IVUSS

**IMAGING
PERFORMED BY**

Kelly Reshny, RVT

HOSPITAL NAME

Buck AH

REFERRING VET

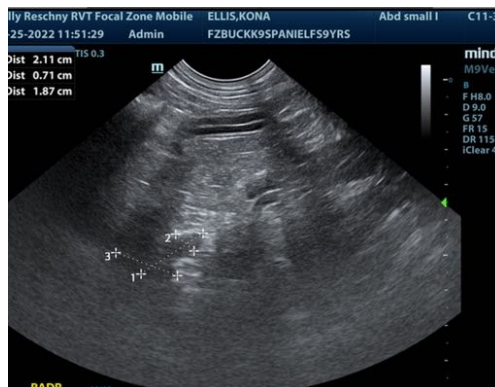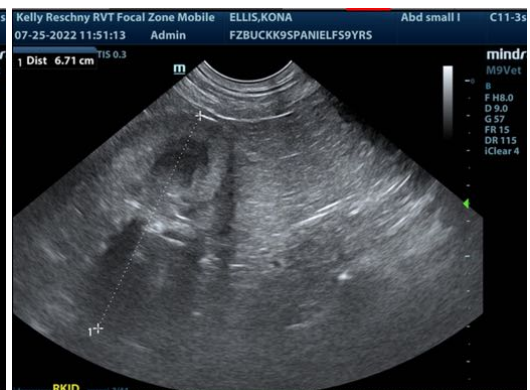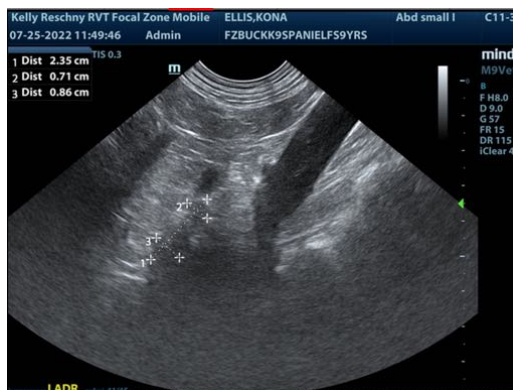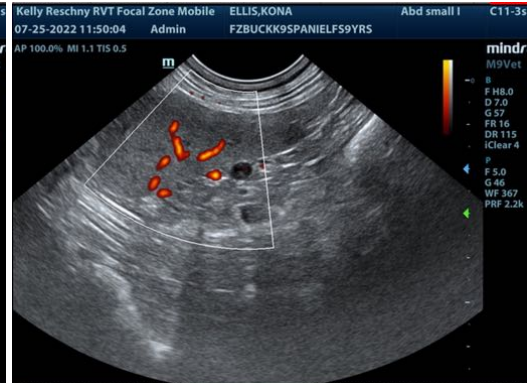
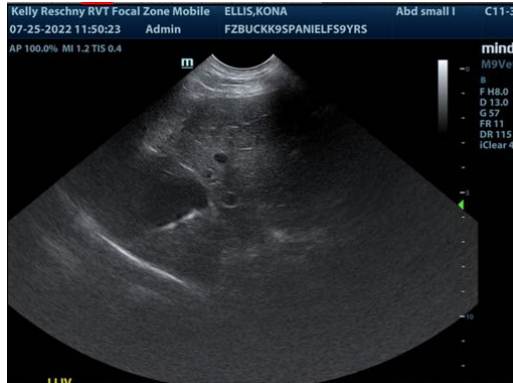Dr. Morin

INVOICE

31898

DATE

7/25/22



The information and recommendations provided are based on the images presented by the referring veterinarian/sonographer. No evaluation can be communicated regarding pathology that was not visible in the image/video clips provided.

Thank you for this referral. If the clinical or image interpretation does not parallel your findings or if I can be of any further assistance please contact me.

Eric Lindquist, DMV, DABVP, Cert. IVUSS, CEO of SonoPath.com
Eric.Lindquist@SonoPath.com