

PATIENT PRESENTING CLINICAL SIGNS

Tar Kovacevich

Previous scan on August 2021. Has been drastically losing weight over the last year and it has continued. Lethargic.

SPECIES

Abnormal PE/Chem/CBC/UA Results: Reticus decreased, Hemoglobin decreased, SDMA elevated at 17, Chloride decreased, Albumin increased, ALT elevated at 175 and ALP elevated at 83. FPLI pending.

Feline

BREED

Domestic Shorthair

SEX

Neutered male

AGE

14 years

WEIGHT

13.5 lbs

ULTRASONOGRAPHIC EXAMINATION OF THE HEART

The echocardiogram in this patient demonstrated normal **left atrial** size based on 3 separate LA measurements. The cranial and caudal **mitral** valve leaflets presented normal linear structure and kinetics. The **left ventricle** presented normal thicknesses with linear contour and was not dilated nor restricted. The **myocardium** presented normal echogenicity without subjective evidence of significant fibrotic or ischemic disease. **Contractility** of the ventricular walls was adequate and in normal range for this patient evidenced by the fractional shortening measurement and subjective evaluation of the different regions and angles of the myocardium. The **left ventricular outflow** tract demonstrated normal laminar flow and subjective structural integrity. The **right atrium** and auricle revealed normal size, structure and content. No evidence of masses was noted or chamber overload. **Tricuspid** valvular assessment demonstrated adequate linear morphology and kinetics. The **right ventricle** was of normal size (1/3 diameter of LV), chordae structure, myocardial echogenicity and thickness. **Pulmonic** tract assessment revealed normal valve structure, laminar flow, and diameter (approx. 1:1 pa/ao ratio). No visible **pericardial** or free pleura fluid was noted or extra cardiac pathology in the visible planes. The cranial **mediastinum and pericardial regions** were free of masses in the visible window.

INTERPRETED BY

Eric Lindquist, DMV
DABVP, Cert. IVUSS

IMAGING PERFORMED BY

Crystal Hill, RVT

HOSPITAL NAME

Halton Peel AH

REFERRING VET

Dr. Walters

INVOICE

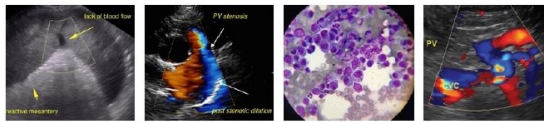
31713

DATE

7/15/22

FELINE CARDIAC PARAMETERS	BODY WEIGHT (kg)	HR (BPM)	IVSd (cm)	LVIDd (cm)	LVWd (cm)	FS (%)	EF (%)
NORMAL PARAMETER	-----	150-240	0.3-0.6	1.0-2.1	0.25-0.6	35-67	80-100
PATIENT		NM	0.5	1.4	0.4	50	
FELINE CARDIAC PARAMETERS	LA/AO (Boon)	LA/AO HEART BASE (Sisson)	LA 2D 4-chamber long axis AS to FW (Sisson) (cm)	LVOT VEL. (m/s)	RVOT VEL. (m/s)	IVRT (m/)	
NORMAL PARAMETER	<1.5	0.88-1.79	0.7-1.7	<1.6	<1.3	40-60	
PATIENT	1.1	1.4	1.3	1.0	0.9	NM	

Adapted from June Boon, Veterinary Echocardiography, 1998
Sisson D et al. JVIM 1991; 5: 232, Jacobs et al. Am J Vet Res 1985; 46:1705



PATIENT **ULTRASONOGRAPHIC EXAMINATION OF THE ABDOMEN**

Tar Kovacevich

Urinary System

SPECIES

Feline

The **urinary bladder**, trigone, and pelvic urethra presented normal thicknesses and normal tone. The ureters were not visible which is normal. No uroliths or sediment were visualized and anechoic urine was present. No evidence of inflammatory or neoplastic changes was noted. Ureteral papillae were normal.

BREED

Domestic Shorthair

The **kidneys** revealed normal size and structure, corticomedullary definition and ratio for this age. The cortices presented largely uniform texture with normal echogenic relationship to liver and spleen. Medullary structure differed distinctly from the cortex and no evidence of pelvic dilation was present. The capsules were acceptably uniform without significant irregularities. The right kidney measured 4.2 cm.

SEX

Neutered male

AGE

14 years

Adrenal Glands

Both **adrenal glands** were visualized and recognized as having normal shape, size, position and echogenicity for this breed. The phrenic vasculature, glandular echogenicity and detail were unremarkable. Capsule, cortex, and medullary definition were normal for this age patient.

WEIGHT

13.5 lbs

Spleen

The **spleen** was mildly enlarged with uniform, but subtly micronodular parenchyma, and undulating capsular contour. This is consistent with reactive spleen owing to immune stimulus or early infiltrative disease such as mast cell disease or lymphoma. 25-gauge FNA would be ideal if weight loss is an issue to differentiate early round cell neoplasia versus splenitis or reactive spleen all of which can present in this manner.

INTERPRETED BY

Eric Lindquist, DMV
DABVP, Cert. IVUSS

IMAGING PERFORMED BY

Crystal Hill, RVT

Liver

The **liver** presented multi-focal, isoechoic nodular changes with irregular contour. Generalized hepatomegaly was noted. The gallbladder and common bile duct were unremarkable.

HOSPITAL NAME

Halton Peel AH

Gastrointestinal

Examination of the **gastrointestinal tract** revealed a stomach and intestine free of stasis, of normal wall thickness, acceptable curvilinear mural detail, and peristaltic activity. Small and large intestine demonstrated normal luminal chyme and stool consistency respectively. No obstructive or overt infiltrative disease was noted. No associated abnormal lymphatic activity was noted.

REFERRING VET

Dr. Walters

INVOICE

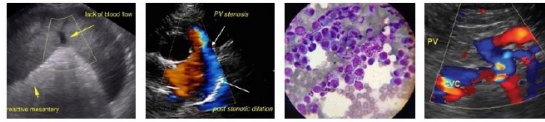
31713

Pancreas

DATE

7/15/22

A mixed, hypoechoic, ill-defined, 2.5 x 3.2 cm mass was noted in the region of the **pancreas**. The mass was undifferentiated.



PATIENT ULTRASONOGRAPHIC FINDINGS

Tar Kovacevich Essentially normal echocardiogram.

SPECIES Hepatic nodular changes with irregular contour.

Feline Scalloping spleen.

BREED Mass in area of pancreas may be a primary mass or related to the hepatic pathology.

Domestic Shorthair

INTERPRETATION OF THE FINDINGS & FURTHER RECOMMENDATIONS

FNA of the spleen, pancreatic lesion and liver are all indicated. Multi-centric neoplasia, carcinoma versus round cell neoplasia are a concern.

SEX

Neutered male

AGE

14 years

WEIGHT

13.5 lbs

INTERPRETED BY

Eric Lindquist, DMV
DABVP, Cert. IVUSS

IMAGING PERFORMED BY

Crystal Hill, RVT

HOSPITAL NAME

Halton Peel AH

REFERRING VET

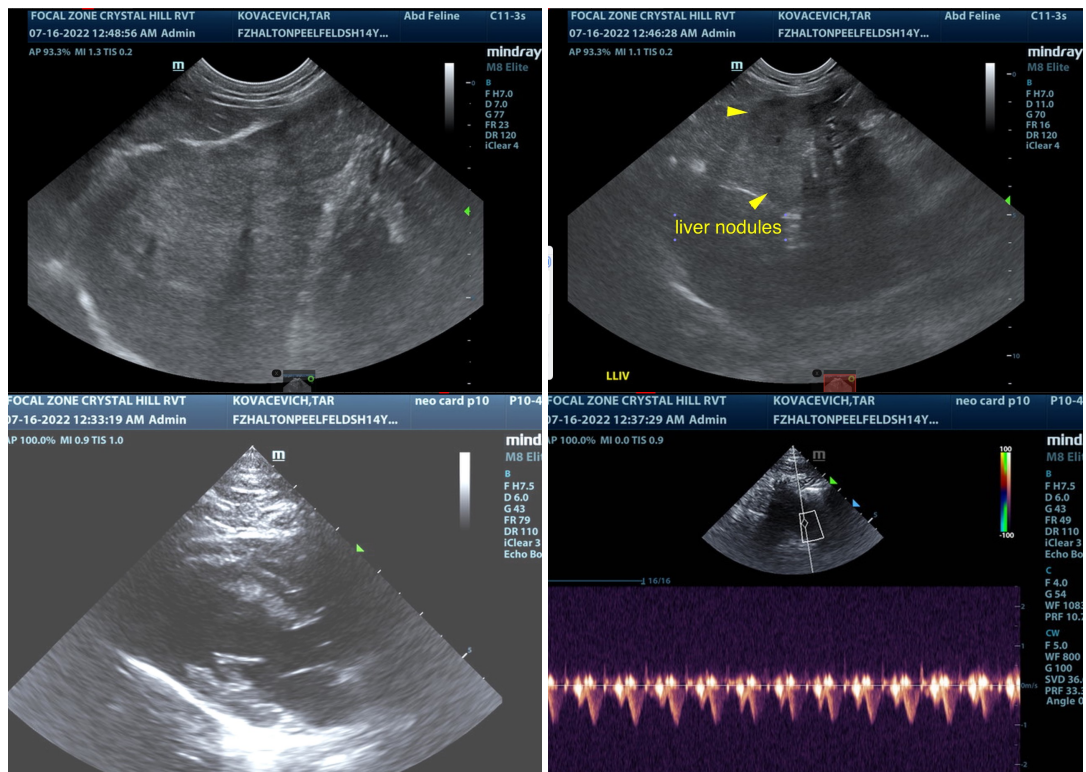
Dr. Walters

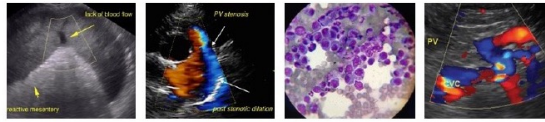
INVOICE

31713

DATE

7/15/22





PATIENT

Tar Kovacevich

SPECIES

Feline

BREED

Domestic Shorthair

SEX

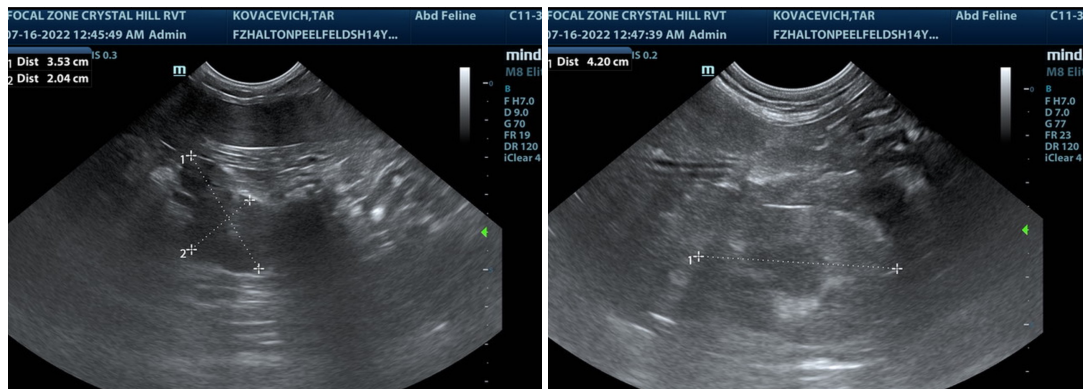
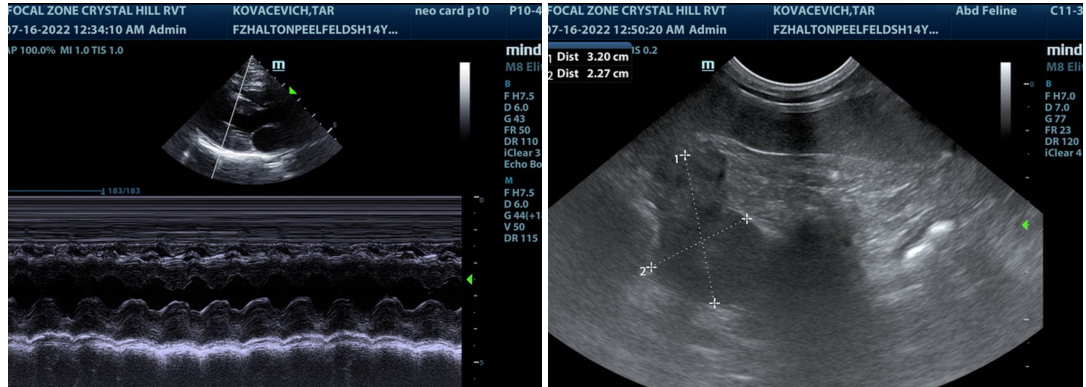
Neutered male

AGE

14 years

WEIGHT

13.5 lbs



INTERPRETED BY

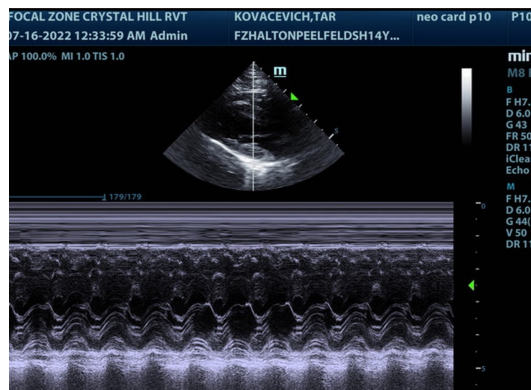
Eric Lindquist, DMV
DABVP, Cert. IVUSS

**IMAGING
PERFORMED BY**

Crystal Hill, RVT

HOSPITAL NAME

Halton Peel AH



REFERRING VET

Dr. Walters

The information and recommendations provided are based on the images presented by the referring veterinarian/sonographer. No evaluation can be communicated regarding pathology that was not visible in the image/video clips provided.

INVOICE

31713

DATE

7/15/22

Thank you for this referral. If the clinical or image interpretation does not parallel your findings or if I can be of any further assistance please contact me.

Eric Lindquist, DMV, DABVP, Cert. IVUSS, CEO of SonoPath.com
Eric.Lindquist@SonoPath.com