

**PATIENT**

Tully McLaughlin

**SPECIES**

Canine

**BREED**

German Shepherd

**SEX**

Neutered male

**AGE**

11 years

**WEIGHT**

99.2 lbs

**INTERPRETED BY**

Eric Lindquist, DMV,  
 DABVP, Cert. IVUSS,  
 CEO of SonoPath.com

**IMAGING PERFORMED BY**

Amanda Stewart

**HOSPITAL NAME**

The Maples AH

**REFERRING VET**

Dr. Kazienko

**INVOICE**

78329

**DATE**

6/3/26

**PRESENTING CLINICAL SIGNS**

History: Lump right axilla has grown, extends out laterally. Attachments to brachial plexus?  
 2nd lump just behind main lump?  
 Both appear to be lipomas on palpation.  
 Current Medications Hepato Support

**ULTRASONOGRAPHIC EXAMINATION**

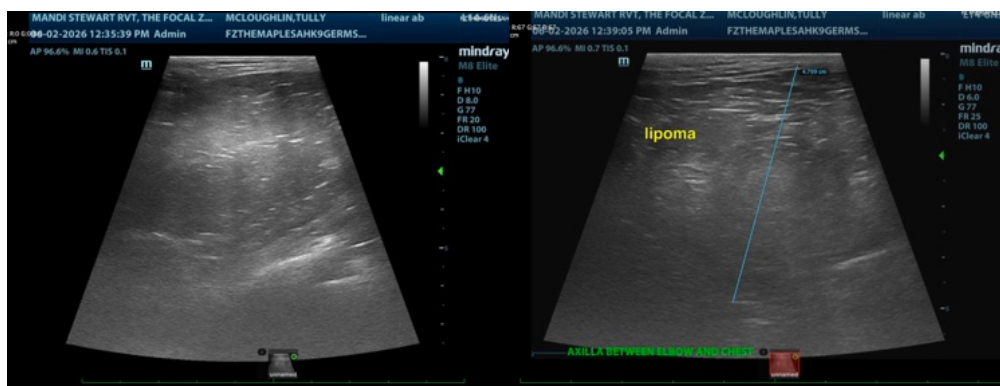
An axillary mass was note and measured 4.8 cm. The mass is uniformly echogenic. This is most consistent with lipoma. There is no evidence of vascular structures within the mass. The mass is expansive and space occupying. The mass appears to have fairly well-defined margins. The mass impinges upon regional issues, yet no crucial tissue appears to be present within the mass itself.

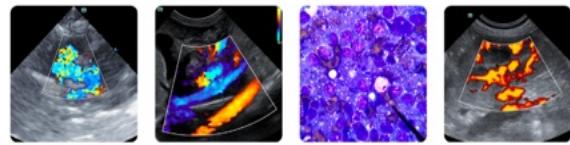
**ULTRASONOGRAPHIC FINDINGS**

- Axillary lipoma, appears resectable.

**INTERPRETATION OF THE FINDINGS & FURTHER RECOMMENDATIONS**

CT examination is recommended for surgical planning. However, debulking effort may be adequate. There was no reginal bony involvement or significant muscular involvement appears to be present. The mass does not appear malignant from a sonographic perspective. This is most consistent with lipoma.





**PATIENT**

Tully McLaughlin

**SPECIES**

Canine

**BREED**

German Shepherd

**SEX**

Neutered male

**AGE**

11 years

**WEIGHT**

99.2 lbs

**INTERPRETED BY**

Eric Lindquist, DMV,  
DABVP, Cert. IVUSS,  
CEO of SonoPath.com

**IMAGING PERFORMED BY**

Amanda Stewart

**HOSPITAL NAME**

The Maples AH

**REFERRING VET**

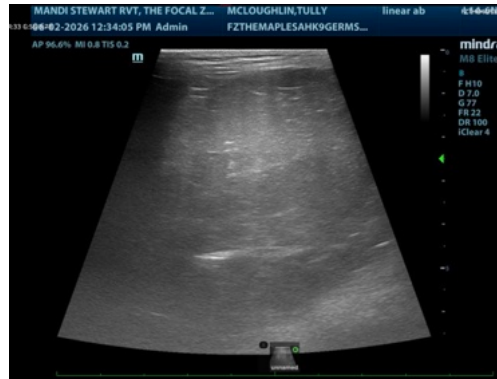Dr. Kazienko

**INVOICE**

78329

**DATE**

6/3/26



The information and recommendations provided are based on the images presented by the referring veterinarian/sonographer. No evaluation can be communicated regarding pathology that was not visible in the image/video clips provided.

Thank you for this referral. If the clinical or image interpretation does not parallel your findings or if I can be of any further assistance please contact me.

**Eric Lindquist, DMV, DABVP, Cert. IVUSS, CEO of SonoPath.com**

[info@SonoPath.com](mailto:info@SonoPath.com)