

**PATIENT PRESENTING CLINICAL SIGNS**

**Buster Iraj**  
History: presented to clinic for episodes of abnormal hunched posture & wheezing/throat-clearing. episodes were happening very frequently 2 days ago, but only 1-2 times yesterday & nothing so far today. on exam, there is a large abdominal mass slightly to left of midline that occupies approx 70% of abdominal cavity! not apparently uncomfortable/painful on palpation. normal appetite/energy levels, bowel movements are regular/normal in consistency. normal drinking/urination. enrofloxacin, meloxicam (from a different clinic)

**Lagomorph**  
Abnormal PE/Chem/CBC/UA Results: different clinic took abdominal radiographs on June 20/22 - showed large partially mineralized mass occupying majority of abdominal cavity

**BREED**

Holland Lop

**ULTRASONOGRAPHIC EXAMINATION OF THE ABDOMEN**

**SEX**

**Urinary System**

Intact female

The **urinary bladder**, trigone, and pelvic urethra presented normal thicknesses and normal tone. The ureters were not visible which is normal. No uroliths or sediment were visualized and anechoic urine was present. No evidence of inflammatory or neoplastic changes was noted. Ureteral papillae were normal.

**AGE**

5 years

The uterine horns were thickened in this patient and appeared to open up into a mineralized mass and measured 6.0 cm.

**WEIGHT**

1.95 kg

The **kidneys** revealed normal size and structure, corticomedullary definition and ratio for this age. The cortices presented largely uniform texture with normal echogenic relationship to liver and spleen. Medullary structure differed distinctly from the cortex and no evidence of pelvic dilation was present. The capsules were acceptably uniform without significant irregularities. The left kidney measured 2.74 cm. The right kidney measured 2.71 cm.

**INTERPRETED BY**

Eric Lindquist, DMV  
DABVP, Cert. IVUSS

The spleen revealed a focal, hypoechoic nodule. The spleen was mildly heterogenous, yet was poorly visible owing to artifactual interference.

**IMAGING PERFORMED BY**

Crystal Hill, RVT

A minimal amount of liver was visible owing to artifact interference.

The gastrointestinal tract appeared unremarkable.

**HOSPITAL NAME**

Preston AC

**ULTRASONOGRAPHIC FINDINGS**

Mineralizing mass, suspected to be of uterine origin. This may represent residual fetal material/mummification

**REFERRING VET**

Dr. Karafilov

**INTERPRETATION OF THE FINDINGS & FURTHER RECOMMENDATIONS**

I recommend exploratory surgery with expectations towards ovarian hysterectomy. Inspection of this spleen is warranted.

**INVOICE**

31290

**DATE**

6/24/22



**PATIENT**

Buster Iraj

**SPECIES**

Lagomorph

**BREED**

Holland Lop

**SEX**

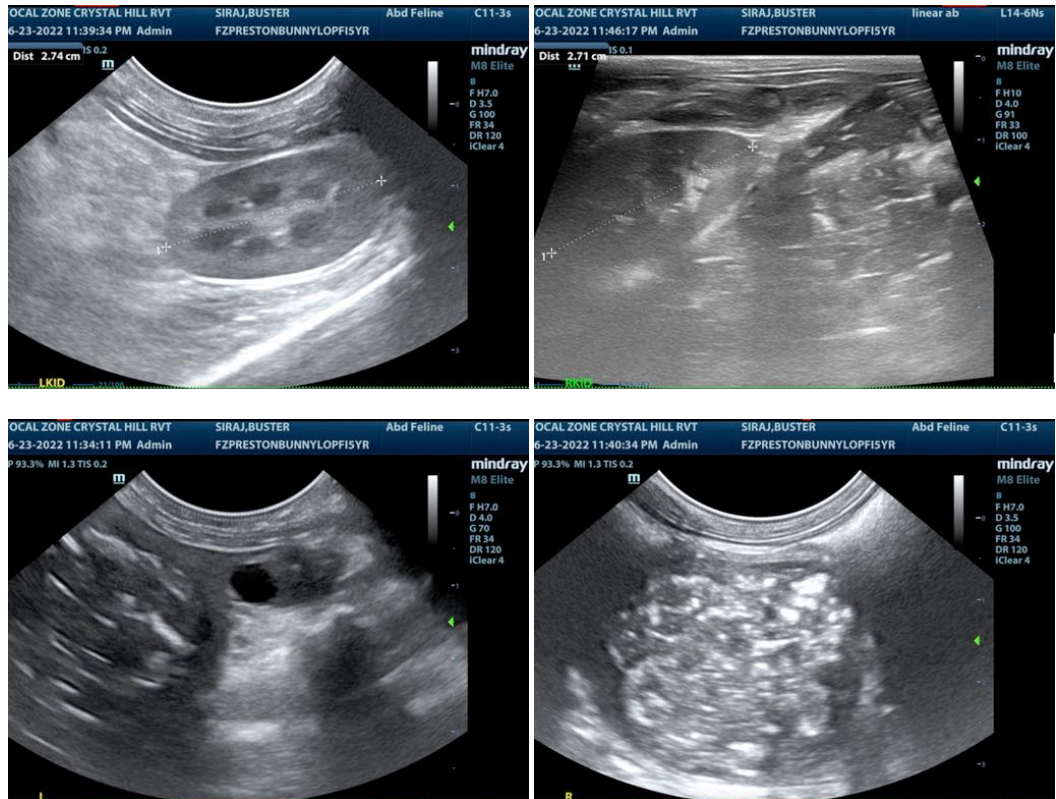
Intact female

**AGE**

5 years

**WEIGHT**

1.95 kg



**INTERPRETED BY**

Eric Lindquist, DMV  
DABVP, Cert. IVUSS

**IMAGING  
PERFORMED BY**

Crystal Hill, RVT

**HOSPITAL NAME**

Preston AC

**REFERRING VET**

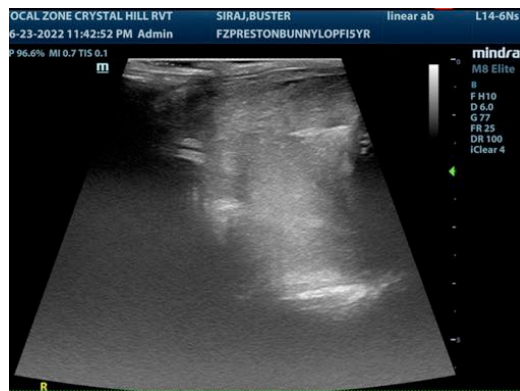
Dr. Karafilov

**INVOICE**

31290

**DATE**

6/24/22



The information and recommendations provided are based on the images presented by the referring veterinarian/sonographer. No evaluation can be communicated regarding pathology that was not visible in the image/video clips provided.

Thank you for this referral. If the clinical or image interpretation does not parallel your findings or if I can be of any further assistance please contact me.

Eric Lindquist, DMV, DABVP, Cert. IVUSS, CEO of SonoPath.com  
Eric.Lindquist@SonoPath.com