



PATIENT

Jordan Fielding

SPECIES

Canine

BREED

Cockapoo

SEX

Neutered male

AGE

14 years

WEIGHT

34 lbs

INTERPRETED BY

Eric Lindquist, DMV
DABVP, Cert. IVUSS

IMAGING PERFORMED BY

Kelly Reshny, RVT

HOSPITAL NAME

Maples AH

REFERRING VET

Dr. Kazienko

INVOICE

PRESENTING CLINICAL SIGNS

History: large lump, approx 8-10cm in diameter on left hind leg, not painful, does hinder some movement.

ULTRASONOGRAPHIC EXAMINATION

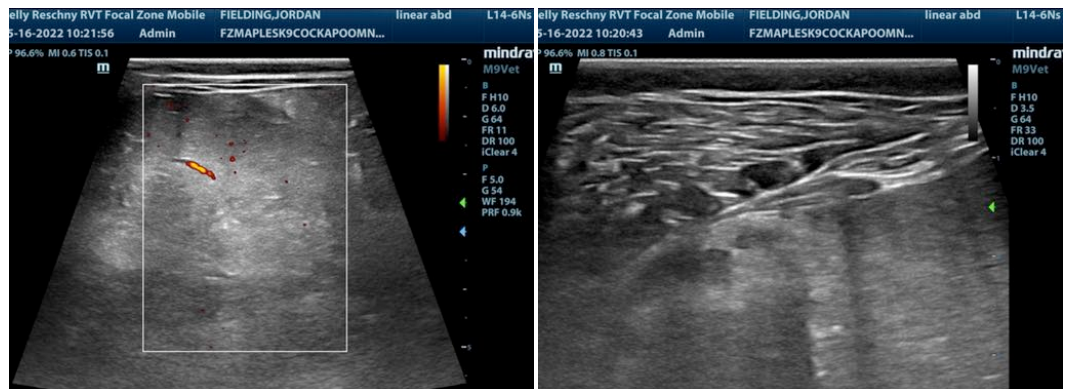
The hind leg region was imaged in this patient. Expansive, macronodular, mildly undifferentiated mass was noted with mild vascularity. A complex lipoma or liposarcoma or muscle based sarcoma is possible. Core biopsy is recommended. CT evaluation is ideal. A minimal amount of inflammatory response is noted in this patient. This appears to be somewhat encapsulated, which would suggest that it is within the muscle belly. No bony lysis is noted in the image set provided.

ULTRASONOGRAPHIC FINDINGS

Large, fairly undifferentiated leg mass, muscle based or complicated lipoma/liposarcoma.

INTERPRETATION OF THE FINDINGS & FURTHER RECOMMENDATIONS

I recommend core biopsy in this patient as opposed to FNA is indicated for a definitive diagnosis.



The information and recommendations provided are based on the images presented by the referring veterinarian/sonographer. No evaluation can be communicated regarding pathology that was not visible in the image/video clips provided.

Thank you for this referral. If the clinical or image interpretation does not parallel your findings or if I can be of any further assistance please contact me.

Eric Lindquist, DMV, DABVP, Cert. IVUSS, CEO of SonoPath.com
Eric.Lindquist@SonoPath.com

DATE

5/4/22