



**PATIENT**

Winston Glogowski

**PRESENTING CLINICAL SIGNS**

History: mass on neck, cranial to R shoulder, unsure of duration, very firm on palpation

**SPECIES**

Canine

**BREED**

Doodle

**SEX**

Intact male

**AGE**

5 months

**WEIGHT**

14.5 kg

**ULTRASONOGRAPHIC EXAMINATION**

A 3.8 x 2.0 cm deep ossified, circumscribed mass was noted in this patient deep to superficial muscle adjacent to the jugular vein. It appears to be resectable. The mass appears to be within the regional muscle with ossification of regional muscle tissue, yet given the circumscribed nature embryonic ectopic origin of tissue ossification is likely. This appears resectable. However, given the vascular structures in the region I recommend CT evaluation for surgical planning. Slight lymph node enlargement was noted and measured 8 x 4 mm. This is likely a normal variant.

**ULTRASONOGRAPHIC FINDINGS**

Ossified mass, likely ectopic embryonic origin. Appears to be deriving from the muscle belly cranial to the shoulder. Suspect teratoma, dermoid cyst is possible.

**INTERPRETATION OF THE FINDINGS & FURTHER RECOMMENDATIONS**

There was no evidence of inflammation. This appears resectable. The hard palpation is owing to the ossification of the mass; however, there is no evident inflammation present to suggest foreign body or other origin.

**INTERPRETED BY**

Eric Lindquist, DMV  
DABVP, Cert. IVUSS

**IMAGING PERFORMED BY**

Kelly Reshny, RVT

**HOSPITAL NAME**

East Credit VH

**REFERRING VET**

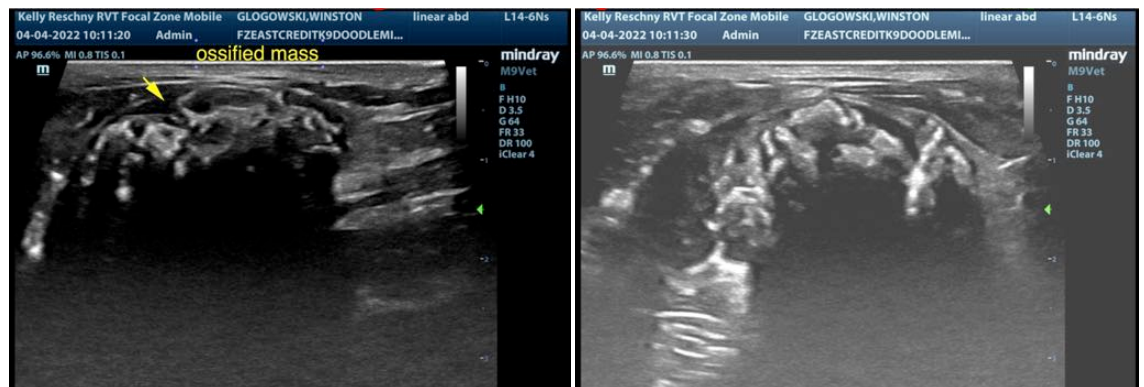Dr. Webster

**INVOICE**

98012

**DATE**

4/4/22





**PATIENT**

Winston Glogowski

**SPECIES**

Canine

**BREED**

Doodle

**SEX**

Intact male

**AGE**

5 months

**WEIGHT**

14.5 kg

**INTERPRETED BY**

Eric Lindquist, DMV  
DABVP, Cert. IVUSS

**IMAGING  
PERFORMED BY**

Kelly Reshny, RVT

**HOSPITAL NAME**

East Credit VH

**REFERRING VET**

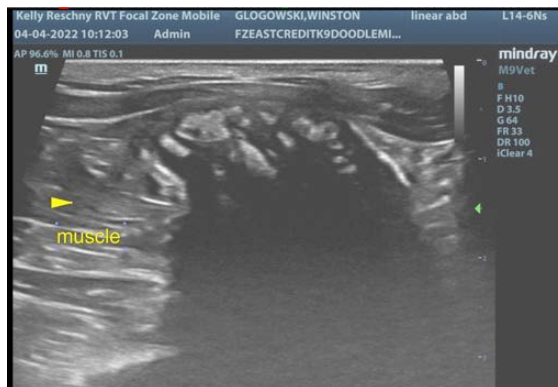
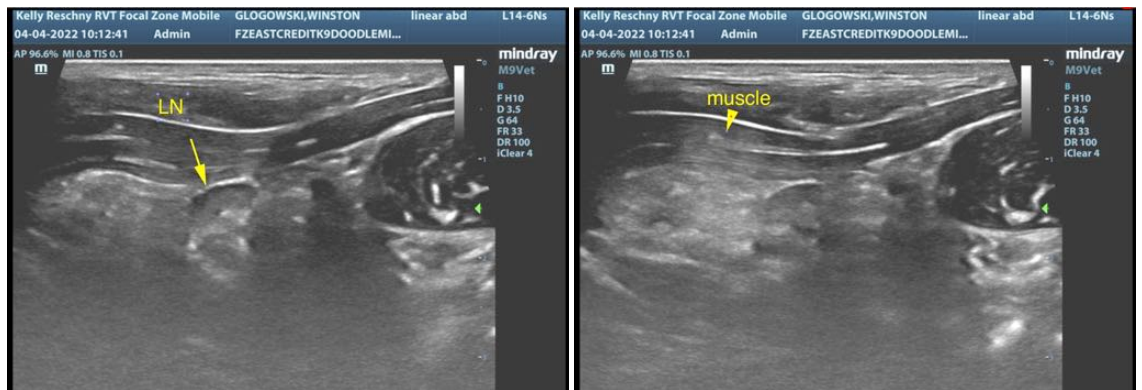
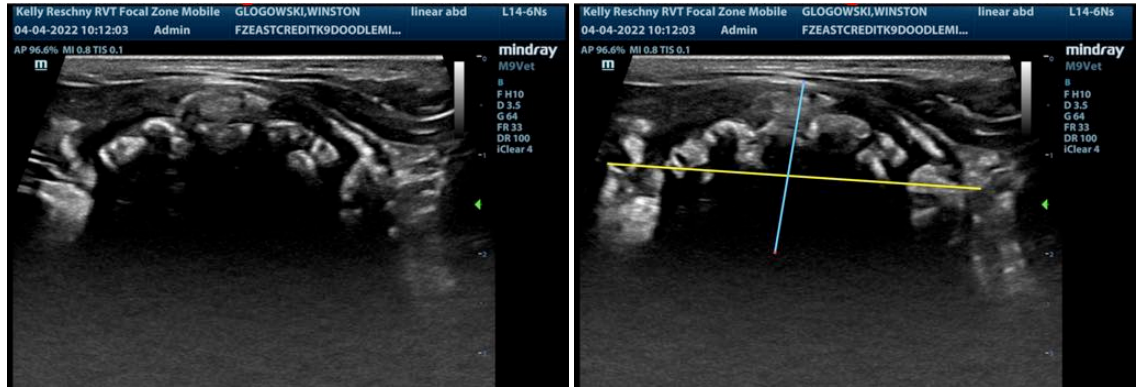
Dr. Webster

**INVOICE**

98012

**DATE**

4/4/22



The information and recommendations provided are based on the images presented by the referring veterinarian/sonographer. No evaluation can be communicated regarding pathology that was not visible in the image/video clips provided.

Thank you for this referral. If the clinical or image interpretation does not parallel your findings or if I can be of any further assistance please contact me.

Eric Lindquist, DMV, DABVP, Cert. IVUSS, CEO of SonoPath.com  
Eric.Lindquist@SonoPath.com