

PATIENT

Saffron Murdoch

PRESENTING CLINICAL SIGNS

History: murmur heard, Left side gr 3-4, right side gr 2, firm lump in thyroid area

SPECIES

Canine

BREED

Cavachon

SEX

Spayed female

AGE

4 years

WEIGHT

9 lbs

ULTRASONOGRAPHIC EXAMINATION OF THE THYROID

The cervical region was imaged in this patient. The left thyroid lobe, esophagus, trachea and salivary glands all appeared normal. The right thyroid lobe appeared to be unremarkable, yet the subcutaneous to fascial nodule is noted in this patient and measures 1.4 x 1.0 cm. Mixed, echogenic change was noted adjacent to the trachea, yet appears to be separate from it. I cannot create a direct connection to the right thyroid lobe, yet appears to impinge upon it. It appears encapsulated and resectable. FNA is warranted for further definition as to the origin. This could be salivary gland origin or possibly linked to the trachea or right thyroid lobe. It appears to be a separate structure. Underlying granuloma is possible. This does appear resectable. An intact left thyroid lobe appeared to be evident and measured 0.5 cm in width.

ULTRASONOGRAPHIC FINDINGS

Granulomatous type nodule, possible underlying neoplasia associated with the right thyroid lobe or trachea or salivary gland origin. Lesion is undifferentiated, yet encapsulated and appears resectable.

INTERPRETATION OF THE FINDINGS & FURTHER RECOMMENDATIONS

CT of the thyroid region would be ideal for surgical planning. FNA is recommended for further definition from a cytological standpoint.

INTERPRETED BY

Eric Lindquist, DMV
DABVP, Cert. IVUSS

IMAGING PERFORMED BY

Kelly Reshny, RVT

HOSPITAL NAME

Maples AH

REFERRING VET

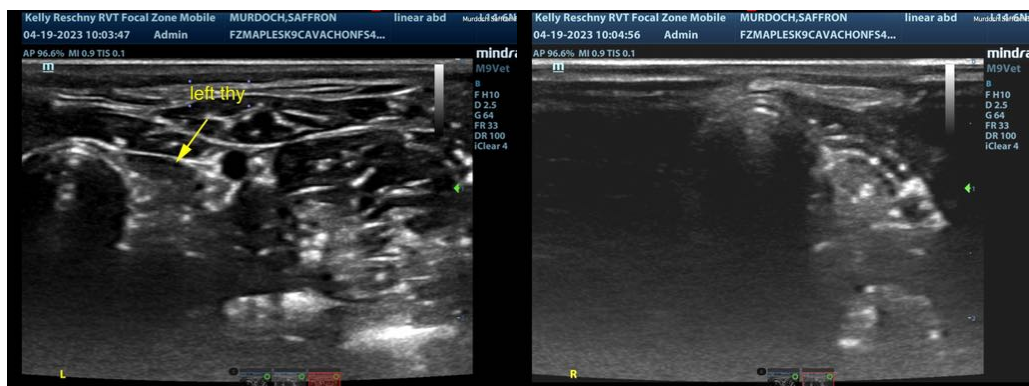
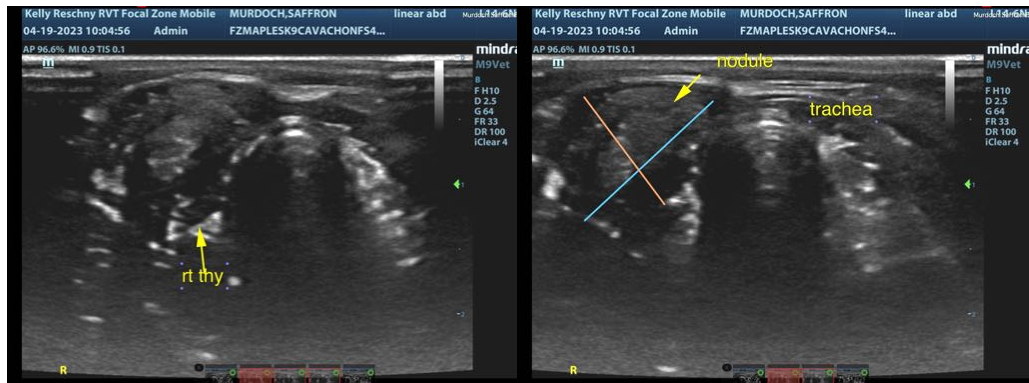
Dr. Kazienko

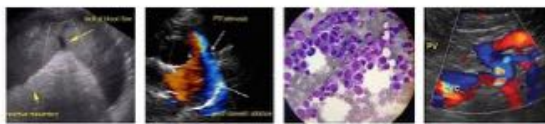
INVOICE

43881

DATE

4/19/23





PATIENT

Saffron Murdoch

SPECIES

Canine

BREED

Cavachon

SEX

Spayed female

AGE

4 years

WEIGHT

9 lbs

INTERPRETED BY

Eric Lindquist, DMV
DABVP, Cert. IVUSS

**IMAGING
PERFORMED BY**

Kelly Reshny, RVT

HOSPITAL NAME

Maples AH

REFERRING VET

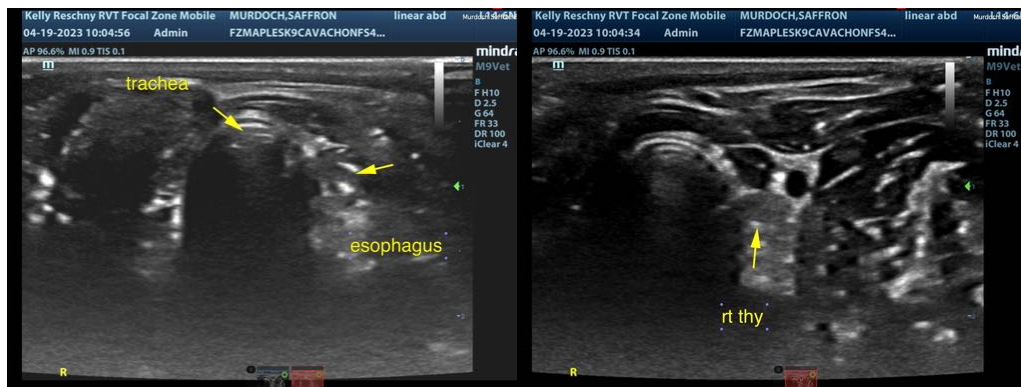
Dr. Kazienko

INVOICE

43881

DATE

4/19/23



The information and recommendations provided are based on the images presented by the referring veterinarian/sonographer. No evaluation can be communicated regarding pathology that was not visible in the image/video clips provided.

Thank you for this referral. If the clinical or image interpretation does not parallel your findings or if I can be of any further assistance please contact me.

Eric Lindquist, DMV, DABVP, Cert. IVUSS, CEO of SonoPath.com
Eric.Lindquist@SonoPath.com