

**PATIENT**

Roxie Konick

**PRESENTING CLINICAL SIGNS**

History: accidental breeding, suspect they tied Dec 21/22

**SPECIES**

Canine

**ULTRASONOGRAPHIC EXAMINATION**

A positive pregnancy was noted in this patient near term. Fetus measured approximately 9.0 cm. Active fetal movement was noted. Amniotic fluid was anechoic. There were at least 3 fetuses that appeared to be present all of which reveal live and active movement. Gestation is roughly 50-60 days.

**BREED**

Husky

**ULTRASONOGRAPHIC FINDINGS**

Near term viable pregnancy.

**SEX**

Intact female

**INTERPRETATION OF THE FINDINGS & FURTHER RECOMMENDATIONS**

**AGE**

There are approximately 3+ fetuses.

3 years

**WEIGHT**

60 lbs

**INTERPRETED BY**

Eric Lindquist, DMV  
DABVP, Cert. IVUSS

**IMAGING PERFORMED BY**

Kelly Reshny, RVT

**HOSPITAL NAME**

Royal VH

**REFERRING VET**

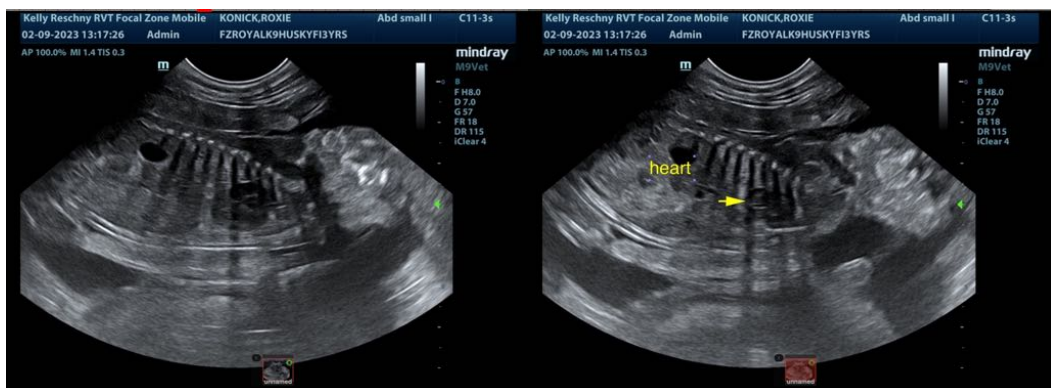
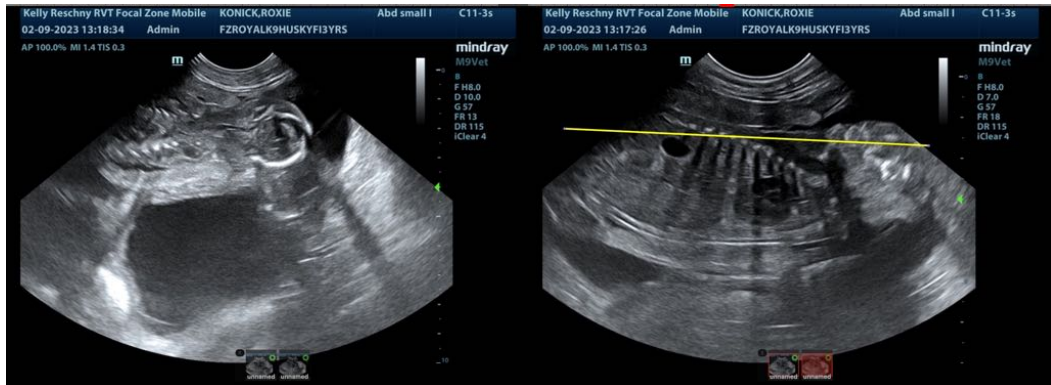
Dr. Jaffery

**INVOICE**

42679

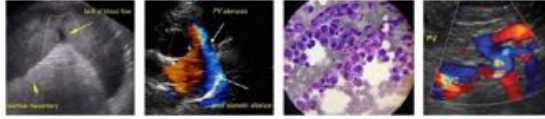
**DATE**

2/9/23



The information and recommendations provided are based on the images presented by the referring veterinarian/sonographer. No evaluation can be communicated regarding pathology that was not visible in the image/video clips provided.

Thank you for this referral. If the clinical or image interpretation does not parallel your findings or if I



**PATIENT**

can be of any further assistance please contact me.

Roxie Konick

**Eric Lindquist**, DMV, DABVP, Cert. IVUSS, CEO of SonoPath.com  
Eric.Lindquist@SonoPath.com

**SPECIES**

Canine

**BREED**

Husky

**SEX**

Intact female

**AGE**

3 years

**WEIGHT**

60 lbs

**INTERPRETED BY**

Eric Lindquist, DMV  
DABVP, Cert. IVUSS

**IMAGING  
PERFORMED BY**

Kelly Reshny, RVT

**HOSPITAL NAME**

Royal VH

**REFERRING VET**

Dr. Jaffery

**INVOICE**

42679

**DATE**

2/9/23