



PATIENT

Chestnut Ralph

PRESENTING CLINICAL SIGNS

History: abdominal mass palpated

SPECIES

ULTRASONOGRAPHIC EXAMINATION OF THE ABDOMEN

Urinary System

BREED

Abyssinian

The **urinary bladder**, trigone, and pelvic urethra presented normal thicknesses and normal tone. The ureters were not visible which is normal. No uroliths or sediment were visualized and anechoic urine was present. No evidence of inflammatory or neoplastic changes was noted. Ureteral papillae were normal.

SEX

Intact female

The uterus was uniform and measured 0.3 cm. A 4.4 cm cyst was noted in the caudal abdomen. This is likely of ovarian origin.

AGE

3 years

The **kidneys** revealed normal size and structure, corticomedullary definition and ratio for this age. The cortices presented largely uniform texture with normal echogenic relationship to liver and spleen. Medullary structure differed distinctly from the cortex and no evidence of pelvic dilation was present. The capsules were acceptably uniform without significant irregularities. The left kidney measured 2.5 cm. The right kidney measured 2.67 cm.

WEIGHT

1.28 kg

Adrenal Glands

Both **adrenal glands** were visualized and recognized as having normal shape, size, position and echogenicity for this breed. The phrenic vasculature, glandular echogenicity and detail were unremarkable. Capsule, cortex, and medullary definition were normal for this age patient. The left adrenal gland measured 0.4 cm.

INTERPRETED BY

Eric Lindquist, DMV
DABVP, Cert. IVUSS

Spleen

IMAGING PERFORMED BY

Kelly Reshny, RVT

The **spleen** presented a smooth homogeneous parenchyma hyperechoic to liver and renal cortical parenchyma. The capsule was smooth without noticeable expansion or deviation from within the spleen or adjacent pathology. The splenic vasculature demonstrated normal volume without signs of congestion or thrombosis. No sonographic evidence of acute or chronic inflammatory, neoplastic, or infarctual changes was noted.

HOSPITAL NAME

Nelson AH

Liver

REFERRING VET

Dr. Anderson

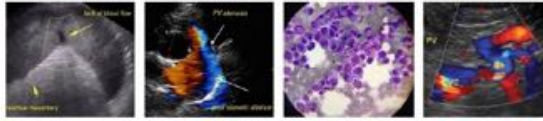
The **liver** images submitted revealed subjectively normal liver size, contour, and structure. Parenchymal echogenicity was naturally coarse and hypoechoic to the spleen. Vascular and biliary tracts were of normal volume with no evidence of congestion. The gallbladder presented acceptably thin walls with primarily anechoic content. The cystic and common bile ducts were normal. No pathological hepatic lymphadenopathy was evident. No overt structural evidence of inflammatory, infiltrative or regenerative pathology was evident.

INVOICE

42982

DATE

1/27/23



PATIENT

Gastrointestinal

Chestnut Ralph

Examination of the **gastrointestinal tract** revealed a stomach and intestine free of stasis, of normal wall thickness, acceptable curvilinear mural detail, and peristaltic activity. Small and large intestine demonstrated normal luminal chyme and stool consistency respectively. No obstructive or overt infiltrative disease was noted. No associated abnormal lymphatic activity was noted.

SPECIES

BREED

Abyssinian

Pancreas

The base and limbs of the **pancreas** were observed to be largely isoechoic to surrounding omental fat. Pancreatic duct and capsular contour were acceptably normal and parenchyma respected normal curvilinear patterns. No overt evidence of active inflammatory or neoplastic disease was noted.

SEX

Intact female

Free Abdomen

A mild amount of free fluid was noted in the caudal abdomen.

AGE

3 years

ULTRASONOGRAPHIC FINDINGS

WEIGHT

1.28 kg

Subjectively benign cyst, likely of ovarian origin

INTERPRETATION OF THE FINDINGS & FURTHER RECOMMENDATIONS

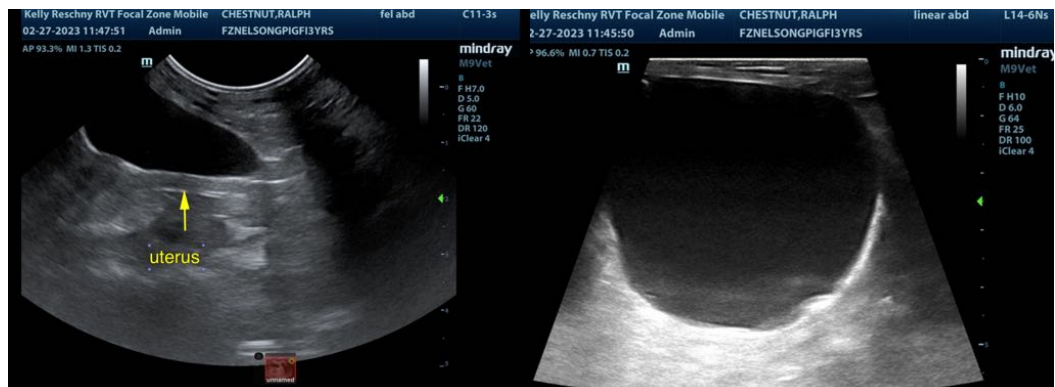
INTERPRETED BY

Eric Lindquist, DMV
DABVP, Cert. IVUSS

The cysts appear surgically resectable. Exploratory surgery is indicated.

IMAGING PERFORMED BY

Kelly Reshny, RVT



HOSPITAL NAME

Nelson AH

REFERRING VET

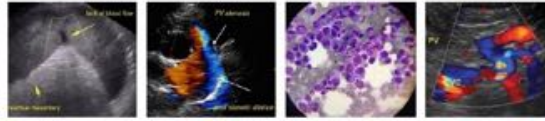
Dr. Anderson

INVOICE

42982

DATE

1/27/23



PATIENT

Chestnut Ralph

SPECIES

BREED

Abyssinian

SEX

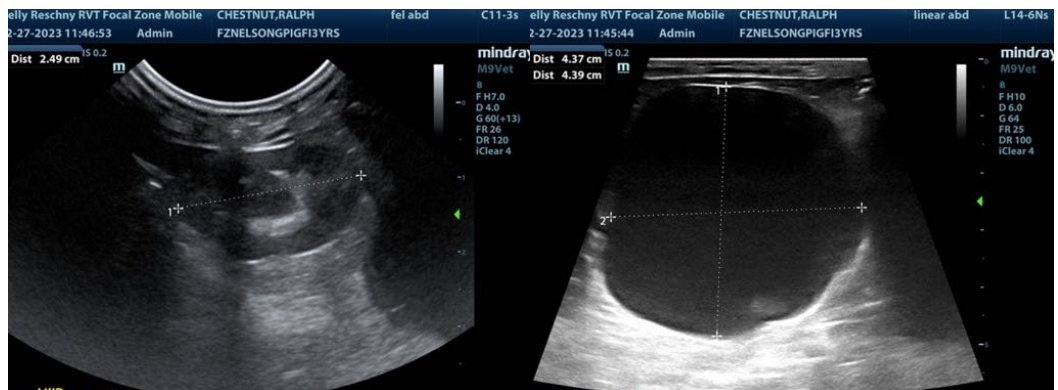
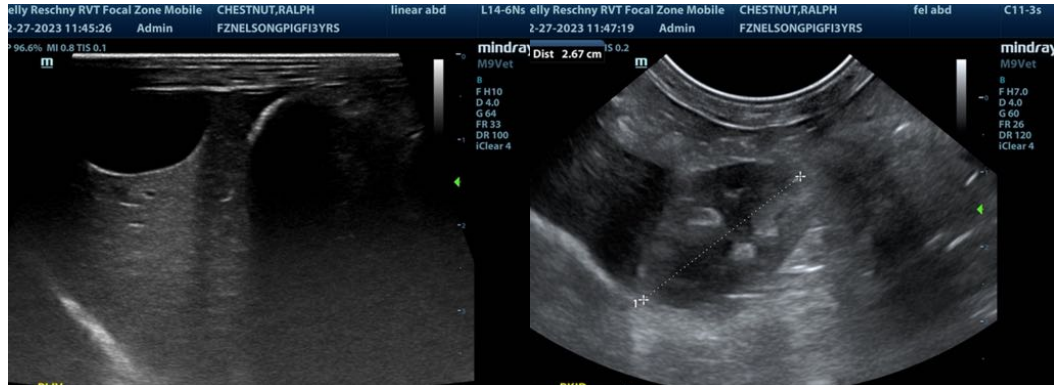Intact female

AGE

3 years

WEIGHT

1.28 kg



INTERPRETED BY

Eric Lindquist, DMV
DABVP, Cert. IVUSS

IMAGING PERFORMED BY

Kelly Reshny, RVT

HOSPITAL NAME

Nelson AH

REFERRING VET

Dr. Anderson

INVOICE

42982

DATE

1/27/23

The information and recommendations provided are based on the images presented by the referring veterinarian/sonographer. No evaluation can be communicated regarding pathology that was not visible in the image/video clips provided.

Thank you for this referral. If the clinical or image interpretation does not parallel your findings or if I can be of any further assistance please contact me.

Eric Lindquist, DMV, DABVP, Cert. IVUSS, CEO of SonoPath.com
Eric.Lindquist@SonoPath.com