



PATIENT PRESENTING CLINICAL SIGNS

Luke Walker

IRREGULAR HEART, NEURO ISSUES DDX: BRAIN LESION (TUMOUR), HEART DISEASE (HCM OR OTHER) RECOMMEND STARTING WITH SR PROFILE, ECHO, ECG, O OK WITH THIS TESTING, O WOULD LIKE TO TRY LIQUID PHENO AS SHE FEELS P IS NOT GETTING MEDS PROPERLY, DISCUSSED HIGH SUSPICION OF BRAIN TUMOUR, HEART DISEASE, WILL TREAT PEDNING RESULTS...on Phenobarb. Grade 2/6 heart murmur and arrhythmia.

SPECIES

Feline

BREED

Domestic Shorthair

SEX

Neutered male

AGE

13 years

WEIGHT

5.8 kg

ULTRASONOGRAPHIC EXAMINATION OF THE HEART

The echocardiogram in this patient demonstrated normal **left atrial** size based on 3 separate LA measurements. The cranial and caudal **mitral** valve leaflets presented normal linear structure and kinetics.. The **left ventricle** presented normal thicknesses with linear contour and was not dilated nor restricted. The **myocardium** presented normal echogenicity without subjective evidence of significant fibrotic or ischemic disease. **Contractility** of the ventricular walls was adequate and in normal range for this patient evidenced by the fractional shortening measurement and subjective evaluation of the different regions and angles of the myocardium. The **left ventricular outflow** tract demonstrated normal laminar flow and subjective structural integrity. The **right atrium** and auricle revealed normal size, structure and content. No evidence of masses was noted or chamber overload. **Tricuspid** valvular assessment demonstrated adequate linear morphology and kinetics. The **right ventricle** was of normal size (1/3 diameter of LV), chordae structure, myocardial echogenicity and thickness. **Pulmonic** tract assessment revealed normal valve structure, laminar flow, and diameter (approx.1:1 pa/ao ratio). No visible **pericardial** or free pleura fluid was noted or extra cardiac pathology in the visible planes. The cranial **mediastinum and pericardial regions** were free of masses in the visible window. Periodic arrhythmia was noted in this patient.

INTERPRETED BY

Eric Lindquist, DMV
DABVP, Cert. IVUSS

IMAGING PERFORMED BY

Crystal Hill

HOSPITAL NAME

Beatties PH Stoney
Creek

REFERRING VET

94797

INVOICE

94797

DATE

12/21/21

FELINE CARDIAC PARAMETERS	BODY WEIGHT (kg)	HR (BPM)	IVSd (cm)	LVIDd (cm)	LVWd (cm)	FS (%)	EF (%)
NORMAL PARAMETER	-----	150-240	0.3-0.6	1.0-2.1	0.25-0.6	35-67	80-100
PATIENT	5.8	112	0.49	1.49	0.49	51	86
FELINE CARDIAC PARAMETERS	LA/AO (Boon)	LA/AO HEART BASE (Sisson)	LA 2D 4-chamber long axis AS to FW (Sisson) (cm)	LVOT VEL. (m/s)	RVOT VEL. (m/s)	IVRT (m/)	
NORMAL PARAMETER	<1.5	0.88-1.79	0.7-1.7	<1.6	<1.3	40-60	
PATIENT	1.1	1.1	1.0	1.25	1.25	NM	

Adapted from June Boon, Veterinary Echocardiography, 1998
Sisson D et al. JVIM 1991; 5: 232, Jacobs et al. Am J Vet Res 1985; 46:1705



PATIENT **ULTRASONOGRAPHIC FINDINGS**

Luke Walker Structurally normal structure and function echocardiogram with arrhythmia.

SPECIES **INTERPRETATION OF THE FINDINGS & FURTHER RECOMMENDATIONS**

Feline No primary treatment based on cardiac disease is noted unless the arrhythmia necessitates treatment based on cardiology review. However, structurally and functionally the heart is normal with normal volumes.

BREED

Domestic Shorthair

SEX

Neutered male

AGE

13 years

WEIGHT

5.8 kg

INTERPRETED BY

Eric Lindquist, DMV
DABVP, Cert. IVUS

**IMAGING
PERFORMED BY**

Crystal Hill

HOSPITAL NAME

Beatties PH Stoney
Creek

REFERRING VET

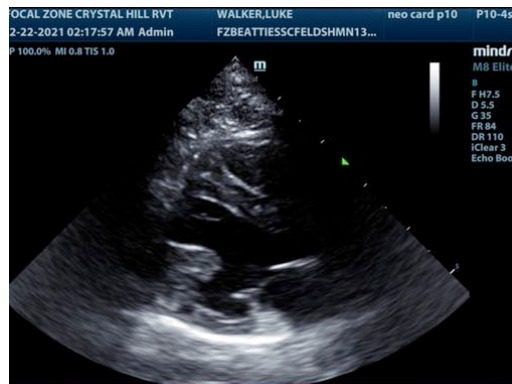
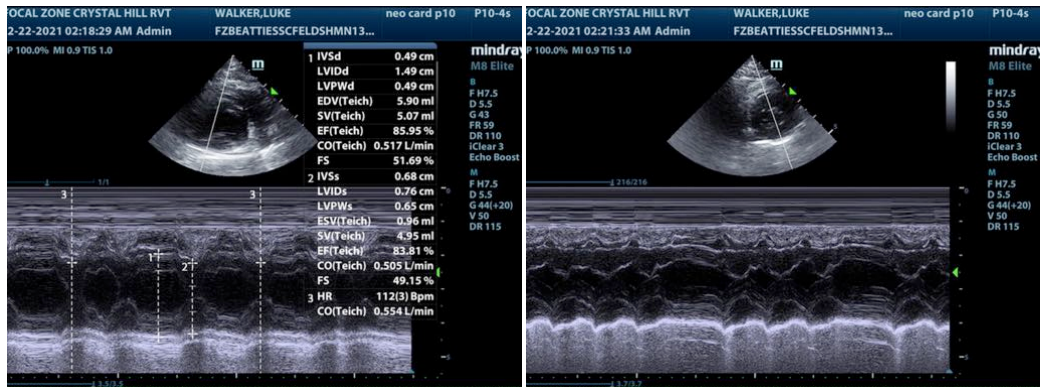
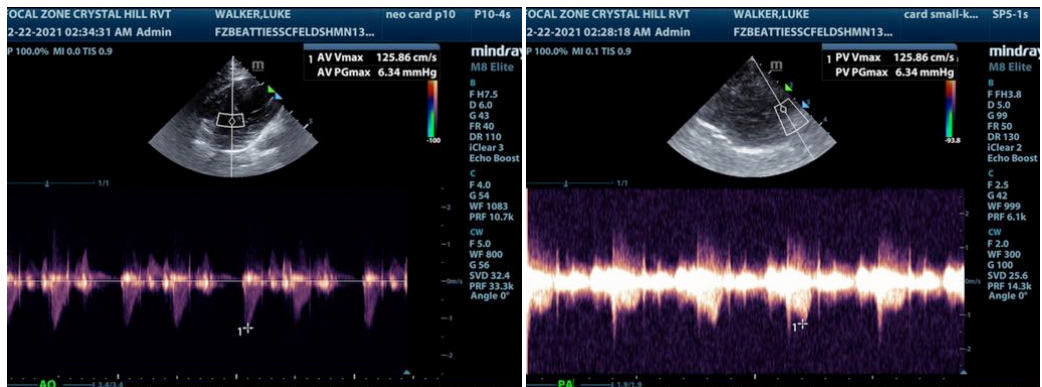
94797

INVOICE

94797

DATE

12/21/21



The information and recommendations provided are based on the images presented by the referring veterinarian. No evaluation can be communicated regarding pathology that was not visible in the



PATIENT

image/video clips provided.

Luke Walker

Thank you for this referral. If the clinical or image interpretation does not parallel your findings or if I can be of any further assistance please contact me.

SPECIES

Feline

Eric Lindquist, DMV, DABVP, Cert. IVUSS, CEO of SonoPath.com
Eric.Lindquist@SonoPath.com

BREED

Domestic Shorthair

SEX

Neutered male

AGE

13 years

WEIGHT

5.8 kg

INTERPRETED BY

Eric Lindquist, DMV
DABVP, Cert. IVUSS

**IMAGING
PERFORMED BY**

Crystal Hill

HOSPITAL NAME

Beatties PH Stoney
Creek

REFERRING VET

94797

INVOICE

94797

DATE

12/21/21