


**PATIENT**

 Domi Sato Saved Dog  
 Rescue

**SPECIES**

Canine

**BREED**

Pug

**SEX**

Intact male

**AGE**

10 years

**WEIGHT**

9.7 kg

**PRESENTING CLINICAL SIGNS**

History: possible 1/6 systolic murmur, but difficult to appreciate with reverberated breath sounds coughing recently. Possible improvement slightly on Furosemide. Furosemide 10mg BID. Was coughing some wet discharge from nose during scan. higher VHS on rads

**ULTRASONOGRAPHIC EXAMINATION OF THE HEART**

The echocardiogram in this patient demonstrated normal **left atrial** size based on 3 separate methods of LA evaluation. Minor **mitral** valve insufficiency is noted in this patient with a centralized jet and minimal filling of the left atrium. The **left ventricle** presented thicknesses with linear contour and was not dilated nor restricted. The **myocardium** presented normal echogenicity without subjective evidence of significant fibrotic or ischemic disease. **Contractility** of the ventricular walls was adequate and in normal range for this patient evidenced by the fractional shortening measurement and subjective evaluation of the different regions of the myocardium. The **left ventricular outflow** tract demonstrated normal laminar flow and subjective structural integrity. The **right atrium** and auricle revealed normal size, structure and content. No evidence of masses was noted. **Tricuspid** valvular assessment demonstrated adequate linear morphology and kinesis. The **right ventricle** was of normal size (1/3 diameter of LV), chordae structure, myocardial echogenicity and thickness. **Pulmonary outflow** tract assessment revealed normal valve structure, laminar flow, and diameter (approx. 1:1 pa/ao ratio). No visible **pericardial** or free pleura fluid was noted. The cranial **mediastinum and pericardial and extra-cardiac regions** were free of masses in the visible window. Pronounced arrhythmia is noted in this patient; however, it would suggest sinus arrhythmia. Mild excessive thoracic fat was noted around the heart which may give radiographic appearance of cardiomegaly, yet chamber size and function are normal.

**INTERPRETED BY**

 Eric Lindquist, DMV  
 DABVP, Cert. IVUSS

**IMAGING PERFORMED BY**

Crystal Hill

**HOSPITAL NAME**

Queensway AH

**REFERRING VET**

Dr. Bilinsky

**INVOICE**

94568

**DATE**

12/14/21

CANINE CARDIAC PARAMETERS	MR VMAX (m/s)	TR VMAX (m/s)	LA/AO (Boon method)	LA/AO (Heart Base; Swe)	FS (%)	EF (%)	EPSS (cm)
NORMAL PARAMETER	4.5-5.5	<2.7	1.3	<1.6	28-40	40-100	<0.6
PATIENT			1.15	1.16	45	78	NM
CANINE CARDIAC PARAMETERS	HR (BPM)	AV VMAX (m/s)	PV MAX (m/s)	BODY WEIGHT (kg)	LA (2D short axis Base view) (cm)	LVIDd (Avg; 2D and m-mode short axis) (cm)	LVIDs (Avg; 2D and m-mode short axis) (cm)
NORMAL PARAMETER	50-100	0.7-1.7	0.7-1.6				
PATIENT		1.37	1.18	9.7		2.58	



**PATIENT**

Domi Sato Saved Dog  
Rescue

**SPECIES**

Canine

**BREED**

Pug

**SEX**

Intact male

**AGE**

10 years

**WEIGHT**

9.7 kg

**INTERPRETED BY**

Eric Lindquist, DMV  
DABVP, Cert. IVUSS

**IMAGING  
PERFORMED BY**

Crystal Hill

**HOSPITAL NAME**

Queensway AH

**REFERRING VET**

Dr. Bilinsky

**INVOICE**

94568

**DATE**

12/14/21

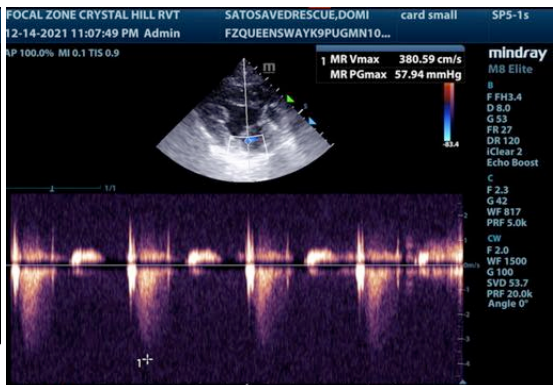
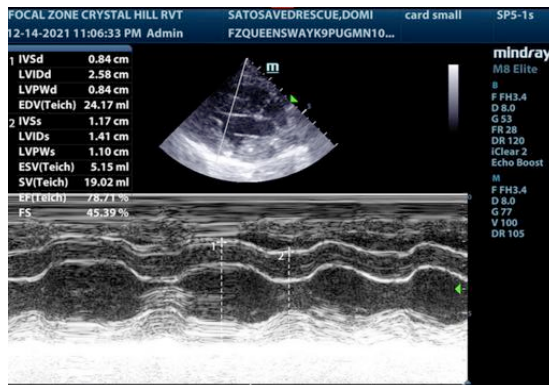
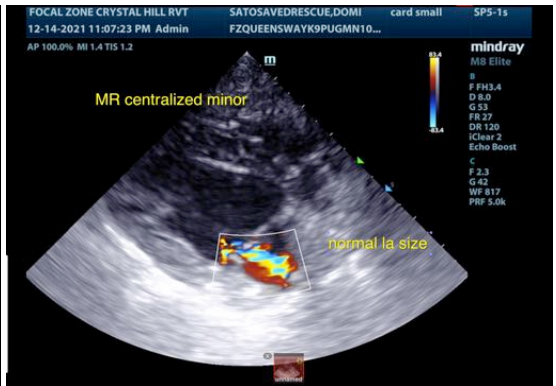
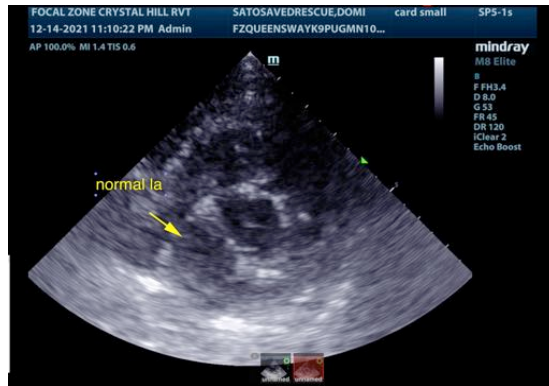
**ULTRASONOGRAPHIC FINDINGS**

Minor mitral insufficiency, not clinically significant.

Early stage B1 valvular disease.

**INTERPRETATION OF THE FINDINGS & FURTHER RECOMMENDATIONS**

If anesthesia is necessary, there is no overt contraindication to an anesthetic procedure. Suggested protocol includes Torbutrol premed, Propofol induction, and Isoflurane maintenance. Recheck echocardiogram in 6 months or earlier if murmur grade increases or clinical signs initiate. Baseline EKG is warranted to ensure that pathological arrhythmia is not present. The clinical signs are not cardiogenic in this patient. Furosemide effect is likely working upon a bronchodilator and anti-inflammatory effect as well as drying respiratory secretions, yet there is no cardiac indication for diuretics in this patient. Primary respiratory protocol is warranted with bronchodilators and potential broad spectrum antibiotics with a potential inhaled corticosteroids. Blood pressure measurements are warranted. If systolic pressure is > 160 then ace inhibitor therapy is indicated.





**PATIENT**

Domi Sato Saved Dog  
Rescue

**SPECIES**

Canine

**BREED**

Pug

**SEX**

Intact male

**AGE**

10 years

**WEIGHT**

9.7 kg

**INTERPRETED BY**

Eric Lindquist, DMV  
DABVP, Cert. IVUSS

**IMAGING  
PERFORMED BY**

Crystal Hill

**HOSPITAL NAME**

Queensway AH

**REFERRING VET**

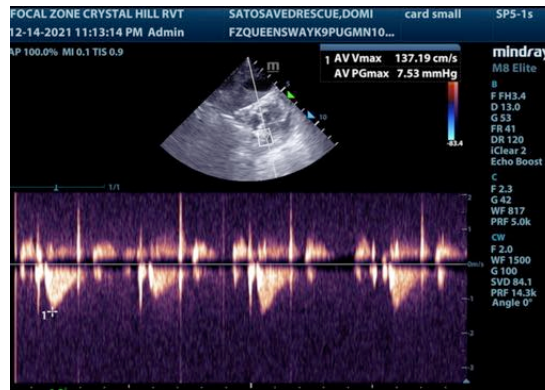
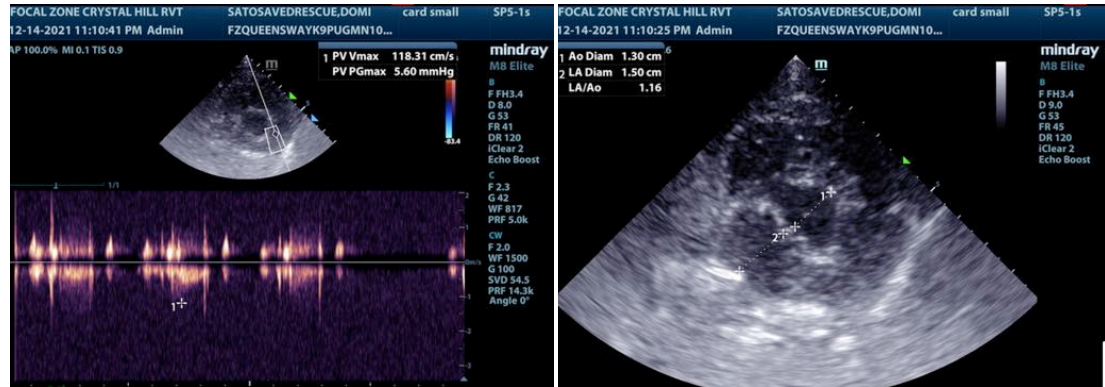
Dr. Bilinsky

**INVOICE**

94568

**DATE**


12/14/21



The information and recommendations provided are based on the images presented by the referring veterinarian. No evaluation can be communicated regarding pathology that was not visible in the image/video clips provided.

Thank you for this referral. If the clinical or image interpretation does not parallel your findings or if I can be of any further assistance please contact me.

**Eric Lindquist, DMV, DABVP, Cert. IVUSS, CEO of SonoPath.com**  
Eric.Lindquist@SonoPath.com



The following is an applicable excerpt from the *Curbside Guide to Diagnosis & Treatment of Sonographic Disease* offered by [SonoPath.com](http://sonopath.com) Lindquist, Frank, Lobetti, and Modler.

An essential quick guide for every general practitioner and sonographer.

<https://sonopath.com/products/curbside-guide-editing-due-release-12012015>

**Respiratory Disease in Dogs and Cats**

<http://www.sonopath.com/Respiratory>



**PATIENT**

Domi Sato Saved Dog  
Rescue

**SPECIES**

Canine

**BREED**

Pug

**SEX**

Intact male

**AGE**

10 years

**WEIGHT**

9.7 kg

**INTERPRETED BY**

Eric Lindquist, DMV  
DABVP, Cert. IVUSS

**IMAGING  
PERFORMED BY**

Crystal Hill

**HOSPITAL NAME**

Queensway AH

**REFERRING VET**

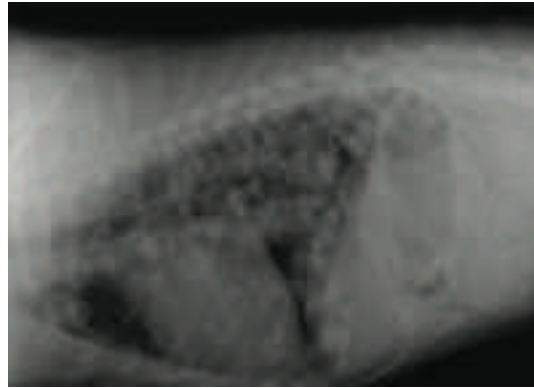
Dr. Bilinsky

**INVOICE**

94568

**DATE**

12/14/21



Right lateral view of the thorax in a dog with lung metastases. Note the presence of multifocal interstitial nodules of varying size and the expanded lung fields.

**Description:** Infections, allergies, parasites, foreign bodies, fungi, or neoplasia can all cause respiratory disease. Efficacious therapy maximizes the precise targeting of the causative agent and minimizes the suppression of the body's own defense mechanisms (i.e., mucociliary activity, bronchus-associated lymph tissue and reflexes). Therefore, respiratory therapy is most effective if it is determined based on cytology and culture and sensitivity results obtained from a bronchoalveolar lavage (BAL) or a transtracheal wash. If lung consolidations are imaged sonographically, ultrasound-guided FNA or even core biopsy may be performed. The BAL or transtracheal wash results will also dictate the level of therapy needed to control or resolve the pathology. If the patient is in acute respiratory distress, stabilization is vital before any attempt is made to obtain cytology and culture samples.

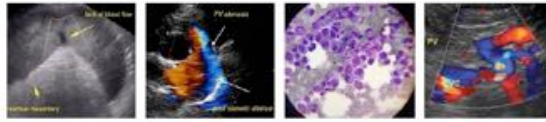
Acute Respiratory Distress Syndrome (ARDS) must be kept in mind in cases of acute respiratory distress, which sometimes mimics congestive heart failure (CHF) in dogs and causes non-cardiogenic pulmonary edema. The following risk factors have been identified for ARDS:

**Direct Pulmonary Injury:**

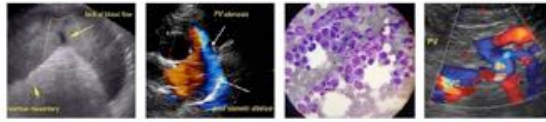
- Microbial pneumonia
- Aspiration pneumonia
- Strangulation
- Hyperoxia
- Sepsis
- Parvovirus
- Paraquat poisoning
- Shock
- Trauma
- Bee envenomation

**Indirect Pulmonary Injury:**

- Parasitic pneumonitis
- Smoke inhalation
- Pulmonary contusions
- Lung lobe torsion
- Babesiosis
- SIRS
- Pancreatitis
- Gastric and splenic torsion
- Multiple transfusions
- Disseminated intravascular coagulation



<b>PATIENT</b>	Pulmonary thromboembolic disease should also be considered in older patients that have predisposing underlying diseases, such as Cushing's syndrome, diabetes, protein-losing disease, neoplasia, pulmonary hypertension, congestive cardiac disease, chronic infectious disease, and so forth. Clinical signs may initiate with minor unexplained tachypnea and restlessness or persistent "allergic"-type coughs (especially those that present at night), and can progress to fulminant respiratory distress and rapid right heart enlargement due to ensuing pulmonary hypertension. (See the chapter on "Right Heart Disease" for further details regarding this phenomenon.)
Domi Sato Saved Dog Rescue	
<b>SPECIES</b>	
Canine	
<b>BREED</b>	<b>Clinical Signs:</b> Clinical signs can vary and will depend on the underlying etiology. A cough may be productive or non-productive, and increased effort may be noted upon inspiration, expiration, or both. Crackles, wheezes, rales, and pleural rubs may also be heard over various lung fields.
Pug	
<b>SEX</b>	<b>Diagnostics:</b> Nasal swabs are of no value as they do little more than identify normal flora; however, tissue scrapings provide information that is more meaningful. In cases of primary bacterial infection, culture and sensitivity results derived from BAL samples will usually reveal heavy growth of pathogenic bacteria; light to moderate growth generally reveals normal bacterial flora. Typically, the normal cytologic population is comprised of 70-80% monocytes. An elevated lymphocyte presence may be indicative of lymphoma and can be followed up with PCR testing of the lavage fluid. One should consider the location of infiltrates on the thoracic radiographs as well as the level of culture growth in order to determine which antibiotics to prescribe. Fungal organisms are commonly missed on transtracheal washes but usually found upon BAL. When faced with chronic nasal discharge in cats, it can be helpful to conduct fungal serology ( <i>Cryptococcus</i> spp. is often found); however, false positive results are common, especially in cases of <i>Histoplasma</i> and <i>Blastomycosis</i> .
Intact male	
<b>AGE</b>	
10 years	
<b>WEIGHT</b>	<b>Treatment:</b> Therapy is directed at controlling secretions with antibiotics and steroids, as justified by culture and sensitivity and cytology results, respectively. Respiratory diseases are often complicated by secondary bacterial infection. Gram-positive organisms inhabit the upper airways, whereas gram-negative organisms reside in the lower airway tissues in minimally oxygenated environments. Given the presence of the blood-bronchus barrier, many systemic antibiotics do not reach the therapeutic concentrations necessary to be effective against the etiologic or complicating organism. For example, only 4% of amoxicillin given parenterally ever reaches bronchial secretions, whereas gentamicin provides 25% penetration. Therefore, aerosol or intratracheal injection (diluted in 2 ml saline) therapy for 3-5 days initially, followed by systemic treatment, is the best approach for moderate to severe diseases affecting the bronchial tree. Cytology results may justify a tapering prednisone protocol (0.5 mg/kg PO BID, with appropriate tapering after the abatement of symptoms). Excessive mast cells, lymphocytes, and/or plasma cells may justify cortisone therapy. Alternatively, cyclosporin can be considered to inhibit infiltrates in poorly responsive cases. Hypoallergenic dietary trials are justified if an allergic etiology is a concern. A non-productive cough can be treated with hydrocodone (0.22mg/kg PO Q4-6hr, as needed). Productive coughs require percussion therapy along with bronchodilators, such as albuterol (20ug/kg PO BID x 5d) for dogs or terbutaline for cats (0.625 mg PO BID-TID or 0.01 mg/kg SQ in a crisis). Bronchodilators are indicated if crackles, elongated expiratory time and effort, tracheal collapse, flattened diaphragm, or cough are present. Non-generic extended-release theophylline (10 mg/kg PO BID) is the most effective given that dosages and release pharmacodynamics are product specific. Cyproheptadine can also be used in cats as a bronchodilator, as it interferes with smooth muscle contraction. For best penetration into the lung parenchyma, bronchodilators and steroid nebulizers should be used.
9.7 kg	
<b>INTERPRETED BY</b>	
Eric Lindquist, DMV DABVP, Cert. IVUSS	
<b>IMAGING PERFORMED BY</b>	
Crystal Hill	
<b>HOSPITAL NAME</b>	
Queensway AH	
<b>REFERRING VET</b>	
Dr. Bilinsky	
<b>INVOICE</b>	
94568	
<b>DATE</b>	Treatment of feline asthma depends on the stage of the disease. In an acute crisis, use epinephrine ([1:1000] 0.1-0.2 ml IV or SQ). A shock dose of a steroid, such as prednisolone, can also be given (2-4 mg/kg PO Q24hr, which can be tapered from 1.0 to 0.5 mg/kg PO Q48hr once signs are under control). Chronic management should include a bronchodilator, such as theophylline extended-release or terbutaline, at the doses outlined above. Cyproheptadine, a serotonin inhibitor, can also be given (2 mg PO Q24hr). Alternatively, the leukotriene inhibitor zafirlukast (Accolate) can be given at 5-10 mg PO Q12-24hr as maintenance, although this medication requires 2-3 weeks to reach efficacy.
12/14/21	



**PATIENT**

Domi Sato Saved Dog  
Rescue

**SPECIES**

Canine

**BREED**

Pug

**SEX**

Intact male

**AGE**

10 years

**WEIGHT**

9.7 kg

**INTERPRETED BY**

Eric Lindquist, DMV  
DABVP, Cert. IVUSS

**IMAGING  
PERFORMED BY**

Crystal Hill

**HOSPITAL NAME**

Queensway AH

**REFERRING VET**

Dr. Bilinsky

**INVOICE**

94568

**DATE**

12/14/21

Chronic rhinitis cases in cats typically respond best to doxycycline (10 mg/kg PO Q24hr), which is a best first choice against primary bacterial pathogens. Quinolones (enrofloxacin at 5 mg/kg/day), chloramphenicol (10 mg/kg PO BID), or azithromycin (10 mg/kg PO BID x 5d then PO Q72hr for 3 weeks) can be used for resistant cases. Feline herpes virus or calicivirus are often primary culprits with secondary pathogens. Pasteurella and mycoplasma live in low-oxygen tissue under the mucosal surfaces in the nose and mouth, and often grow secondarily on virally induced lesions. Clindamycin (10 mg/kg PO Q24hr), Clavamox (62.5 mg/cat PO BID), and metronidazole (15 mg/kg PO BID; also an anti-inflammatory) are prudent choices if these organisms are suspected. Resistant viral infections can be treated with lysine (125-250 mg per cat PO BID), alpha interferon (30 IU Q24hr, part in the nostril diluted in saline and the remainder given orally), or famciclovir (31.25 mg/kg PO BID for 14 days) can be attempted as viral modulators. Initial studies with famciclovir are promising; however, data with respect to long-term use have yet to be established. As a last resort, piroxicam (0.3 mg/kg PO Q24hr in liquid form) can be given as an immune modulator.

**Summary of Therapeutic Options for Respiratory Disease**

**1. Bronchodilators**

The use of bronchodilators in various disease states is based on the assumption that clinically significant bronchoconstriction exists. Although this has been shown in a small proportion of dogs with inflammatory bronchopulmonary disease, it is significant in cats where bronchoconstriction is a frequent feature of inflammatory bronchial disease. Because the signs of bronchoconstriction can dominate the clinical syndrome, feline inflammatory airway disease is frequently referred to as "feline asthma." This disease should not be thought of simply as reversible airway obstruction or "irritable airways," but instead understood as an inflammatory disease that can yield bronchial hyperreactivity and bronchospasm.

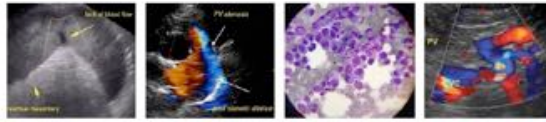
Bronchial tone is mediated by three neuroendocrine systems:

- The parasympathetic system, which is the dominant efferent pathway, provides the baseline tone of mild bronchoconstriction that characterizes the normal respiratory tract.
- The sympathetic system mediates these inherent bronchoconstrictive effects through  $\beta_2$ -adrenergic-mediated bronchodilation and  $\alpha_1$ -mediated bronchoconstriction, and possibly via  $\alpha_2$ -mediated reduction of parasympathetic bronchoconstriction.
- The non-adrenergic, non-cholinergic (NANC) system mediates bronchodilation through various neurotransmitters, such as vasoactive intestinal peptides.

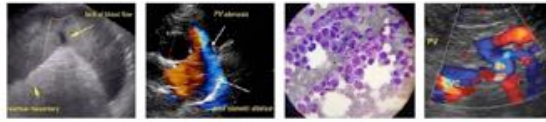
**a) Adrenergic agonists**

All adrenergic agonists have variable  $\alpha$  and  $\beta$  receptor affinity. Non-selective  $\beta$  receptor agonists, such as isoprenaline, or mixed  $\alpha$  and  $\beta$  receptor agonists, such as adrenaline, are more likely to produce cardiovascular side effects than similarly administered selective  $\beta$  agonists. Consequently, drugs with preferential affinity for  $\beta_2$  receptors are likely to provide more effective bronchodilation with fewer side effects. The two  $\beta_2$  agonists used in small animals are terbutaline and albuterol.

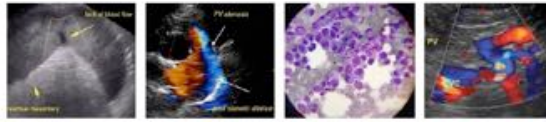
*Terbutaline*



<b>PATIENT</b>	Terbutaline is a selective $\beta_2$ receptor agonist that promotes the relaxation of smooth muscle found principally in bronchial, vascular, and uterine tissues. <b>Dogs:</b> 1.25-5 mg/dog PO BID-TID or 0.01 mg IM/SC Q4hr. <b>Cats:</b> 0.312-1.25 mg/cat PO BID-TID or 0.015 mg/kg IM/SC Q4hr.
Domi Sato Saved Dog Rescue	
<b>SPECIES</b>	<i>Albuterol</i>
Canine	Albuterol is a selective $\beta_2$ receptor agonist with pharmacological properties similar to terbutaline. The drug should be given for 5 days, and if there has been no improvement or adverse effects, the dose can be increased. For animals that only respond to a higher dose, the dose should be reduced to the lowest effective dose, as determined for each patient. Albuterol and prednisolone act synergistically to produce bronchodilation in response to a standard bronchoconstriction stimulus. Thus, concurrent glucocorticoid therapy may be worth considering in patients proving refractory to albuterol's bronchodilatory effects. <b>Dogs and cats:</b> 0.05 mg/kg (50 mcg/kg) PO BID-TID or inhaled via a pediatric aerochamber or AeroKat® inhaler.
<b>BREED</b>	
Pug	
<b>SEX</b>	
Intact male	
<b>AGE</b>	<b>b) Methylxanthines</b>
10 years	Methylxanthines modulate respiratory function by being adenosine receptor antagonists, inhibiting phosphodiesterase, interfering with calcium mobilization, and suppressing the release of histamine. The net result is bronchodilation of both large and small airways, inhibition of mast cell degranulation, increased mucociliary clearance, and decreased work associated with breathing. The most common drug used is aminophylline. <b>Dogs:</b> 9-11 mg/kg IM/PO TID-QID or slow IV (diluted) for emergency bronchodilation. <b>Cats:</b> 6.6 mg/kg PO Q12hr or 2-5 mg/kg slow IV (diluted) for emergency bronchodilation.
<b>WEIGHT</b>	<b>c) Anticholinergics</b>
9.7 kg	Anticholinergics compete with acetylcholine at muscarinic sites and antagonize vagally mediated bronchoconstriction in the respiratory tract. Despite this, they are generally not clinically effective due to their non-selective interaction with different muscarinic receptors and their side effects.
<b>INTERPRETED BY</b>	<b>d) Atropine</b>
Eric Lindquist, DMV DABVP, Cert. IVUSS	The primary indication for atropine use in small animals is to produce bronchodilation in acutely dyspneic animals. It is the treatment of choice for life-threatening respiratory distress induced by anticholinesterases.
<b>IMAGING PERFORMED BY</b>	
Crystal Hill	
<b>HOSPITAL NAME</b>	<b>2. Disruption of Mucous Clearance</b>
Queensway AH	In respiratory disease, mucous undergoes a physical change and becomes extremely viscous, affecting ciliary function. When effective mucous clearance ceases, there is an accumulation of mucous and the following occurs:
<b>REFERRING VET</b>	
Dr. Bilinsky	
<b>INVOICE</b>	
94568	
<b>DATE</b>	<ul style="list-style-type: none"> <li>• Reduced airway diameter.</li> <li>• Compromised penetration of antibiotics and host defense mechanisms at the site of infection.</li> <li>• Worsening of the cough.</li> </ul>
12/14/21	



<b>PATIENT</b>	<ul style="list-style-type: none"> <li>Bacterial colonization.</li> <li>Reduced humidification of inspired air and trapping of foreign particles. Decreased protection of mucoid surfaces from dehydration and injury from physical, chemical, and infectious agents.</li> </ul>
Domi Sato Saved Dog Rescue	
<b>SPECIES</b>	
Canine	Treatment is aimed at optimizing the mucociliary escalator by altering mucous production and its viscosity, and enhancing ciliary action. Mucolytics are used to break down and decrease the viscosity of mucous, whereas expectorants promote an increase in the volume and a decreased viscosity of bronchial secretions. Ciliary activity can be improved using $\beta$ -receptor agonists and methylxanthine derivatives.
<b>BREED</b>	
Pug	
<b>SEX</b>	
Intact male	<b>a) Rehydration</b> Animals with lung disease are frequently dehydrated because of decreased water intake and increased fluid loss due to pyrexia and polypnea, which contributes to increased mucus viscosity. Water and saline solutions can be used to liquefy hyperviscous mucous and can be administered orally or via parenteral fluids, inhalation (steam vapour), or saline aerosols (nebulisation).
<b>AGE</b>	
10 years	
<b>WEIGHT</b>	
9.7 kg	<b>b) Mucolytic drugs</b> The viscosity of pulmonary mucus secretions depends on the concentrations of mucoproteins and presence of DNA. Although mucoprotein is the main determinant of viscosity in normal mucus, in cases of purulent inflammation, the concentration of DNA increases due to increased cellular debris, which contributes to an increased mucoid viscosity. Mucolytic drugs break down the disulfide bonds of mucoproteins, resulting in a decrease in viscosity.
<b>INTERPRETED BY</b>	
Eric Lindquist, DMV DABVP, Cert. IVUSS	<b>c) Acetylcysteine</b> Acetylcysteine reduces the viscosity of both purulent and non-purulent secretions by virtue of its free sulphhydryl group, which reduces the disulphide linkages in mucoproteins. The latter are thought to be at least partly responsible for the particularly viscid nature of respiratory mucus. The mucolytic activity of acetylcysteine is unaltered by the presence of DNA and increases with rising pH levels. Acetylcysteine can be given by aerosol or orally; however, administration by aerosol may cause bronchospasm, ciliary inhibition, and severe coughing. Nebulize as a 2% solution over 30-60 minutes or instill directly into the trachea (1-2 ml of a 20% solution).
<b>IMAGING PERFORMED BY</b>	
Crystal Hill	
<b>HOSPITAL NAME</b>	
Queensway AH	
<b>REFERRING VET</b>	
Dr. Bilinsky	<b>d) Bromohexine</b> Bromohexine increases mucus viscosity by increasing lysosomal activity. This increased lysosomal activity enhances hydrolysis of acid mucopolysaccharide polymers, which contributes significantly to normal mucus viscosity. In purulent bronchial inflammation, bronchial mucus viscosity is more dependent upon the presence of large amounts of DNA fibres. As bromohexine does not affect these DNA fibres, its mucolytic action is limited in these situations. At high doses, it can act as an antitussive and will increase the concentration of tetracyclines, sulphonamides, and erythromycin in the bronchial mucus.
<b>INVOICE</b>	
94568	
<b>DATE</b>	
12/14/21	



**PATIENT**

Domi Sato Saved Dog  
Rescue

**SPECIES**

Canine

**BREED**

Pug

**SEX**

Intact male

**AGE**

10 years

**WEIGHT**

9.7 kg

**INTERPRETED BY**

Eric Lindquist, DMV  
DABVP, Cert. IVUSS

**IMAGING  
PERFORMED BY**

Crystal Hill

**HOSPITAL NAME**

Queensway AH

**REFERRING VET**

Dr. Bilinsky

**INVOICE**

94568

**DATE**

12/14/21

**e) Decongestants**

Decongestants reduce the production and accumulation of inflammatory edema in the nasal passages, but are seldom used in veterinary practice. Drugs, such as adrenaline and phenylephrine, are applied topically. The major side effect is a rebound phenomenon; relapse is likely once the effect of the decongestant has worn off.

**f) Expectorants**

Expectorants promote the removal of secretions from the respiratory tree by increasing the volume and reducing the viscosity of respiratory secretions; however, overall, they only make a slight contribution to therapeutic success. Steam, volatile oils, and iodine preparations can all act as expectorants.

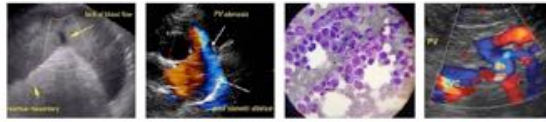
**3. Coughing**

The cough reflex is complex, involving the central and peripheral nervous system as well as the smooth muscle of the bronchial tree. It has been suggested that irritation of the bronchial mucosa causes bronchoconstriction, which in turn stimulates cough receptors located within the tracheobronchial tree. Afferent conduction from these receptors occurs via the vagus nerve and likely travels to multiple centers within the medulla that are distinct from the actual respiratory center.

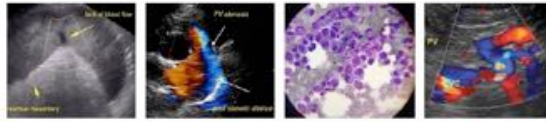
Almost all respiratory tract disorders involving the large and small airways result in coughing. The latter can be viewed as a protective physiological process that helps to clear viscid secretions produced by chronic airway inflammation. Because prolonged contact between inflammatory mediators in the mucus and epithelial cells perpetuates inflammation, any form of cough suppression needs to be implemented cautiously. If coughing persists once the primary disease has been addressed, then suppression may be desirable, as chronic coughing tends to promote airway inflammation, which increases the risk of a vicious cough cycle that can lead to further mucosal irritation and perpetuate coughing. Additionally, chronic coughing of any kind will increase the risk of irreversible emphysema. Consequently, cough suppression may be particularly helpful in certain situations. Perhaps the most common condition where cough suppression plays an integral part in successful management is dynamic airway disease.

It is also important to differentiate between a productive cough and a non-productive cough. A productive cough is a protective reflex that removes secretions from the lungs, which may otherwise become congested with mucous plugs that can become sites for infection and disturb effective gas exchange. This type of cough should not be suppressed and may be encouraged with expectorants. A non-productive cough, particularly if it is chronic and continuous, may itself cause chronic respiratory parenchymal changes, such as emphysema and fibrosis. It is also distressing and exhausting to the animal and may irritate the owner. Non-productive coughs may be treated with cough suppressants.

Coughing can be treated by:



<b>PATIENT</b>	<ul style="list-style-type: none"> <li>Removing the irritant using mucolytics and expectorants.</li> <li>Blocking peripheral receptors to induce bronchodilation.</li> <li>Blocking the cough center in the medulla.</li> </ul>
Domi Sato Saved Dog Rescue	
<b>SPECIES</b>	Typically, drugs that are used to suppress coughing are categorized as opioid or non-opioid antitussive agents.
Canine	
<b>BREED</b>	<b>a) Non-opioid antitussives</b>
Pug	<i>Dextromethorphan</i>
<b>SEX</b>	Dextromethorphan is a synthetic cough suppressant that acts centrally to elevate the cough threshold but does not have addictive, analgesic, or sedative effects. At normal doses, it does not produce respiratory depression or inhibit ciliary activity. Its antitussive effects may persist for up to 5 hours.
Intact male	<b>Dogs only:</b> 0.1-0.2 mg/kg up to 4 times daily.
<b>AGE</b>	<b>b) Opioid antitussives</b>
10 years	<i>Codeine phosphate</i>
<b>WEIGHT</b>	Due to reduced first-pass hepatic metabolism, codeine has a high oral-parenteral potency for an opioid. Oral administration of codeine provides approximately 60% of its parenteral efficacy. Often the dose may need to be increased to achieve a satisfactory effect.
9.7 kg	
<b>INTERPRETED BY</b>	<i>Hydrocodone</i>
Eric Lindquist, DMV DABVP, Cert. IVUSS	Hydrocodone exhibits the same properties of other opiate agonists but has increased antitussive properties compared to codeine. The mechanism of this effect appears to be a direct suppression of the cough center within the medulla. Hydrocodone may also reduce respiratory mucosal secretions through undetermined mechanisms. <b>Dogs:</b> 0.22 mg/kg PO Q6hr. The antitussive effect generally lasts between 6-12 hours. <b>Cats:</b> 1.25-5 mg per cat PO Q12hr (ensure no combination with acetaminophen).
<b>IMAGING PERFORMED BY</b>	
Crystal Hill	
<b>HOSPITAL NAME</b>	<i>Dihydrocodeine</i>
Queensway AH	Dihydrocodeine also acts centrally to raise the cough threshold. It is marketed as an elixir, which is relatively palatable and well absorbed. <b>Dogs:</b> 1.1-2.2 mg/kg PO Q6hr.
<b>REFERRING VET</b>	<i>Butorphanol</i>
Dr. Bilinsky	Butorphanol is an effective antitussive and analgesic. In dogs, it has been shown to elevate the CNS respiratory centre threshold to CO <sub>2</sub> , but unlike other opioid agonists, it does not suppress respiratory centre sensitivity. Butorphanol is well absorbed orally; however, a significant first-pass effect occurs, resulting in less than 20% of the drug appearing in the systemic circulation. <b>Dogs:</b> 0.05-0.1 mg/kg IV/IM/SC or 0.5-1 mg/kg PO TID-QID. <b>Cats:</b> 0.2-0.5 mg/kg IV/IM/SC.
<b>INVOICE</b>	
94568	
<b>DATE</b>	<i>Diphenoxylate</i>
12/14/21	Diphenoxylate is an opioid agonist traditionally used as an anti-diarrheal agent; however, it also has potent antitussive effects and presumably acts through direct suppression of the cough center.



**PATIENT**

Domi Sato Saved Dog  
Rescue

**SPECIES**

Canine

**BREED**

Pug

**SEX**

Intact male

**AGE**

10 years

**WEIGHT**

9.7 kg

**INTERPRETED BY**

Eric Lindquist, DMV  
DABVP, Cert. IVUSS

**IMAGING  
PERFORMED BY**

Crystal Hill

**HOSPITAL NAME**

Queensway AH

**REFERRING VET**

Dr. Bilinsky

**INVOICE**

94568

**DATE**

12/14/21

**4. Inflammation and Pain**

In most respiratory diseases, arachidonic acid is released from reactive cells during tissue inflammation and is converted into a number of derivatives. Among them are prostaglandins and leukotrienes, which are powerful endogenous bronchoconstrictors.

**a) Corticosteroids**

Glucocorticoids induce the formation of lipocortins in cells containing glucocorticoid receptors. These lipocortins then inhibit phospholipase A2, which is responsible for the mobilization of arachidonic acid from membrane lipids. Corticosteroids are therefore effective in preventing the bronchoconstriction often associated with inflammatory conditions.

Indications for the use of corticosteroids include rhinitis, laryngitis, bronchitis, and allergic lung disease. Inhaled steroids are the standard of care for humans with asthma and can be used with an equal success rate in the treatment of dogs and cats with respiratory diseases. Budesonide, flunisolide, and fluticasone are all options. **Dogs:** 110 mcg PO BID for dogs that weigh less than 20 kg and 220 mcg PO BID for those that weigh more than 20 kg. **Cats:** 20-50 mcg/kg PO Q6-8hr (maximum 100 mcg/kg PO Q6hr). These drugs are administered using a spacer (pediatric aerochamber or AeroKat® inhaler).

**b) Antihistamines**

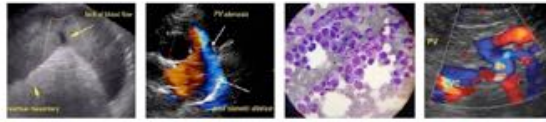
Histamine released due to inflammation or hypersensitivity reactions results in the contraction of bronchial smooth muscle via H<sub>1</sub> receptors in dogs. In cats, however, it causes the relaxation of respiratory smooth muscle by stimulating both H<sub>1</sub> and H<sub>2</sub> receptors. Antihistamines counter bronchoconstriction and will often help to control coughing in dogs.

*Diphenhydramine*

Diphenhydramine reduces the bronchoconstriction, production of secretions, and respiratory irritation due to its local anesthetic effect; it also has a strong sedative effect.

**c) Nonsteroidal anti-inflammatory drugs (NSAIDs)**

NSAIDs inhibit the metabolism of arachidonic acid at one or more steps, limiting the production of the inflammatory mediators, prostaglandins, and thromboxane. They have a limiting action on inflammation and have potent analgesic and antipyretic effects. Yet, because they inhibit the COX enzyme system, shunting towards the LOX pathway occurs, which promotes the formation of leukotrienes; the latter are potent bronchoconstrictors.



**PATIENT**

Domi Sato Saved Dog  
Rescue

**SPECIES**

Canine

**BREED**

Pug

**SEX**

Intact male

**AGE**

10 years

**WEIGHT**

9.7 kg

**INTERPRETED BY**

Eric Lindquist, DMV  
DABVP, Cert. IVUSS

**IMAGING  
PERFORMED BY**

Crystal Hill

**HOSPITAL NAME**

Queensway AH

**REFERRING VET**

Dr. Bilinsky

**INVOICE**

94568

**DATE**

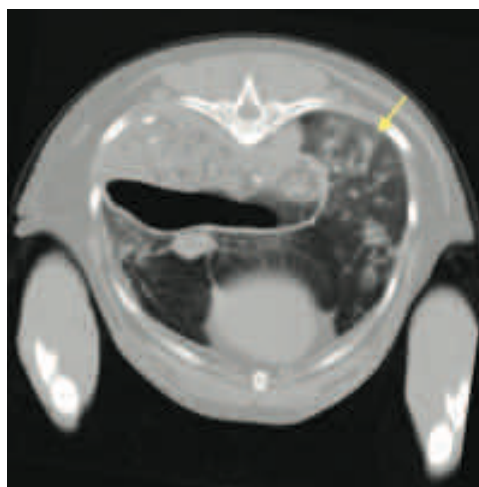
12/14/21

**Bacterial infections**

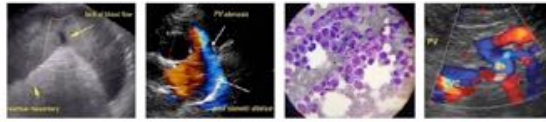
Bacterial infections of the respiratory system are a common occurrence in dogs, but less so in cats. They often transpire after the pulmonary defense mechanisms have been compromised by one of the following: aspiration of foreign material; chronic bronchial disease; foreign bodies; or viral diseases. The organisms that most commonly cause pneumonia in dogs include: *Pasteurella multocida*, *Streptococcus* spp., *Staphylococcus* spp., *Pseudomonas*, *Escherichia coli*, *Klebsiella* spp., and *Bordetella bronchiseptica*.

Ideally, the selection of antibiotics should be based on bacterial culture and sensitivity testing; however, empirical or initial antibiotic selection can be based on an examination of the tracheal wash. The identification of cocci usually indicates a streptococci or staphylococci, which are gram-positive and often susceptible to amoxicillin, potentiated sulphonamides, and cephalosporins. Bacterial rods are usually gram-negative bacteria and suitable antibiotics include potentiated sulphonamides, gentamicin, amikacin, and fluoroquinolones. In cases where it is not possible to identify the bacteria, antibiotics should be selected to cover both gram-negative and gram-positive possibilities, such as penicillin with gentamicin and potentiated penicillins (amoxicillin with clavulanic acid).

Concentrations of antibiotics within the pulmonary parenchyma tend to correlate well with serum concentrations. Some antibiotics, such as fluoroquinolones, will result in concentrations in the lungs that are 4-5 times higher than those found in the serum. In most infections, the routine administration of appropriate antibiotics is adequate to achieve a therapeutic response; however, in severe cases, antibiotics should be administered intravenously for the first 3-7 days. Therapy should be administered for 4-8 weeks, ideally 1-2 weeks after resolution of the condition.



Transverse computed tomographic image of the chest in a cat with chronic bronchopneumonia. Multifocal bronchial wall thickening with peribronchial interstitial infiltrate is seen (arrow). Note the cortication of the lung lobes indicating pleural fibrosis. The esophagus is dilated with food and gas as a sequel to general anesthesia with gastroesophageal reflux.



**PATIENT**

Domi Sato Saved Dog  
Rescue

**SPECIES**

Canine

**BREED**

Pug

**SEX**

Intact male

**AGE**

10 years

**WEIGHT**

9.7 kg

**INTERPRETED BY**

Eric Lindquist, DMV  
DABVP, Cert. IVUSS

**IMAGING  
PERFORMED BY**

Crystal Hill

**HOSPITAL NAME**

Queensway AH

**REFERRING VET**

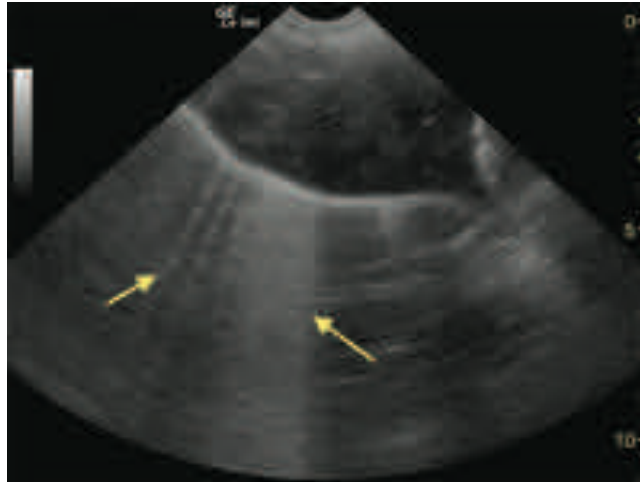Dr. Bilinsky

**INVOICE**

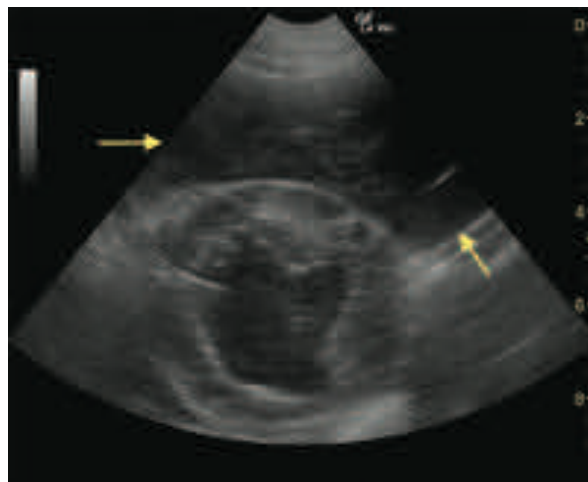94568

**DATE**

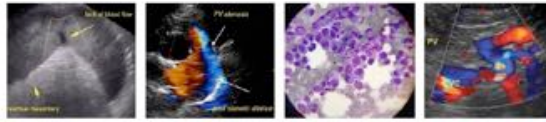
12/14/21



Subphrenic transdiaphragmatic scan of the lung in a dog. The liver is seen in the near field. “Comet tail” (small arrow) or “shower curtain” (large arrow) artifacts originating from the lung surface deep to the diaphragm indicate the presence of multifocal interstitial pulmonary infiltrate as may be seen with pulmonary metastases, pulmonary thromboemboli and other. These lesions can often be seen sonographically before radiographic detection in some cases with increased clinical significance when an elevated resting respiratory rate (> 35 RPM) is present.



Intercostal scan of the chest in a dog with a histiocytic sarcoma within the left cranial lung lobe (arrows). Note the lack of aeration within the pulmonary parenchyma which enables penetration of ultrasound waves through the entire lung lobe. The heart is seen deep to the lung lobe in short axis. The neoplastic infiltrate has led to volume increase within the affected lobe.



**PATIENT**

Domi Sato Saved Dog  
Rescue

**SPECIES**

Canine

**BREED**

Pug

**SEX**

Intact male

**AGE**

10 years

**WEIGHT**

9.7 kg

**INTERPRETED BY**

Eric Lindquist, DMV  
DABVP, Cert. IVUSS

**IMAGING  
PERFORMED BY**

Crystal Hill

**HOSPITAL NAME**

Queensway AH

**REFERRING VET**

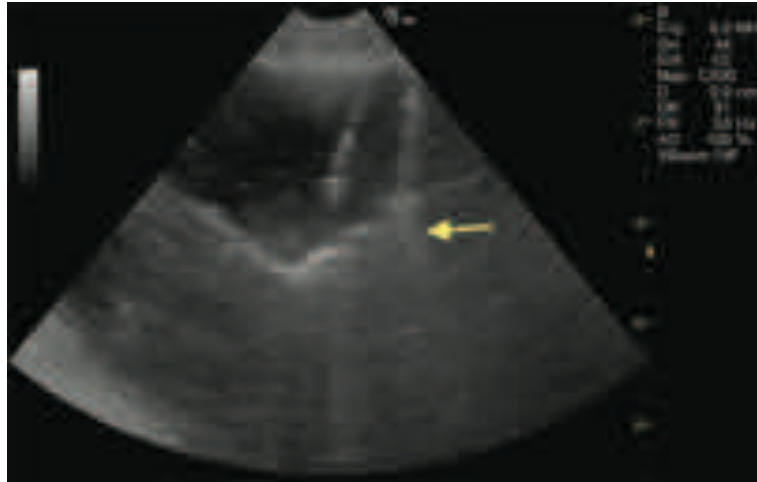
Dr. Bilinsky

**INVOICE**

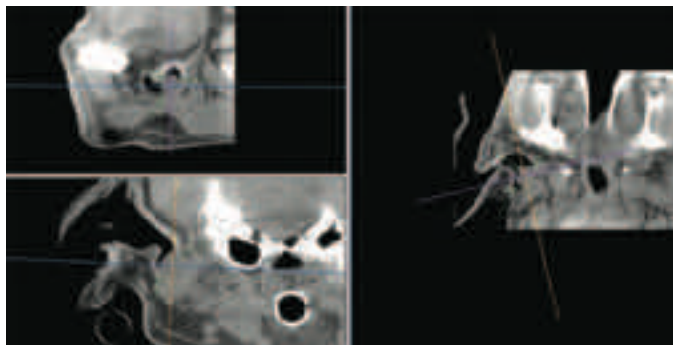
94568

**DATE**

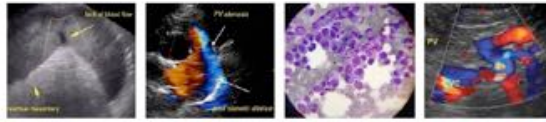
12/14/21



Intercostal scan of the lung of the same dog as in previous image during ultrasound guided biopsy of the lung. The hyperechoic core biopsy needle is seen within the tumor tissue. Development of a relevant pneumothorax is rare in dogs when the needle tract does not interfere with aerated lung tissue. Note the peripheral echogenic aeration of the mass margins (arrow) indicative of lung tissue origin.



7-year-old MN Cocker Spaniel with a history of ear infections and upper respiratory disease. The computed tomographic findings are compatible with a neoplastic mass lesion within the right external auditory canal (arrows) and mild reactive lymphadenopathy. Differential diagnosis includes an inflammatory polyp next to various types of mesenchymal and epithelial soft tissue neoplasia. CT Images: Vimago by Epica Medical International



**PATIENT**

Domi Sato Saved Dog Rescue

**SPECIES**

Canine

**BREED**

Pug

**SEX**

Intact male

**AGE**

10 years

**WEIGHT**

9.7 kg

**INTERPRETED BY**

Eric Lindquist, DMV  
DABVP, Cert. IVUSS

**IMAGING PERFORMED BY**

Crystal Hill

**HOSPITAL NAME**

Queensway AH

**REFERRING VET**

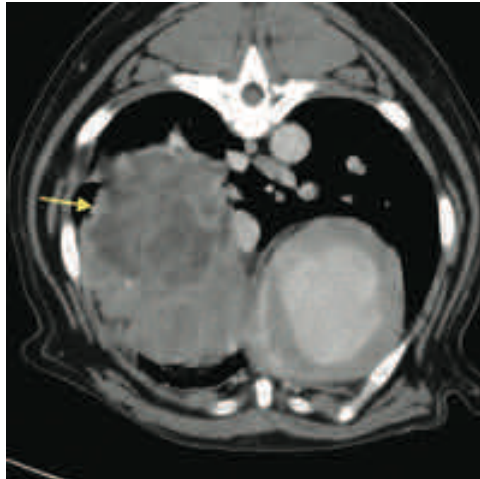Dr. Bilinsky

**INVOICE**

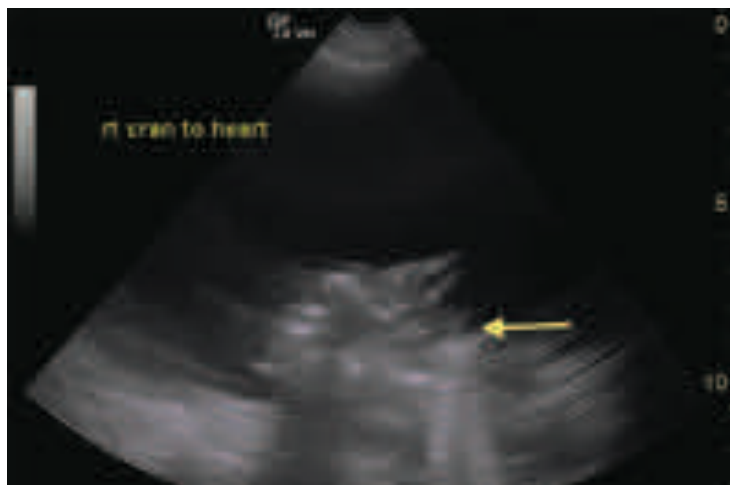94568

**DATE**

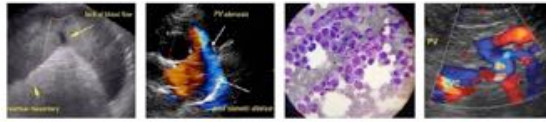
12/14/21



Transverse post contrast computed tomographic image of a dog with a pulmonary histiocytic sarcoma (arrow). Note the large space occupying lesion with heterogenous contrast enhancement within the right middle lung lobe. Also note the mass effect recognized by a significant mediastinal shift and leftward displacement of the caudal vena cava. CT Image courtesy of Nele Ondreka DipDECVDI, Giessen, Germany



Right parasternal intercostal scan of the pleural cavity in a dog with a lung mass. The lung lobes are retracted from the chest wall. Note the uneven surface (arrow) and irregular displacement of air by the neoplastic infiltrate within the lung. A large amount of anechoic pleural effusion is present compatible with carcinomatosis.



**PATIENT**

Domi Sato Saved Dog Rescue

**SPECIES**

Canine

**BREED**

Pug

**SEX**

Intact male

**AGE**

10 years

**WEIGHT**

9.7 kg

**INTERPRETED BY**

Eric Lindquist, DMV  
DABVP, Cert. IVUSS

**IMAGING PERFORMED BY**

Crystal Hill

**HOSPITAL NAME**

Queensway AH

**REFERRING VET**

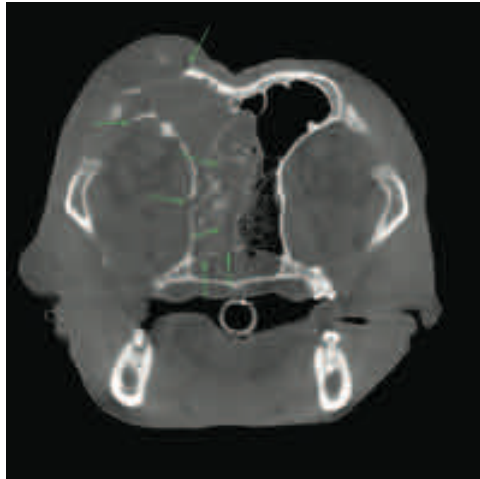
Dr. Bilinsky

**INVOICE**

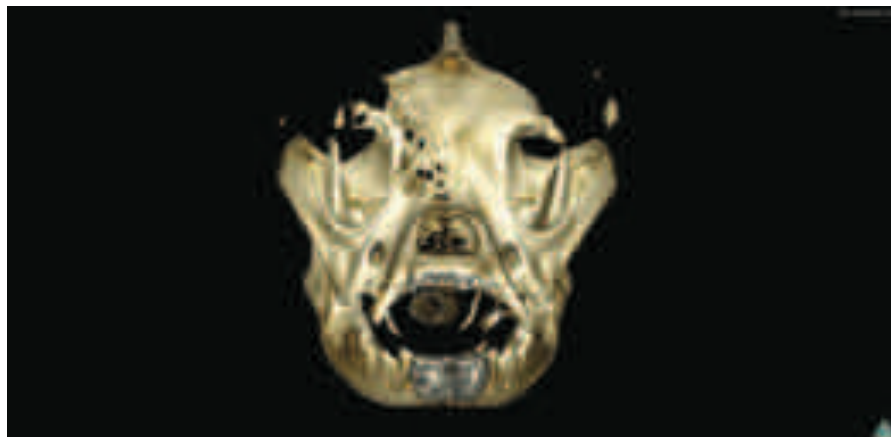
94568

**DATE**

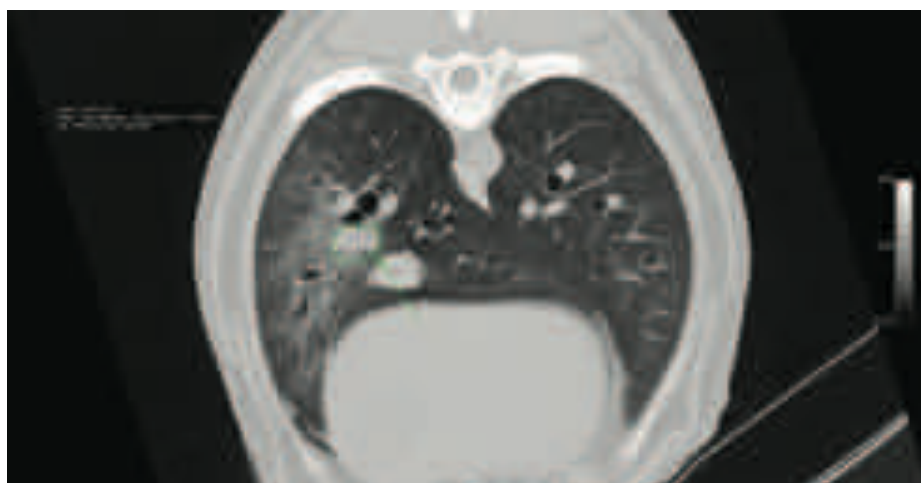
12/14/21



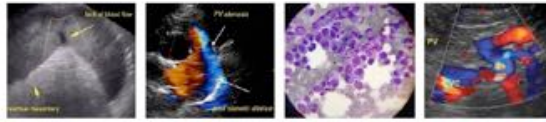
The computed tomographic findings of a Geriatric Boxer dog with chronic nasal discharge are compatible with a malignant nasal soft tissue neoplasia with infiltrative growth and aggressive bone destruction. Likely differential diagnoses include adenocarcinoma, squamous cell carcinoma, lymphosarcoma, melanoma, fibrosarcoma and other. Complete resection unfortunately is not an option. CT Images: Vimago by Epica Medical International



3D rendering of the aggressive nasal mass noted in the prior image. CT Images: Vimago by Epica Medical International



Transverse CT view of the thorax level with the caudal lung lobes in a dog with inhalational pneumonia and grass awn migration. Note the focal hyperattenuating alveolar infiltrate ventral to the significantly dilated bronchus (arrow). The wide extent of the inflammatory changes



**PATIENT**

Domi Sato Saved Dog  
Rescue

**SPECIES**

Canine

**BREED**

Pug

**SEX**

Intact male

**AGE**

10 years

**WEIGHT**

9.7 kg

**INTERPRETED BY**

Eric Lindquist, DMV  
DABVP, Cert. IVUSS

**IMAGING  
PERFORMED BY**

Crystal Hill

**HOSPITAL NAME**

Queensway AH

**REFERRING VET**

Dr. Bilinsky

**INVOICE**

94568

**DATE**

12/14/21

**References:**

Cohn LA, Reiner CR. Respiratory defenses in health and disease. *Vet Clin North Am Small Anim Pract* 2007;37:845-60.

Epstein SE, Mellema MS, Hopper K. Airway microbial culture and susceptibility patterns in dogs and cats with respiratory disease of varying severity. *J Vet Emerg Crit Care* 2010;20:587-94.

Hackett, TB. Canine respiratory emergencies. Proceedings from the Western Veterinary Conference: Emergency and Critical Care, Las Vegas, NV, February 19-23, 2012.

Johnson LR, Queen EV, Vernau W, et al. Microbiologic and cytologic assessment of bronchoalveolar lavage fluid from dogs with lower respiratory tract infection: 105 cases (2001-2011). *J Vet Intern Med* 2013;27:259-67.

Maggs DJ. Antiviral therapy for feline herpes virus infections. *Vet Clin North Am Small Anim Pract* 2010;40:1055-62.

Miller CJ. Approach to the respiratory patient. *Vet Clin North Am Small Anim Pract* 2007;37:861-78.

Rozanski EA, Bach JF, Shaw SP. Advances in respiratory therapy. *Vet Clin North Am Small Anim Pract* 2007;37:963-74.

Rozanski E, Chan DL. Approach to the patient with respiratory distress. *Vet Clin North Am Small Anim Pract* 2005;35:307-17.

Sumner C, Rozanski E. Management of respiratory emergencies in small animals. *Vet Clin North Am Small Anim Pract* 2013;43:799-815.

is indicated by a diffuse interstitial ground glass opacity, bronchial widening and wall thickening ventrally within the right caudal lobe. CT Image courtesy of Nele Ondreka DipDECVDI, Giessen, Germany